



Introduction

Single posteriors

Anteriors

Implants

Product Information

Prime Collection

Clinical Cases

Find out more >

 Dentsply
Sirona





Dear Readers,

Excellent, fascinating and inspiring: with this booklet, you are about to discover the collection of Prime clinical cases. We are very pleased to share a variety of cases done with the latest generation of the CEREC® system.

With CEREC® Primescan®, CEREC Primemill® and CEREC® SpeedFire®, restorations can be manufactured from a wide variety of materials at an extremely high speed. Quality has also reached a new level with precise designs, finely milled surfaces and margins, and excellent accuracy of fit. Everyone who has experienced this innovation live quickly appreciates its value. This modern system is also incredibly easy and intuitive to operate.

The clinical cases presented here originated in the clinics and practices of expert users. We would like to take this opportunity to thank them sincerely for their critical and constructive support during the entire development process. Without them, it would not have been possible to create the solutions that move you and dentistry forward every day.

By means of these clinical cases, your colleagues demonstrate the wide range of indications applicable for CEREC – from single-visit restorations to highly esthetic challenges and comprehensive oral rehabilitation. Be inspired and experience how this smart, sophisticated technology can support you in your work to make the treatment experience for your patients great, and enable a high level of safety and efficiency.

What our expert users created with the newest CEREC generation really impressed us as the developer and manufacturer of the equipment. We invite you to share our enthusiasm for the variety of new opportunities! We hope you find this an interesting read and look forward to hearing from you about your own experiences with CEREC.

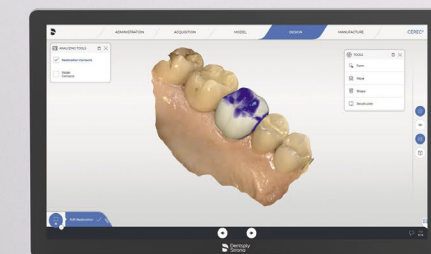
With best regards,

Max Milz
Global Head of Marketing & Clinical Software
Connected Technology Solutions

Swen Deussen
Global Head of Marketing
Connected Technology Solutions

Professionals featured in this document may have been compensated for their time.

Our product heroes:



CEREC Primescan AC



CEREC Primemill



CEREC SpeedFire

Our experts:



Dr. Andreas Bintl
Zurich, Switzerland



Dr. Frank Clark Brown
Melbourne, USA



Dr. Dan Butterman
Centennial, USA



Dr. Gertrud Fabel
Munich, Germany



Dr. Shivi Gupta
San Diego, USA



Dr. Karyn M. Halpern
DMD MS, New York, USA



Dr. Carlos Repullo
Sevilla, Spain



Dr. Sven Rinke
Hanau, Germany



Claudia Scholz
Kiel, Germany



Dr. Mike Skramstad
DDS, Orono, USA



Dr. Fernando Peixoto Soares
São Paulo, Brazil



Dr. Cecilie Terjesen
Arendal, Norway




Dr. Daniel Vasquez
San Diego, USA



Single posteriors

1


Single crown on first upper molar
CEREC Tessera



before after

2


Inlay on first upper molar
CEREC Tessera



before after

3

Single crown on second upper premolar
CEREC MTL Zirconia



before after

4


Quadrant rehabilitation
CEREC Tessera crowns and inlays – each 2



before after

5

Single crown on second upper premolar
IPS e.max CAD



before after

6


Single crown on first upper molar
IPS e.max CAD



before after

7


Single crown on first upper molar
IPS e.max CAD



before after

8

Single crown on second lower premolar
Katana Zirconia STML



before after

9

Single crown on first upper molar
Katana Zirconia STML



before after



A CEREC Tessera crown – First upper molar in 90 minutes



Dr. Shivi Gupta
San Diego, USA

Case Description

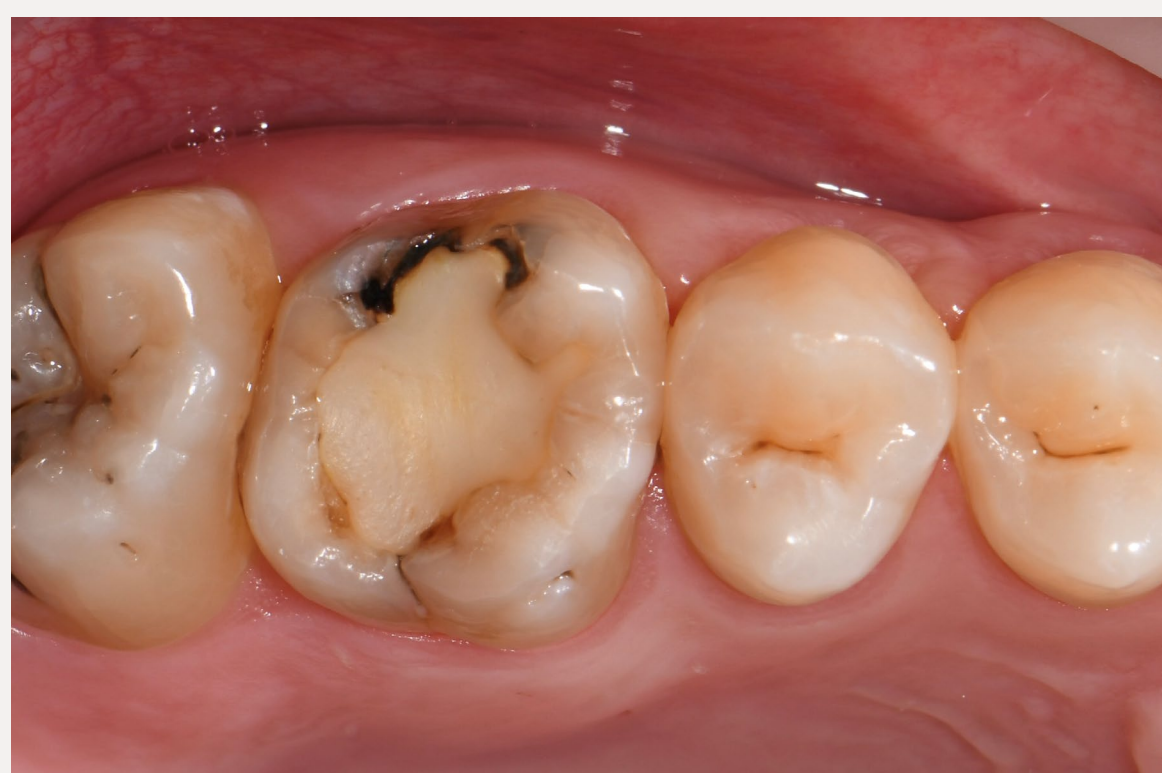A 49-year-old male patient visited my practice with pain in the first upper molar, which he described as occurring when he bit down. The tooth had been restored with an extensive yet insufficient composite filling that already showed visible fractures. The clinical examination also revealed a carious defect...

Discussion

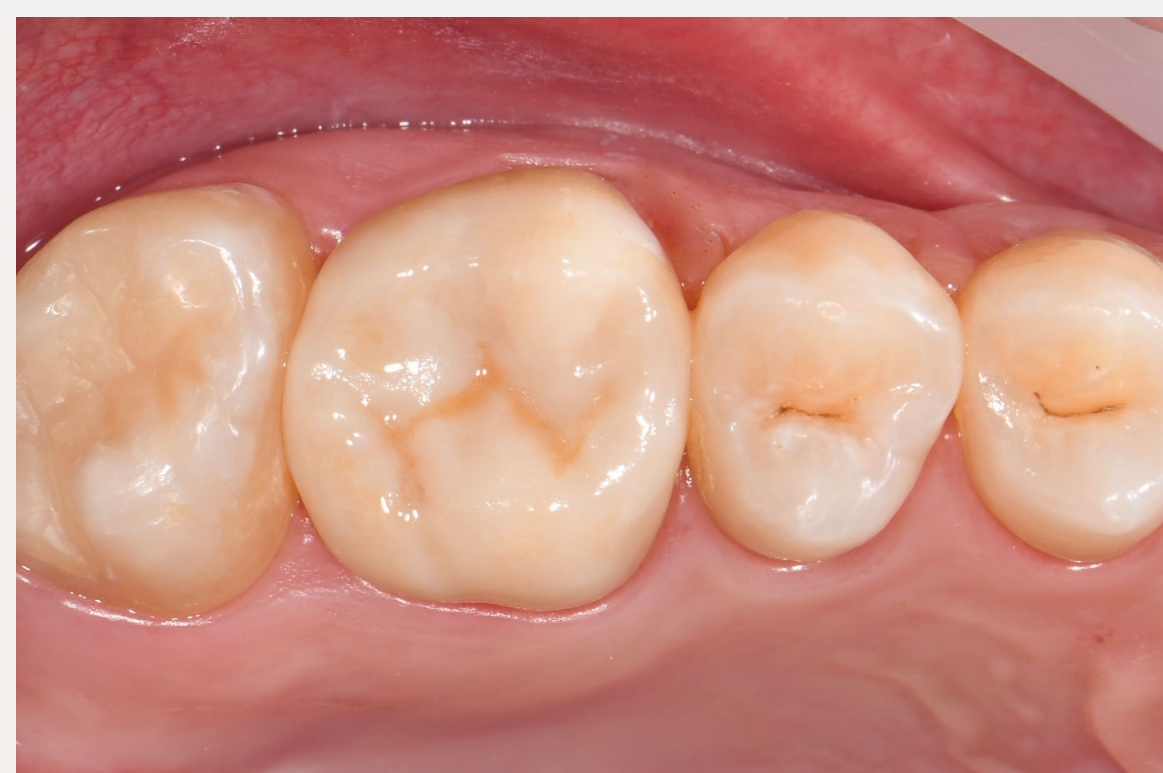The decisive factor for the restoration of the first upper molar with a crown was the patient's pain when biting down. Replacing the filling would have been only a temporary solution. The crown solves the problem from a functional point of view and offers excellent esthetics simultaneously thanks to the new material...

Read more

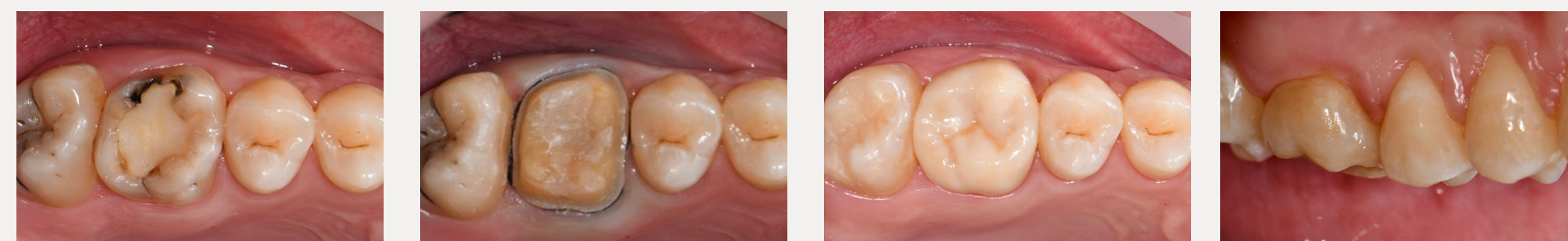Before



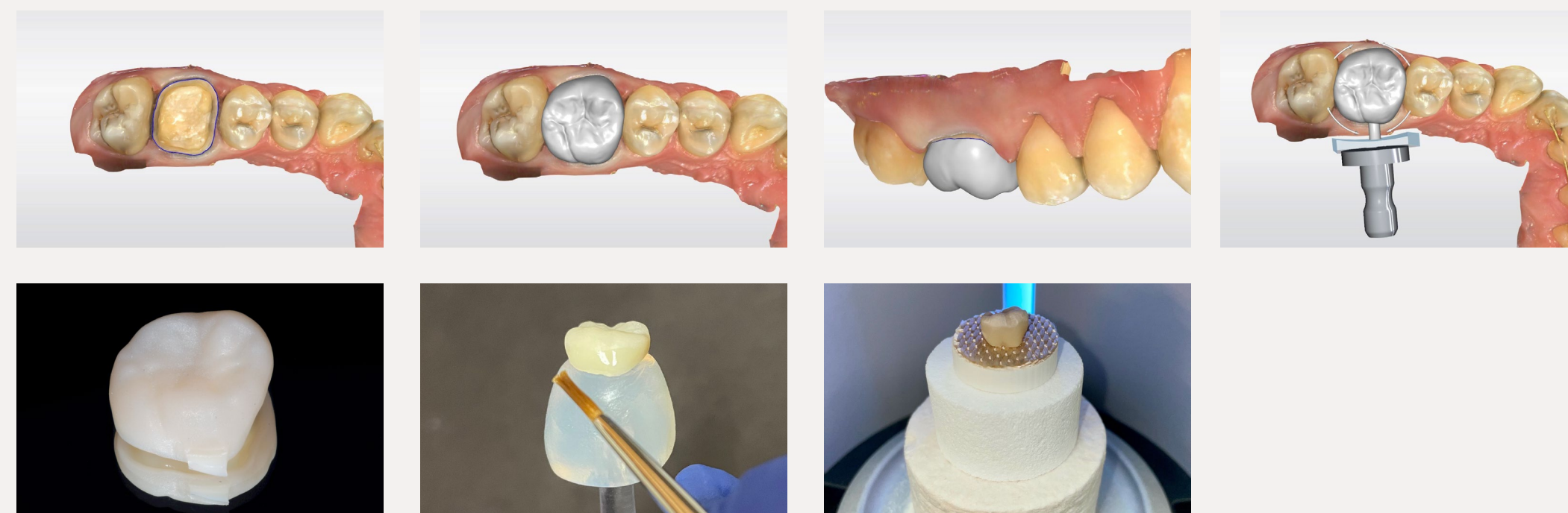After



Clinical Images



Workflow Images





A CEREC Tessera inlay – First upper molar in 100 minutes



Dr. Sven Rinke
Hanau, Germany

Case Description

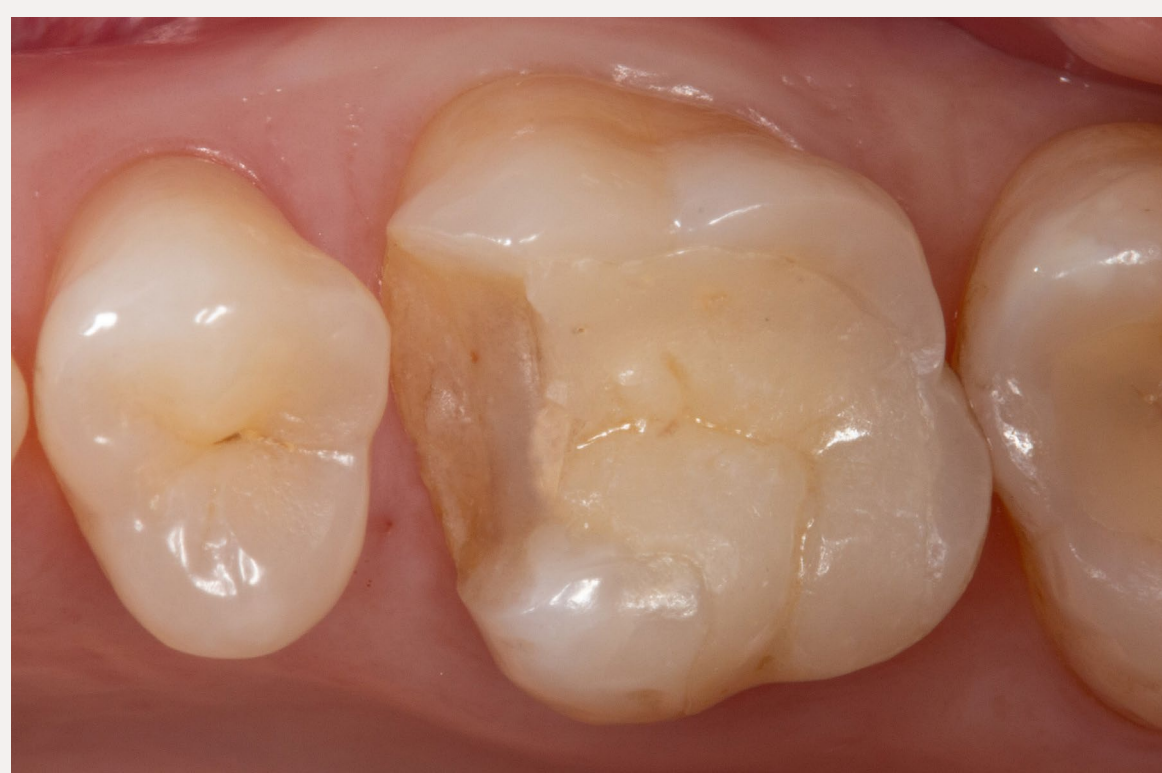A 42-year-old female patient came to my practice with mild pain and a bothersome feeling when chewing on tooth 26. On examination, a fractured ceramic restoration was revealed, but no secondary caries. The patient remembered having received this inlay 12 years ago...

Discussion

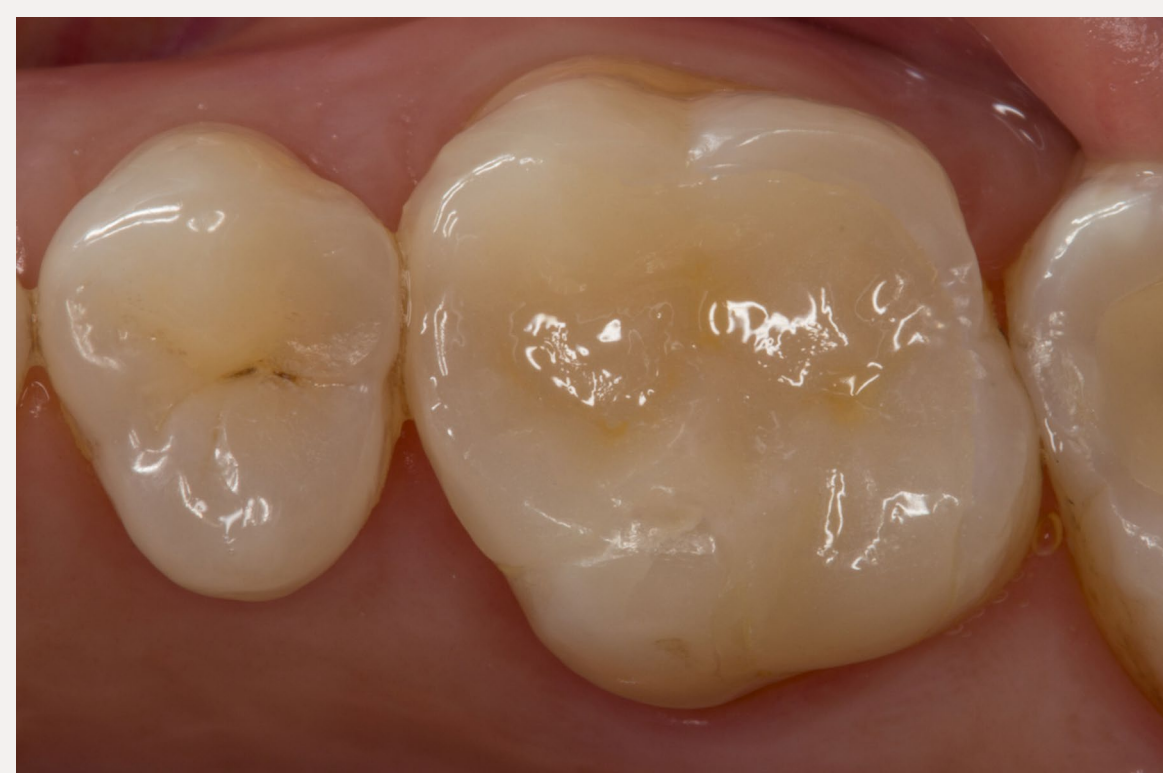The chairside restoration of the tooth in a single visit proved to be a particularly effective and a convenient solution for this patient, as her commute to the practice was around 50 kilometers. CEREC Tessera was used, a material that offers a high level of fracture resistance...

Read more

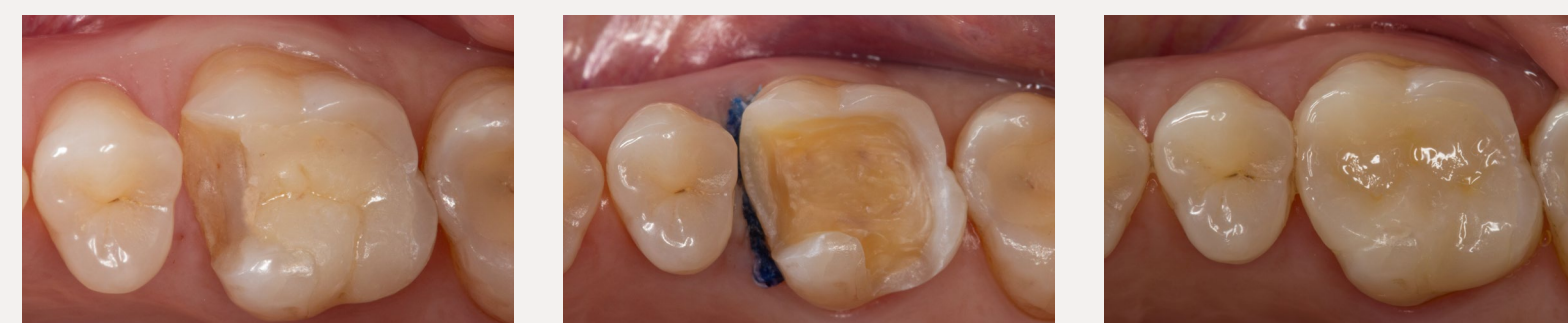Before



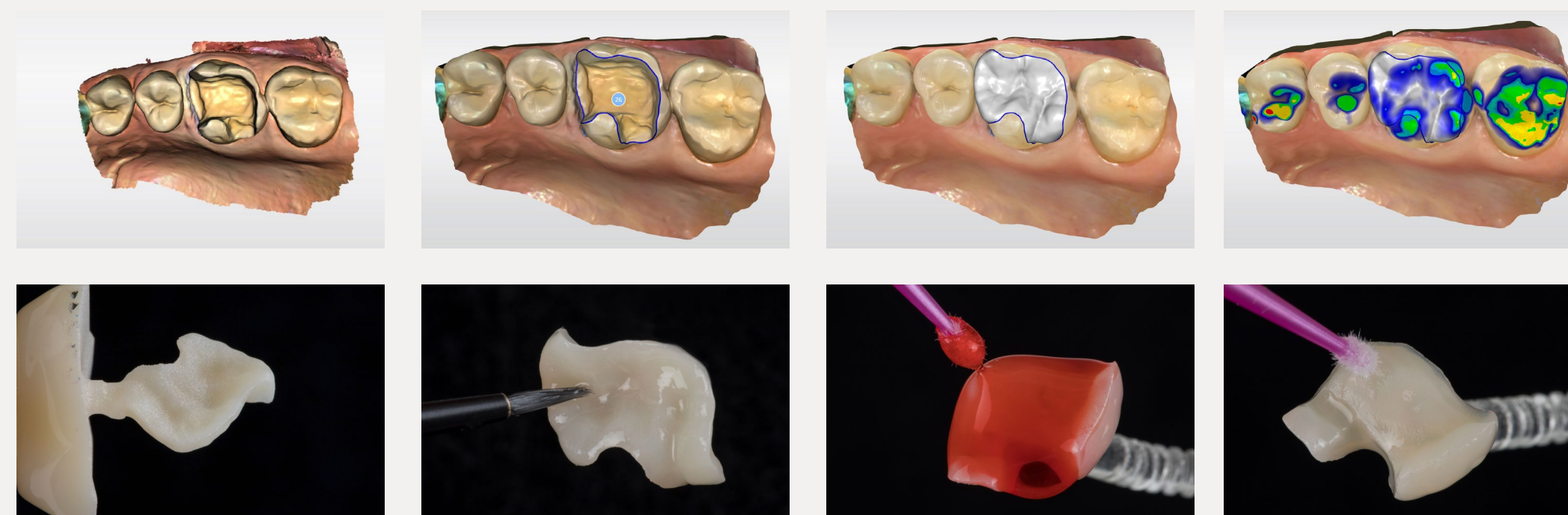
After



Clinical Images



Workflow Images





A CEREC MTL Zirconia crown – Second upper premolar in 90 minutes



Dr. Cecilie Terjesen
Arendal, Norway

Case Description

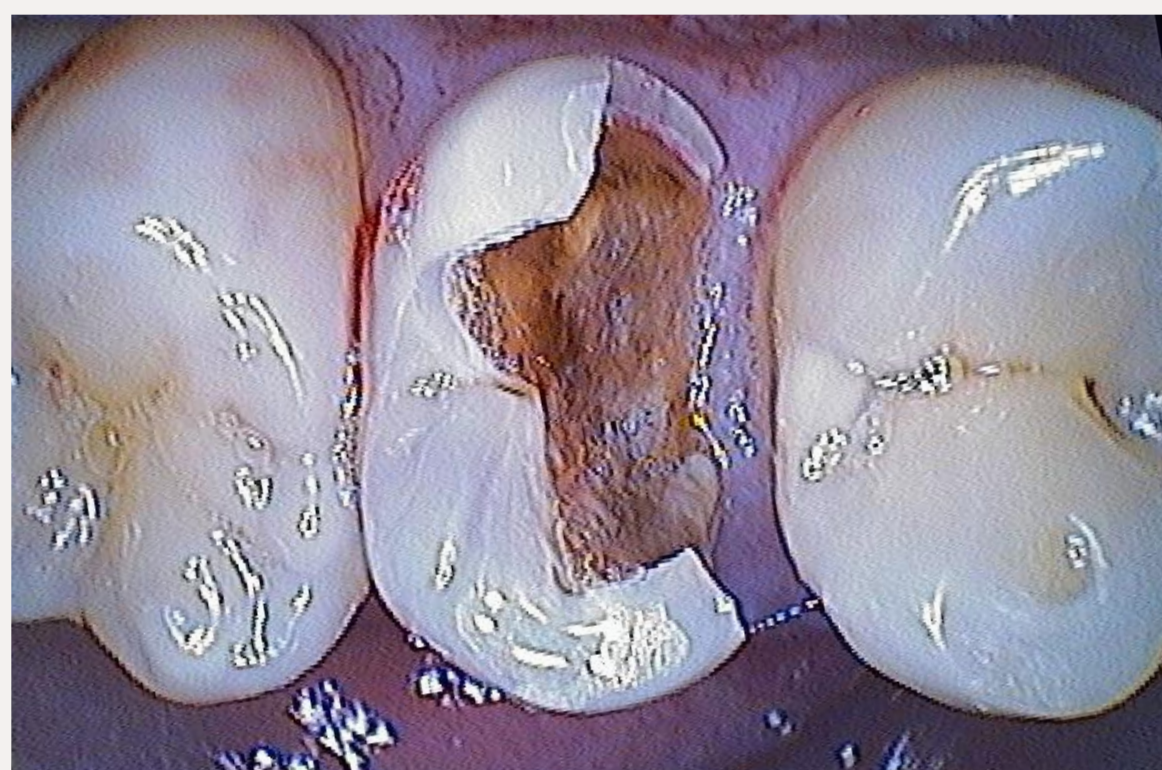A 32-year-old male patient came to the clinic for a check-up after putting off going to the dentist for seven years. He presented with a large carious mesial lesion on tooth 15. The tooth showed asymptomatic apical periodontitis and a significant loss of tooth structure. The patient was motivated for treatment...

Discussion

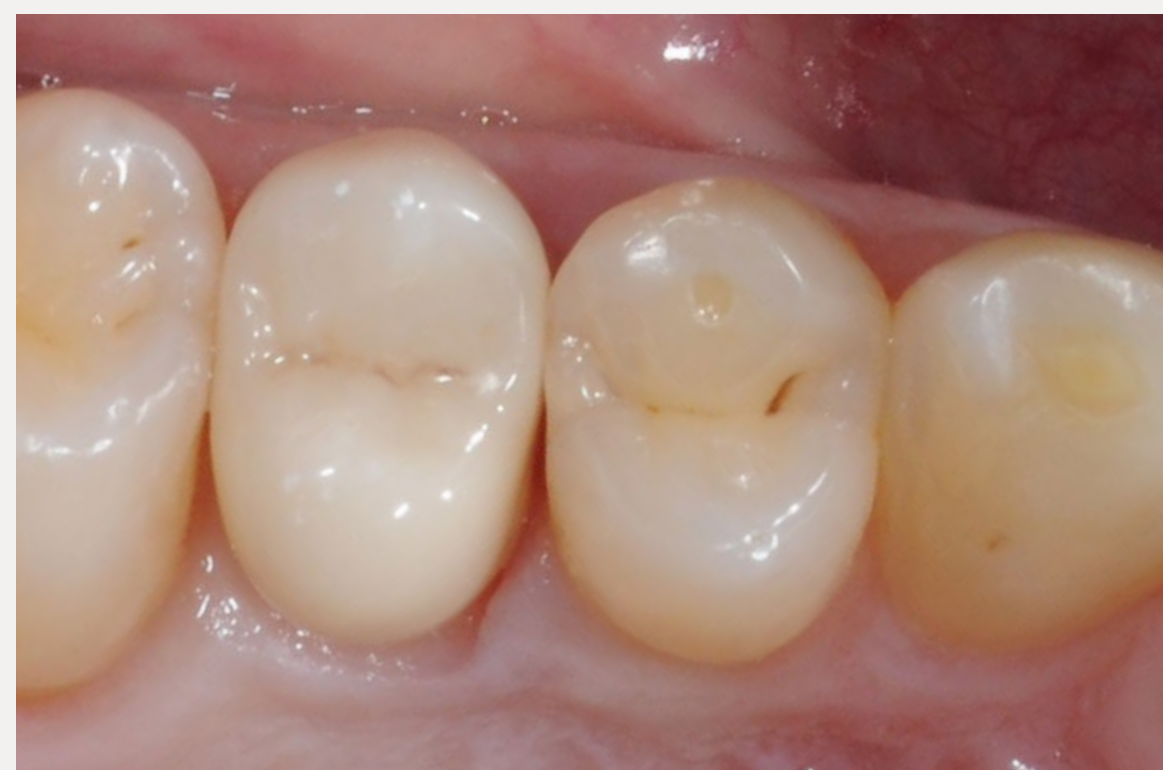Together with the patient, the decision was made in favor of tooth-preserving treatment. The alternative would have been to extract the tooth and replace it with an implant or a bridge restoration. However, this was rejected due to the patient's young age.

Read more 

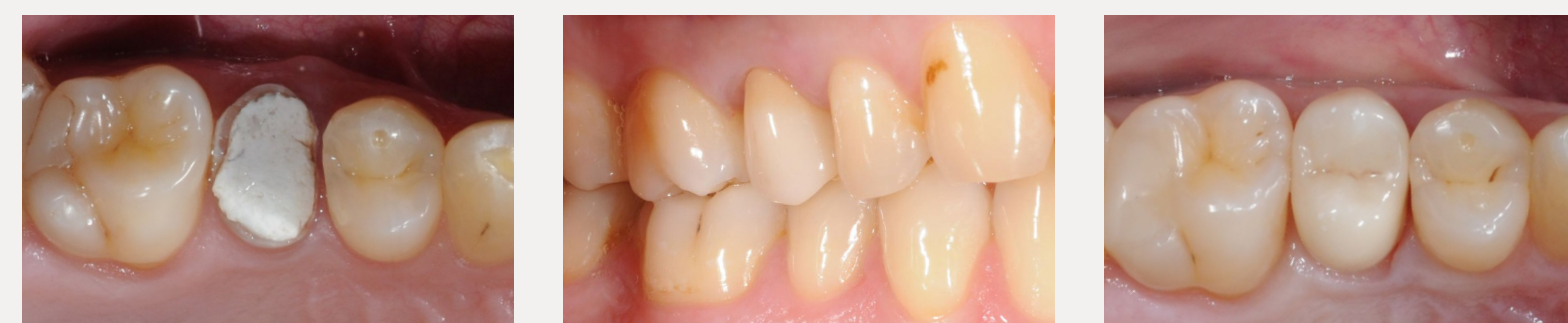Before



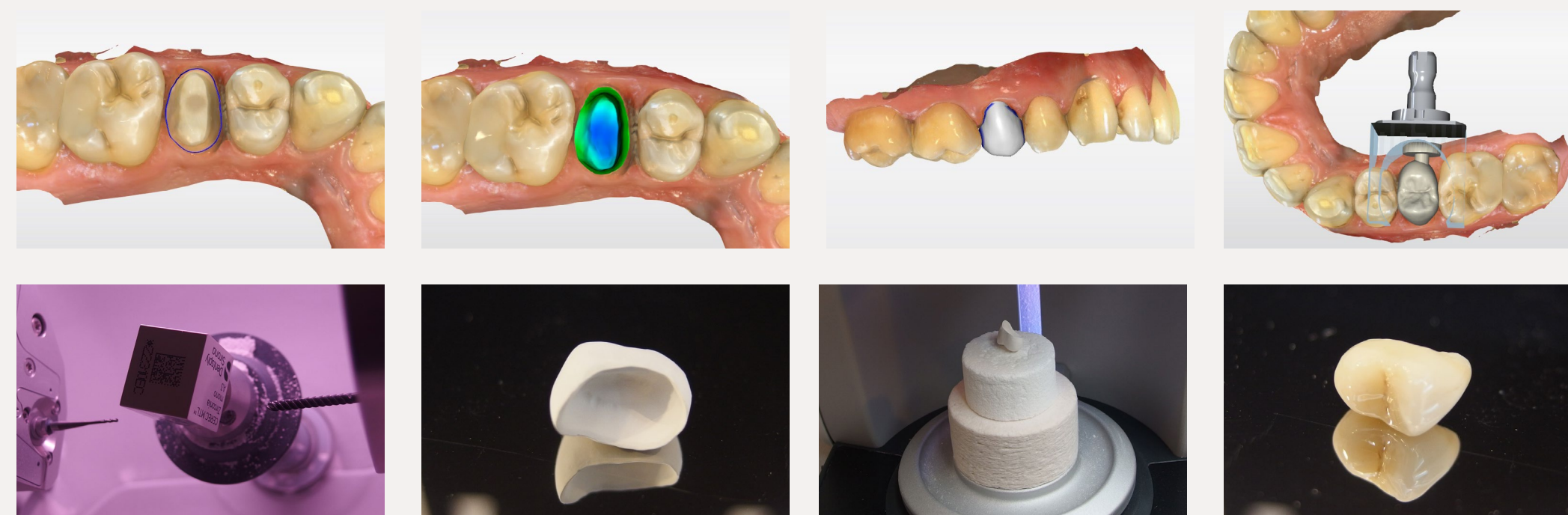
After



Clinical Images



Workflow Images





Two CEREC Tessera crowns and two inlays – Quadrant rehabilitation



Dr. Andreas Bindl
Zurich, Switzerland

Case Description

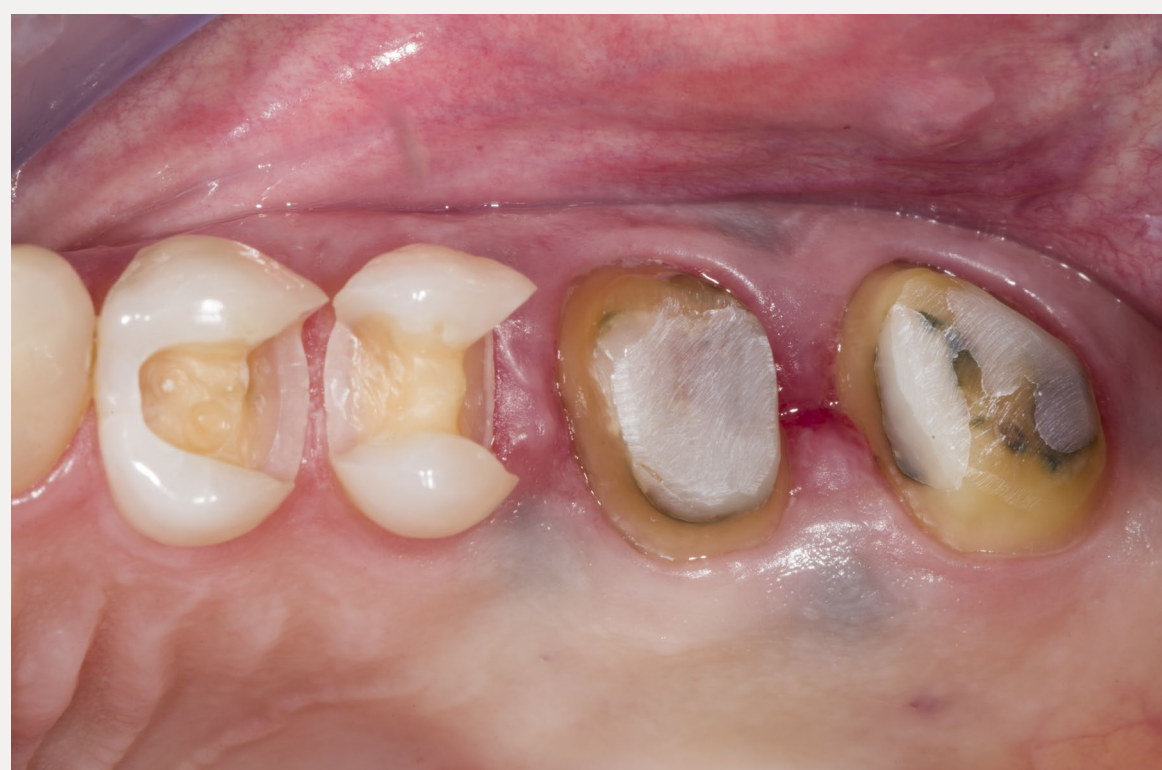A 53-year-old female patient visited my practice with insufficient fillings in the second quadrant. According to the patient, the restorations were about 15 years old. She wanted them to be completely rehabilitated and restored metal-free...

Discussion

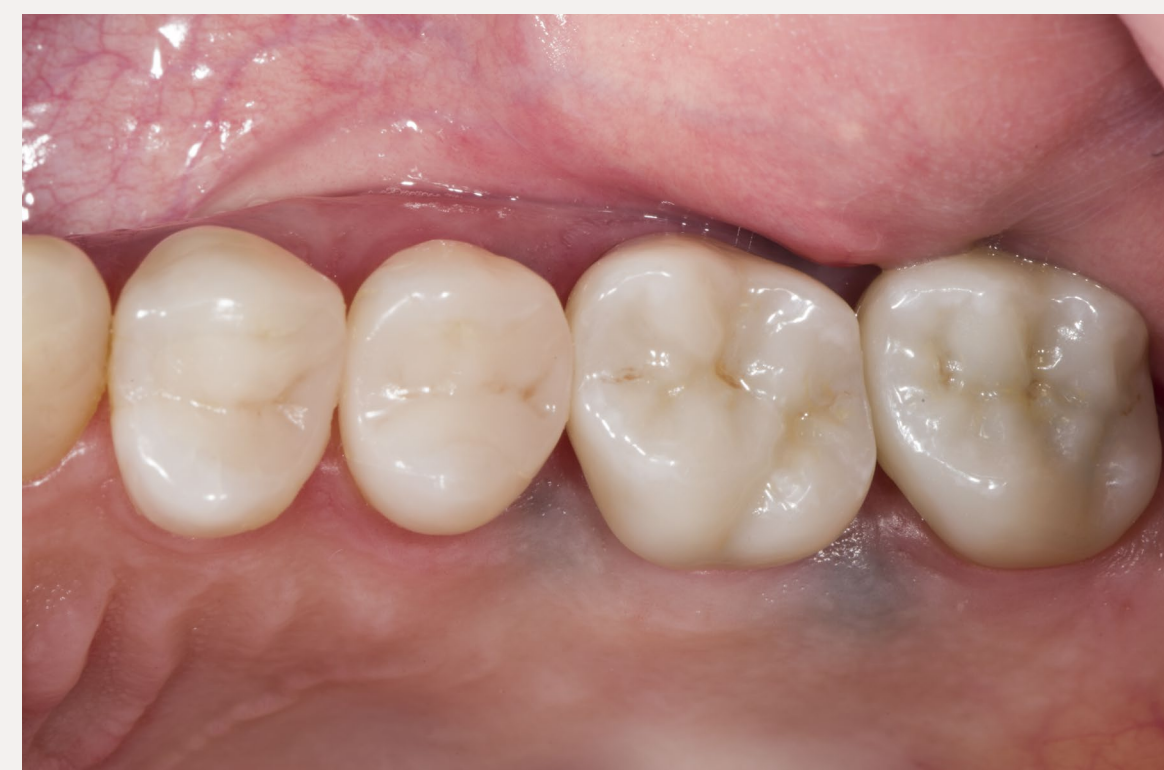The restoration of the second quadrant with two inlays and two full crowns was carried out chairside in a single visit of about four hours. This was possible due to the time-saving fabrication of the restorations with CEREC Primemill...

Read more

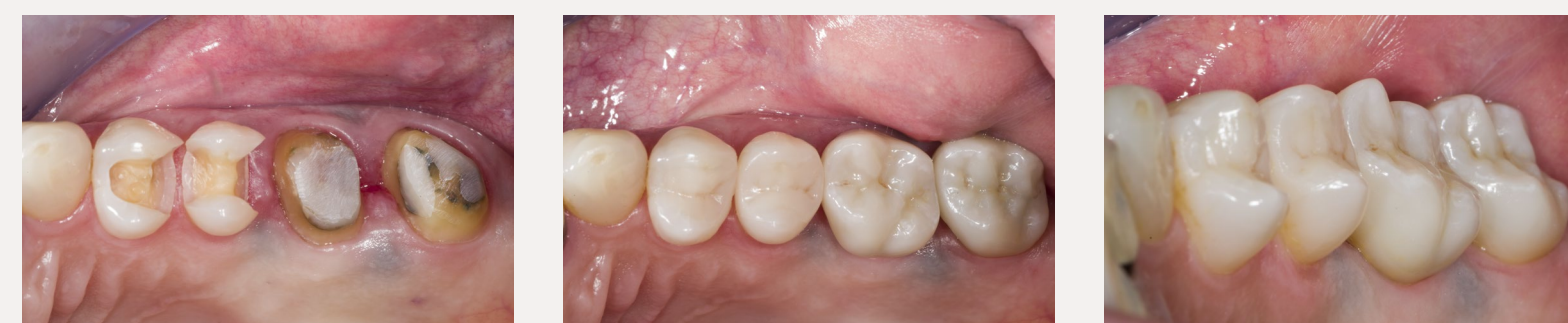Before



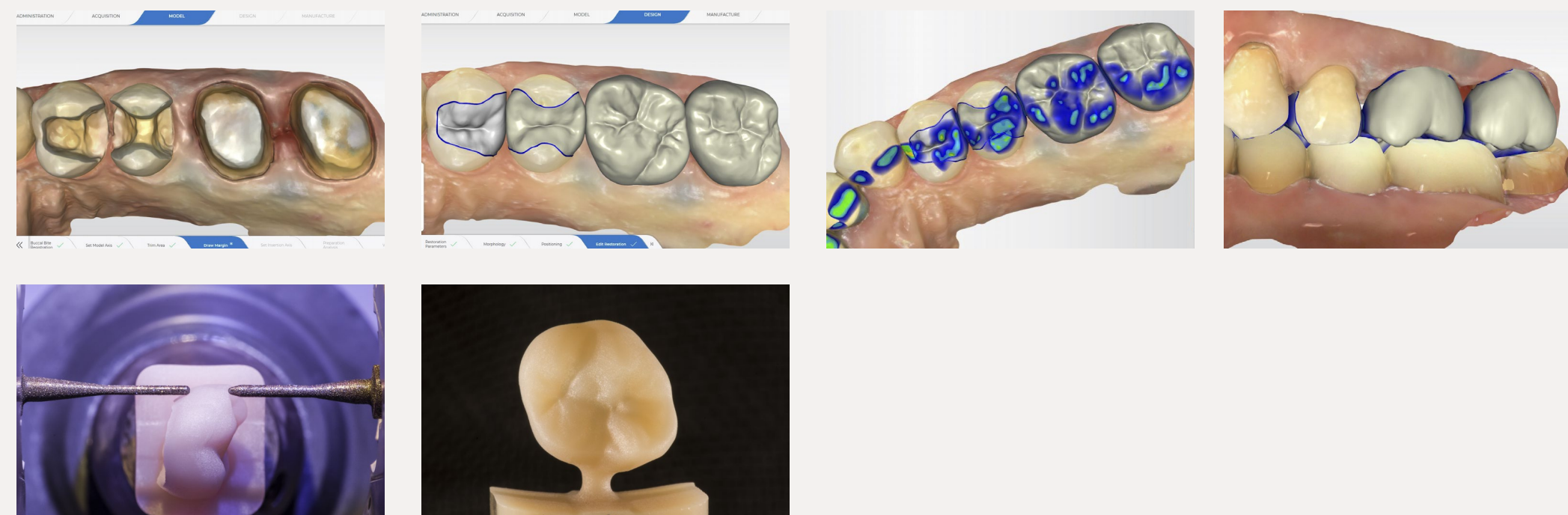After



Clinical Images




Workflow Images





An IPS e.max CAD single crown – Second upper premolar in 60 minutes



Dr. Frank Clark Brown
Melbourne, USA

Case Description

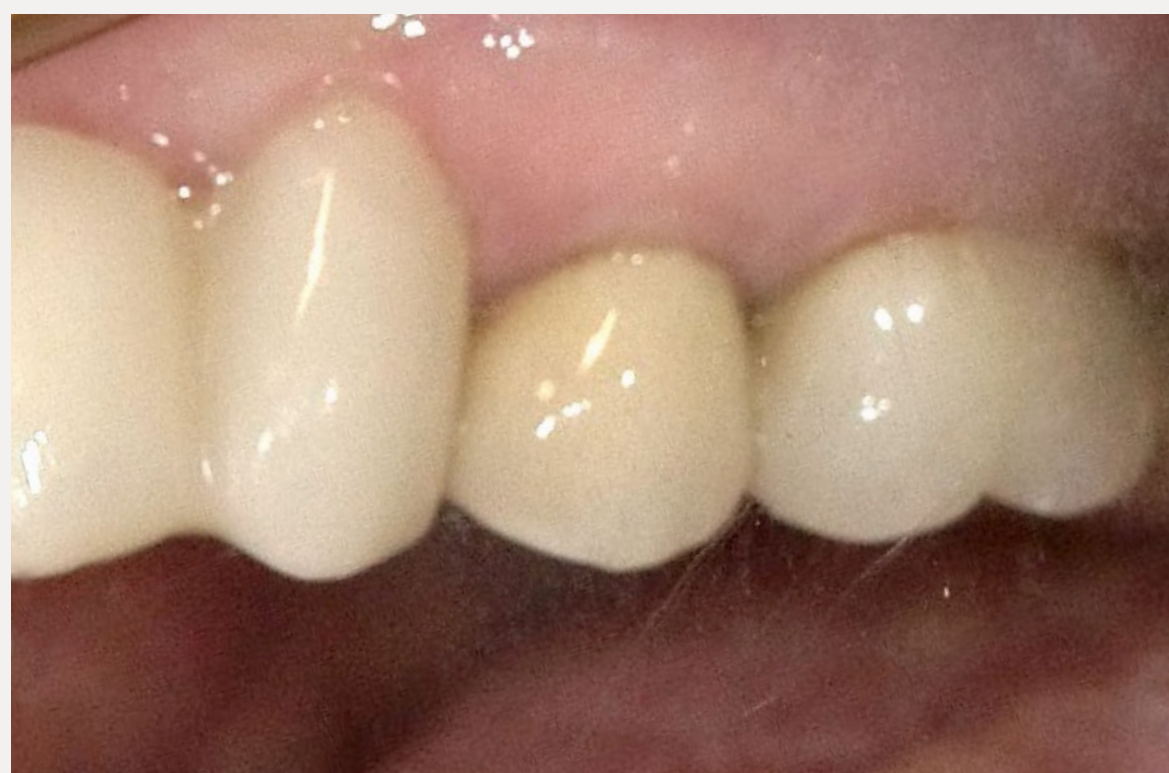The following case refers to a 71-year-old female patient. She was diagnosed with mesial and distal marginal caries on tooth 25. The ceramic veneer of the PFM crown was partially broken. The treatment plan was to restore the tooth with an all-ceramic crown (IPS e.max CAD, Ivoclar Vivadent) after caries removal...

Discussion

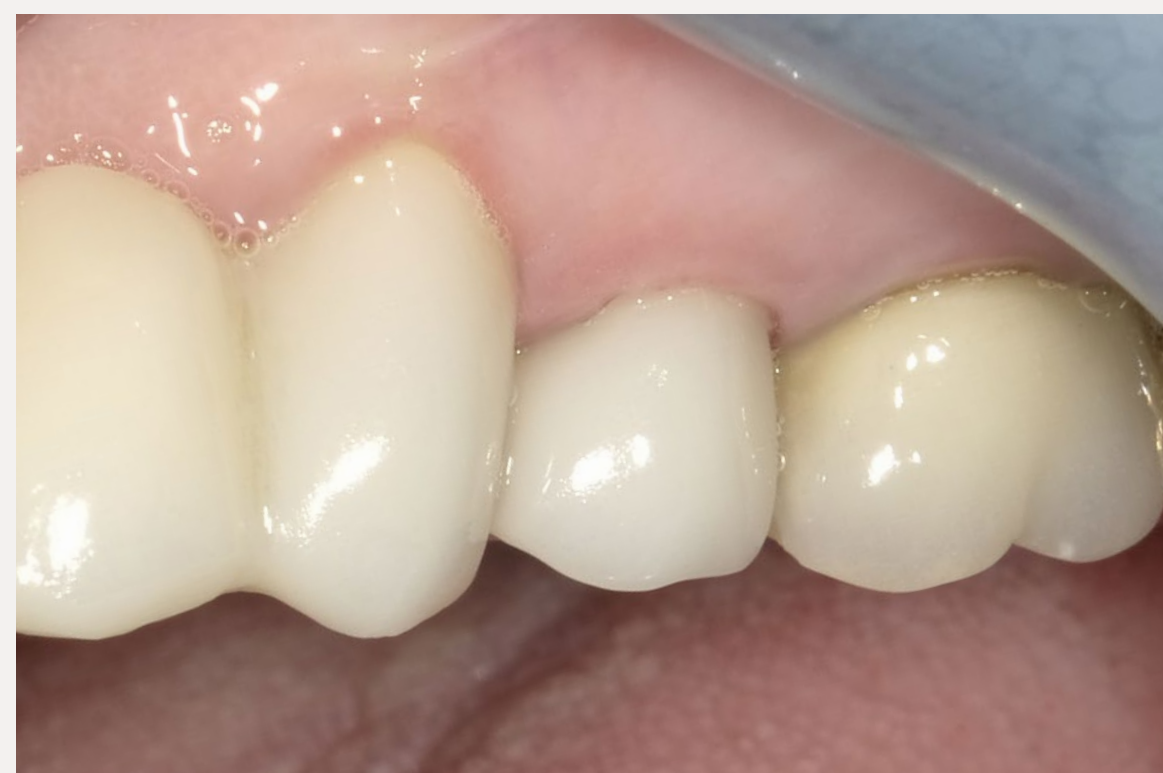The interesting aspect of this case was the workflow speed. Taking the first scan while anesthesia was taking effect already saved a significant amount of time. With CEREC Primescan, the impression could be taken quickly...

Read more

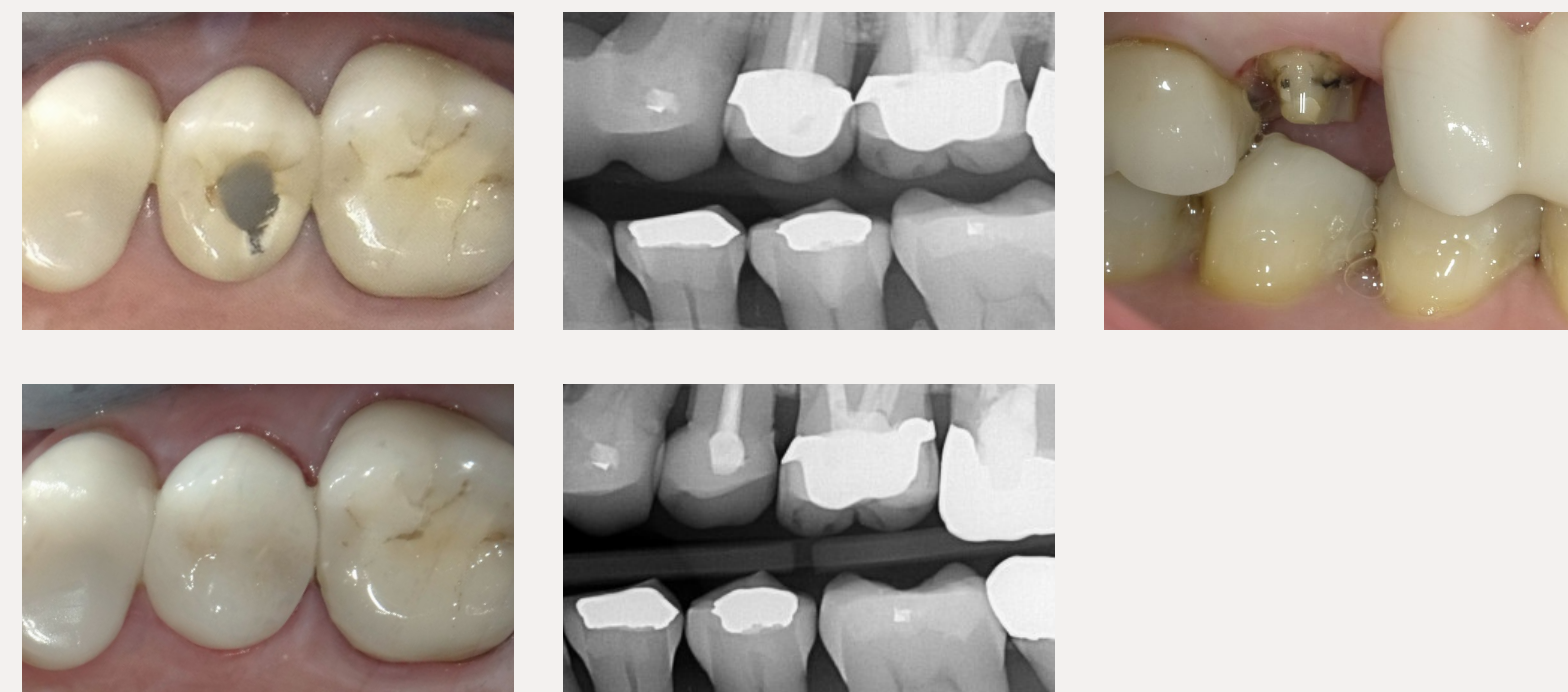
Before



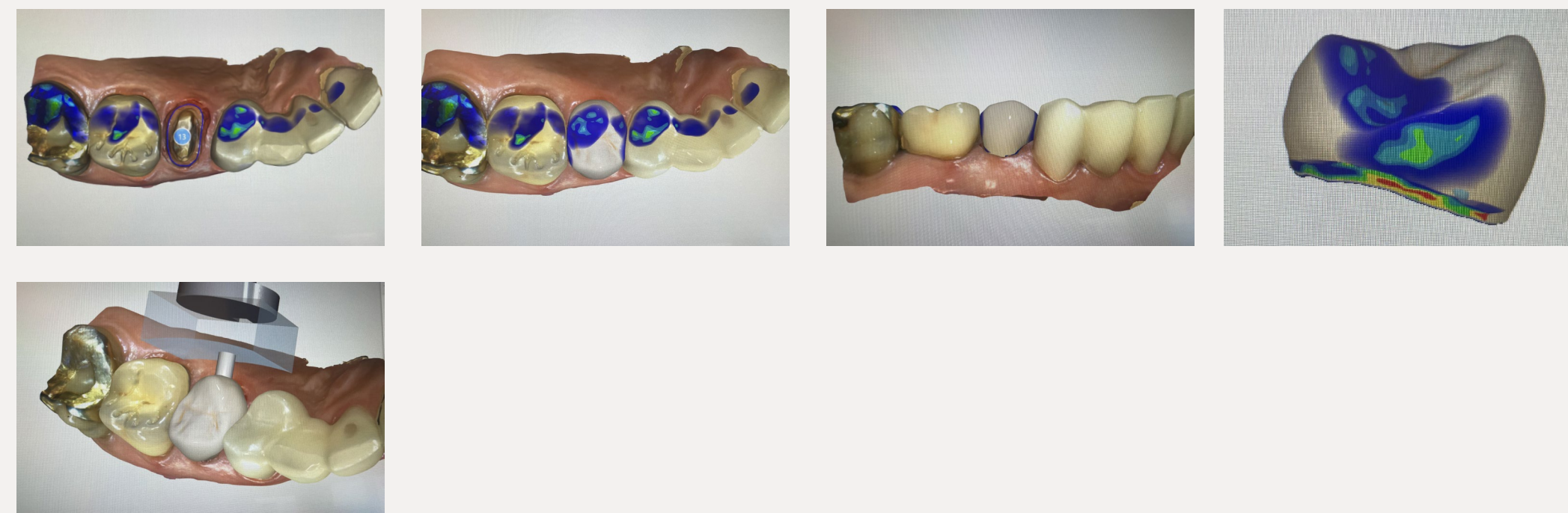
After



Clinical Images



Workflow Images





An IPS e.max CAD single crown – First upper molar in 60 minutes



Dr. Karyn M. Halpern DMD, MS
New York, USA

Case Description

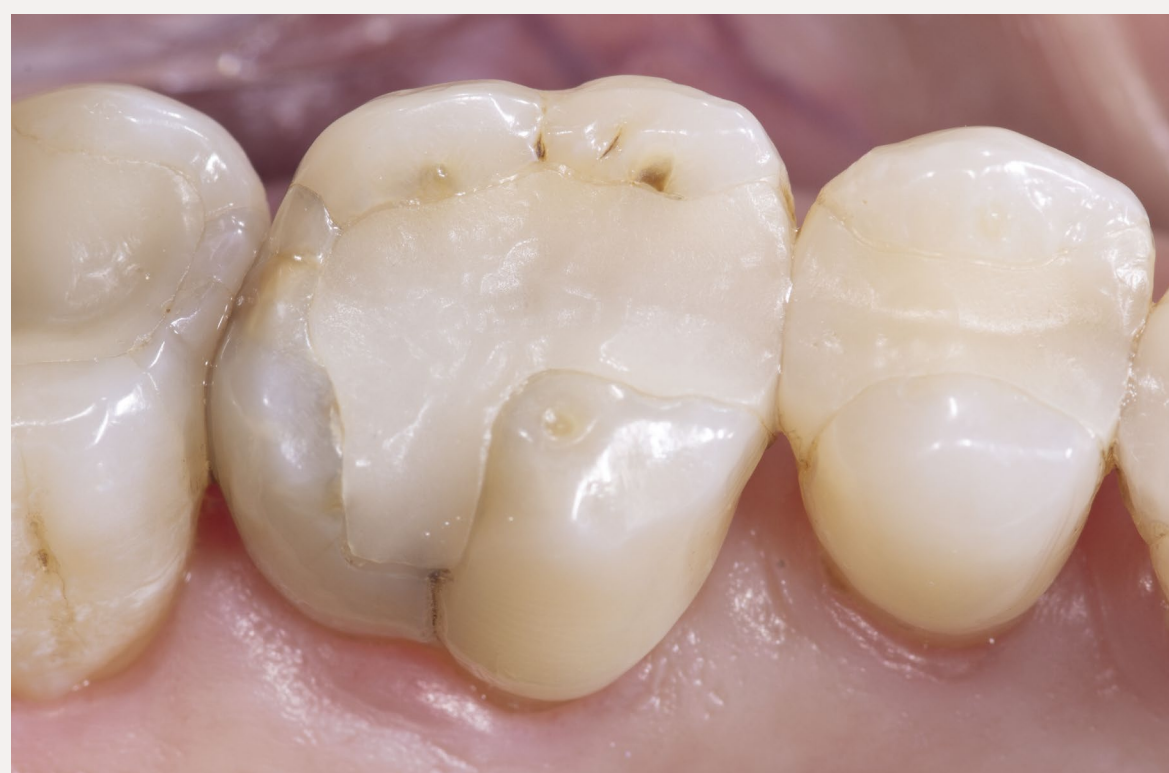A female patient, 47 years old, presented with a slightly intermittent sensitivity to cold at tooth 16. The clinical examination as well as the radiological findings indicated a large insufficiency of the composite filling, with distal marginal ridge cracks, a lingual wall crack, and distal recurrent decay...

Discussion

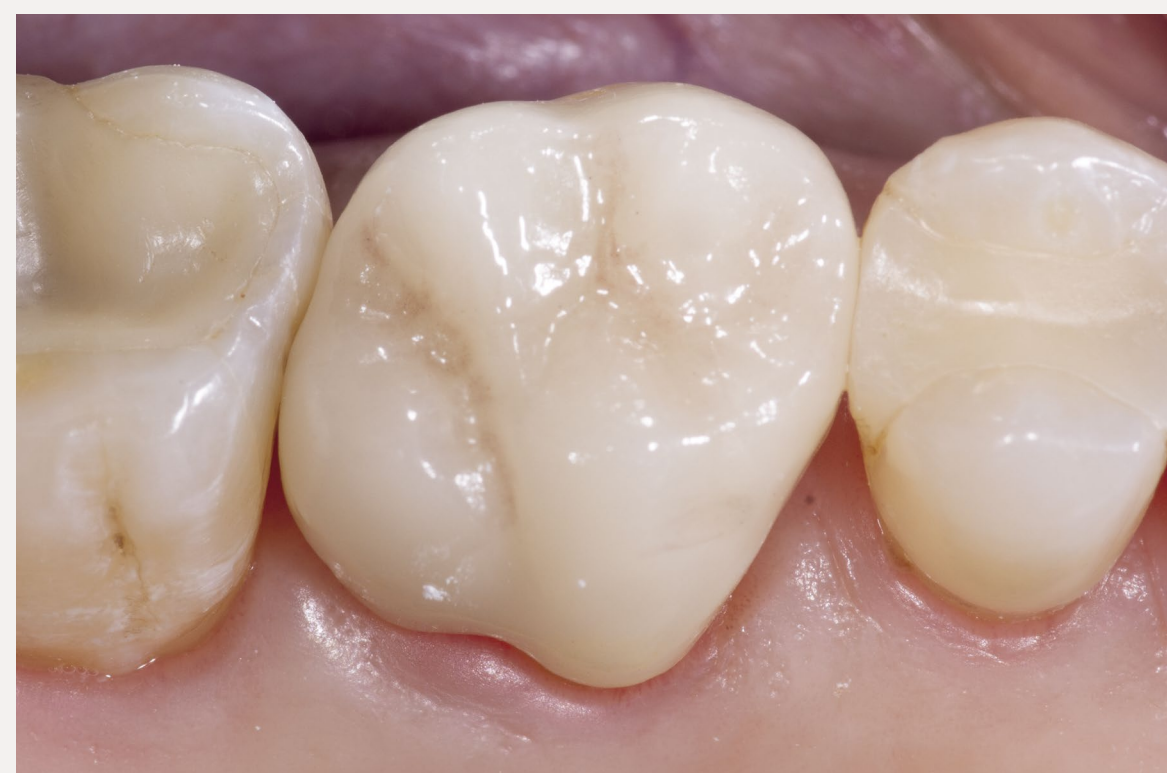The clinical case demonstrates how quickly and efficiently the new CEREC Primemill allows a full-surface glass-ceramic crown to be fabricated chairside in a single session, while meeting a high level of esthetic demands. I can no longer imagine practicing without CEREC Primemill.

Read more

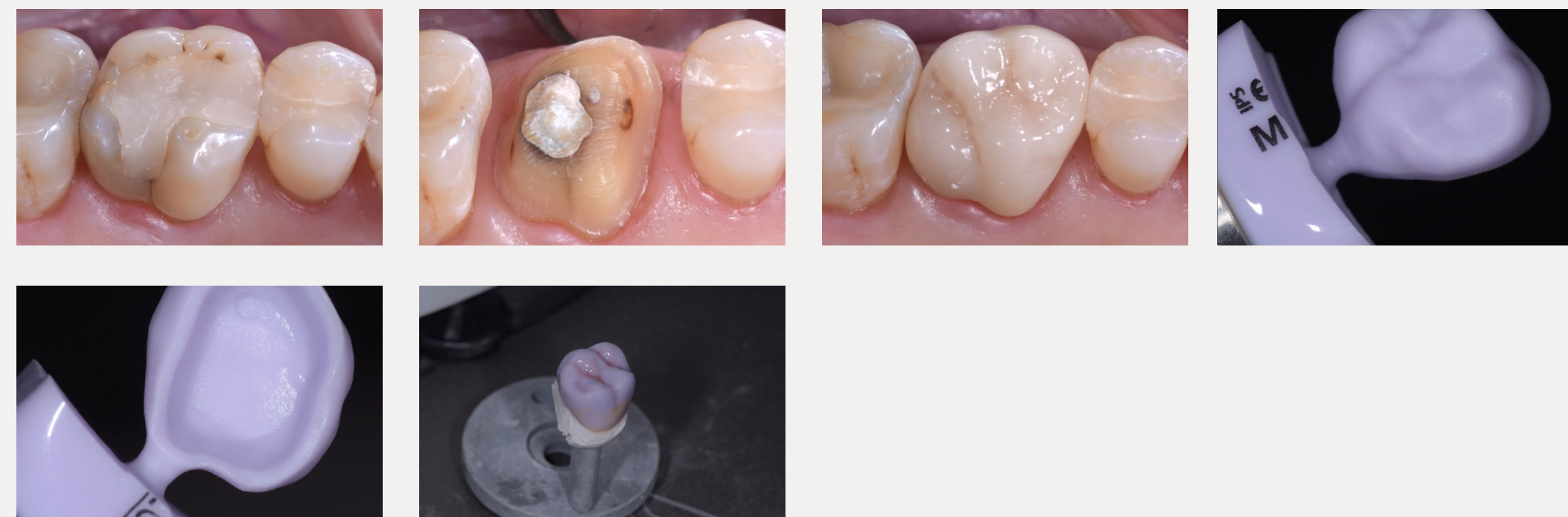
Before



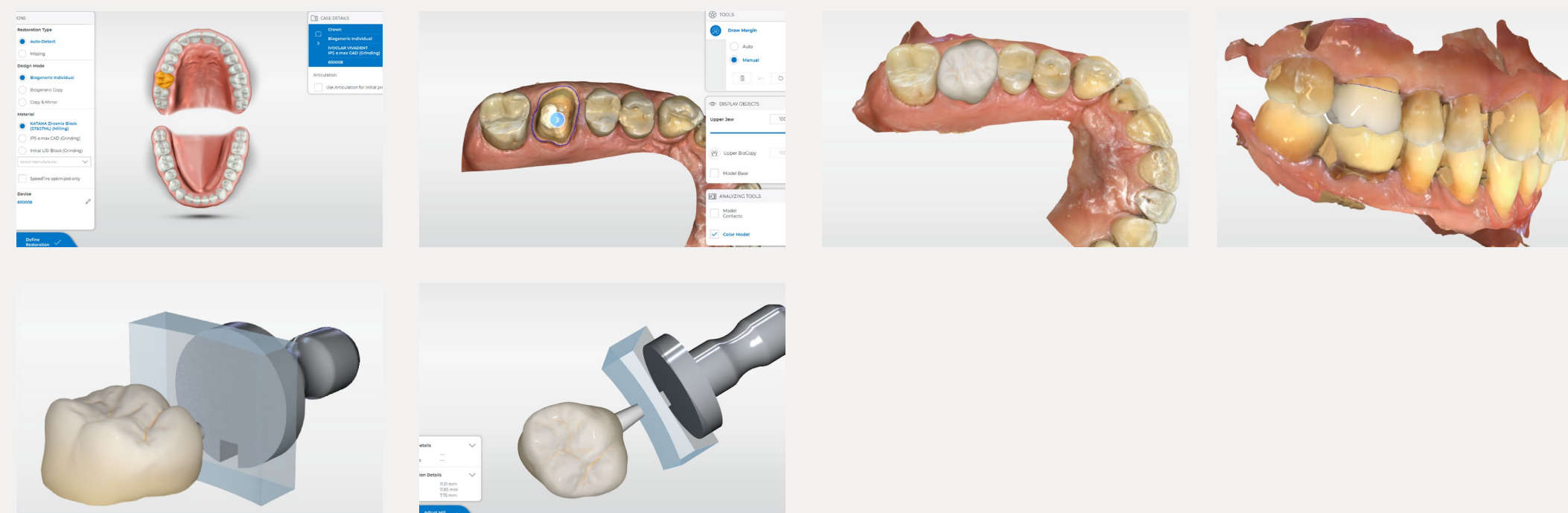
After



Clinical Images



Workflow Images





An IPS e.max CAD single crown – First upper molar in 75 minutes



Dr. Dan Butterman
Centennial, USA

Case Description

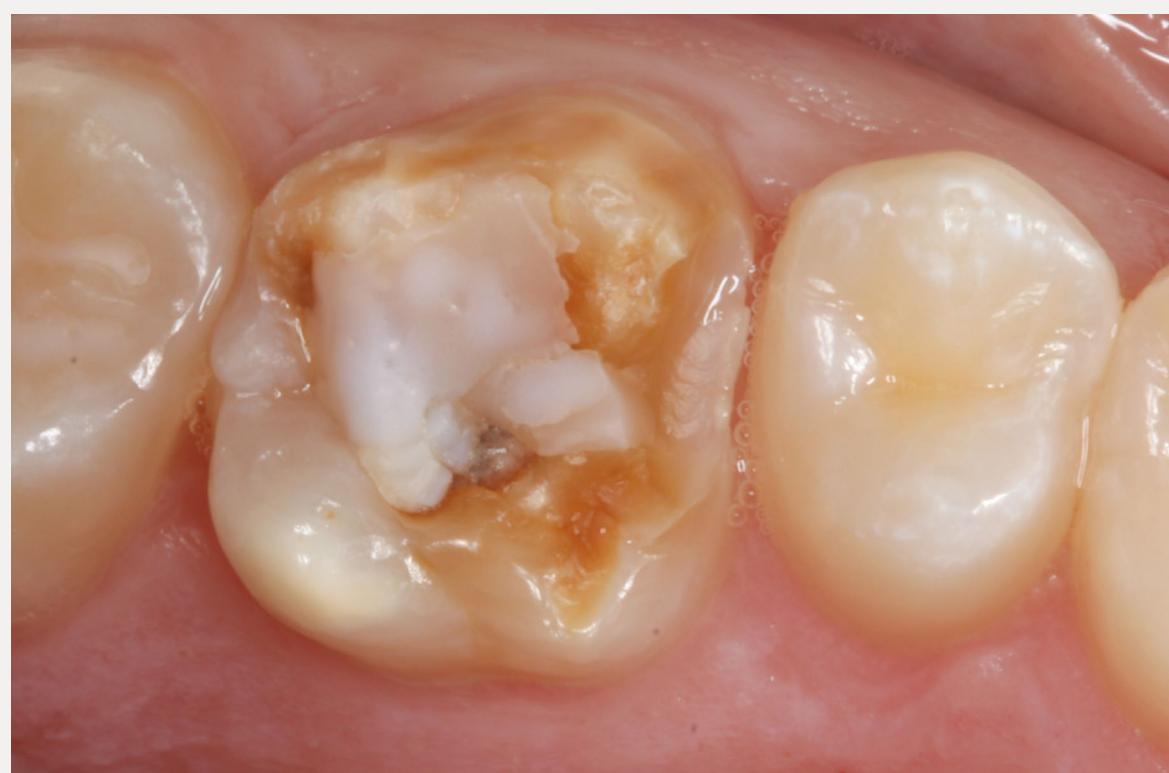A 32-year-old male patient consulted my practice due to decay and a failing direct composite restoration on tooth 26. The treatment plan was to fabricate a full-coverage crown for this tooth in a single visit. After infiltrative administration of anesthesia with Septocaine®, tooth 26 was prepared for a crown...

Discussion

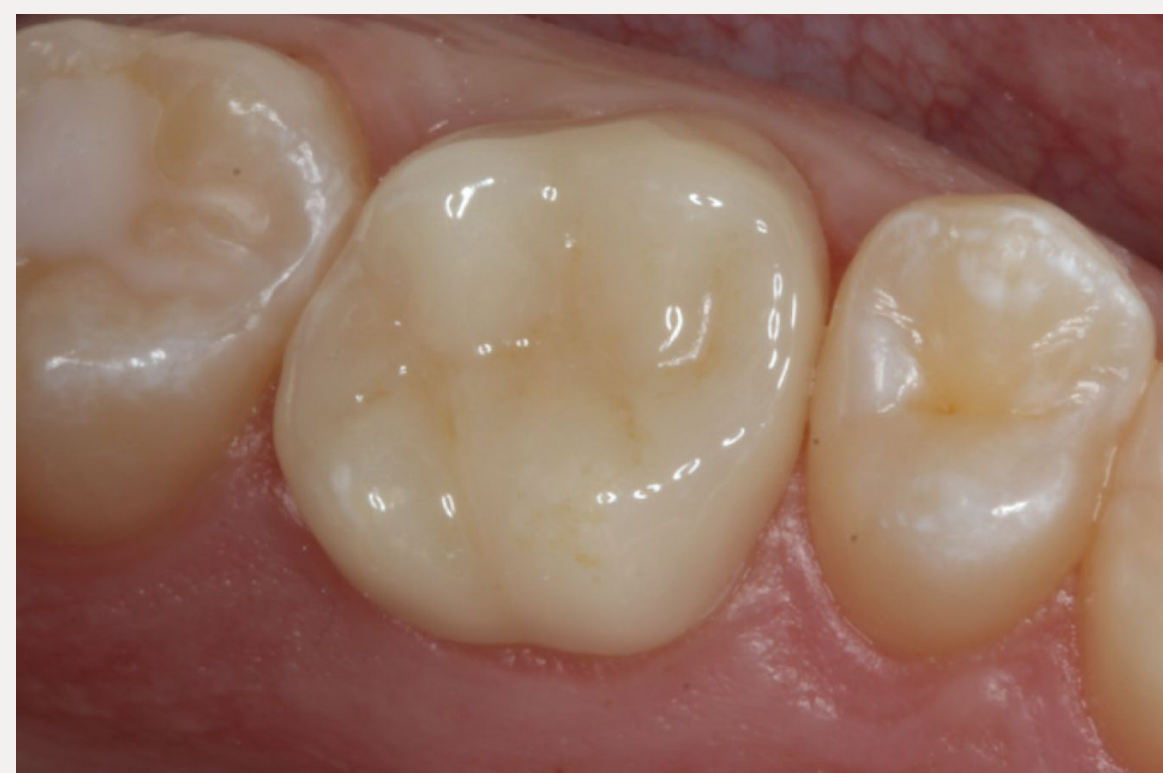Producing restorations in just one session is now faster than ever before. A quick and very accurate scan, manageable and intuitive design software, combined with a milling and grinding unit that completes a restoration in just a few minutes, makes for a significant increase in efficiency and great patient satisfaction with my practice.

[Read more](#)

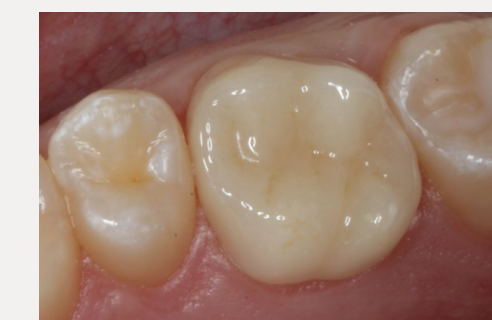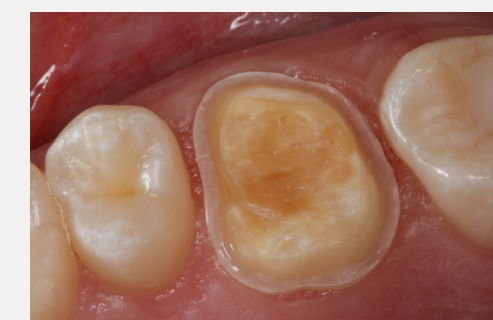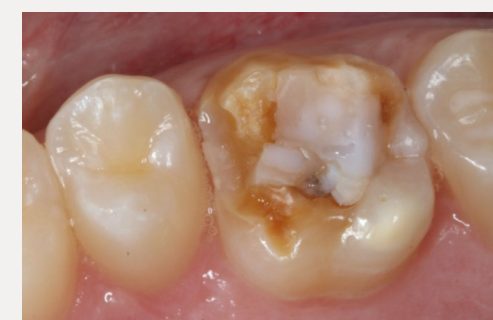Before



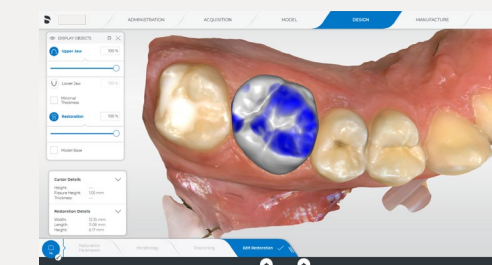
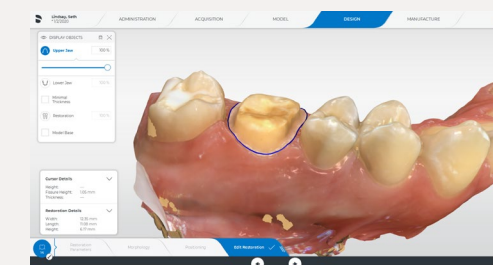
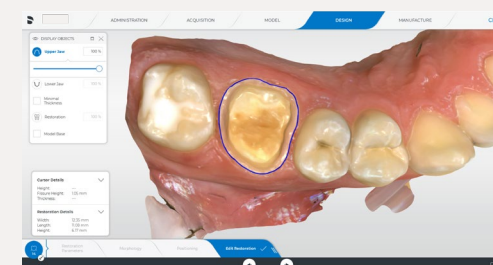
After



Clinical Images +



Workflow Images +





A Katana Zirconia STML single crown – Second lower premolar in 90 minutes



Dr. Gertrud Fabel
Munich, Germany

Case Description

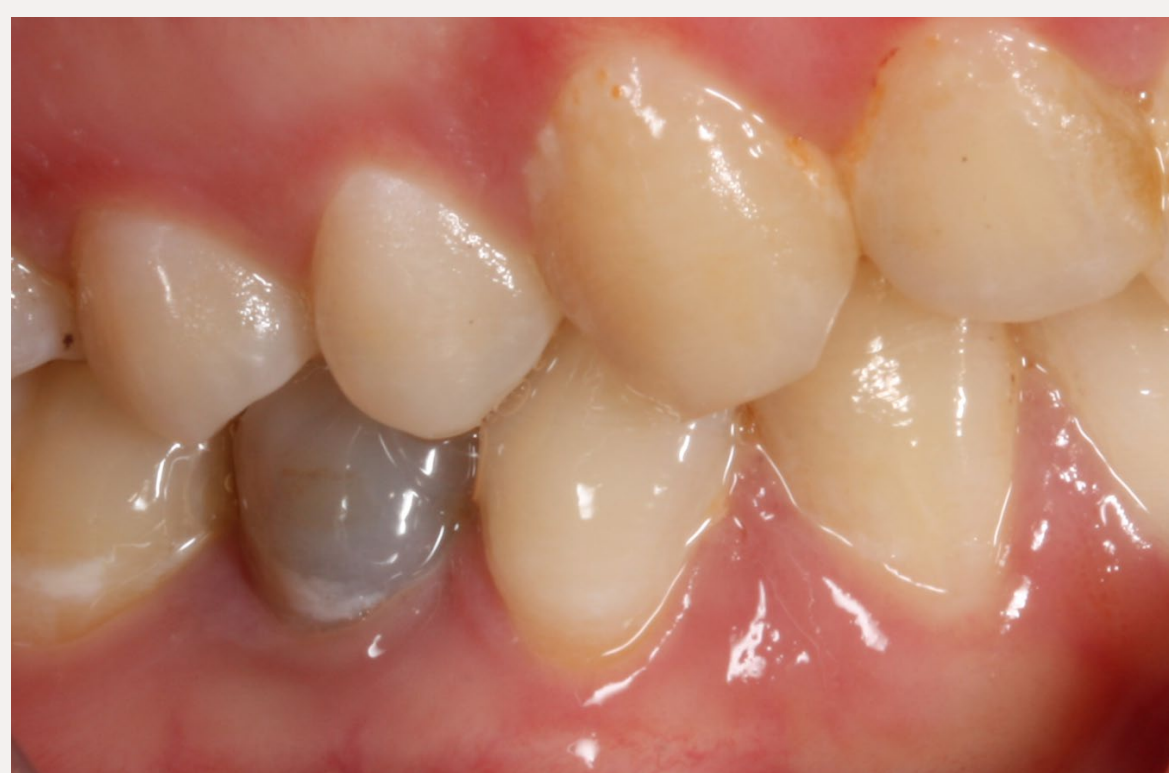A 21-year-old student came to my practice and wanted an esthetic solution for her tooth 45. She reported dissatisfaction with a root canal treatment done elsewhere and was very unhappy about the discoloration of the tooth now, which led to an inconsistent overall impression...

Discussion

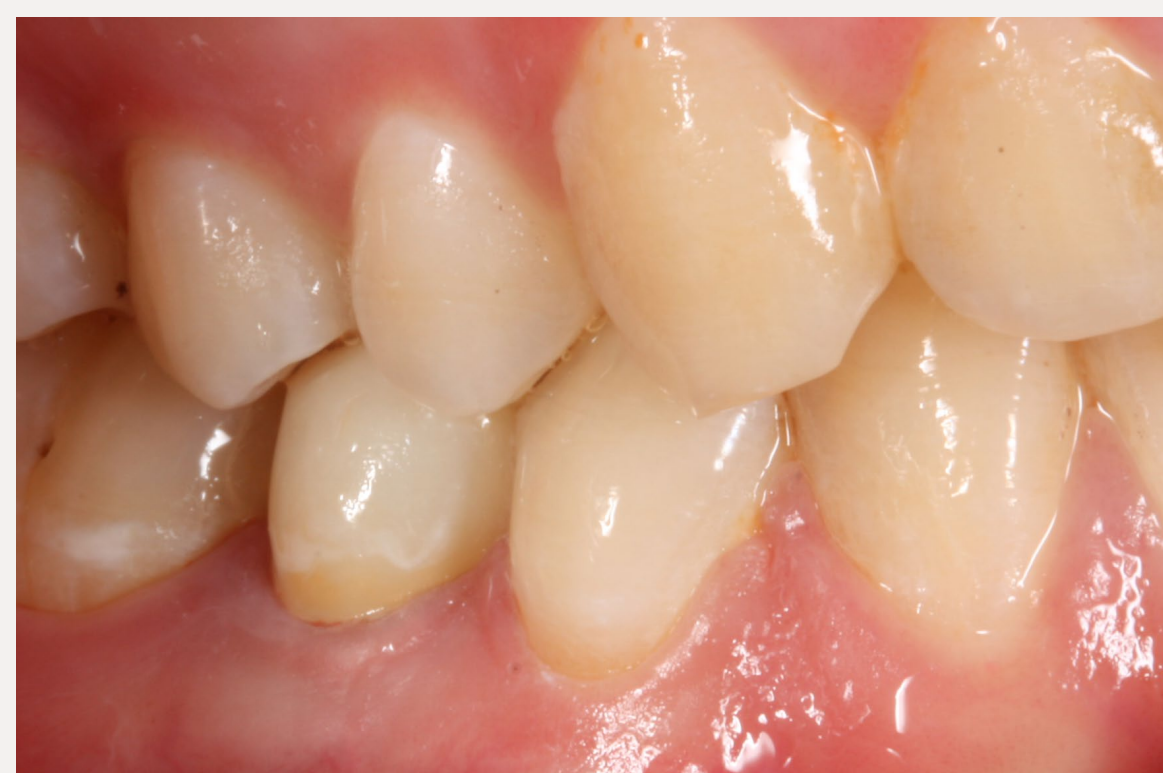Thanks to the newly achieved CEREC workflow time, the restoration of this premolar was very well suited for the chairside treatment with zirconia, which took only about 90 minutes in total. We were able to use full-contour zirconia, a material that has good properties for this area of the tooth and, thanks to...

Read more

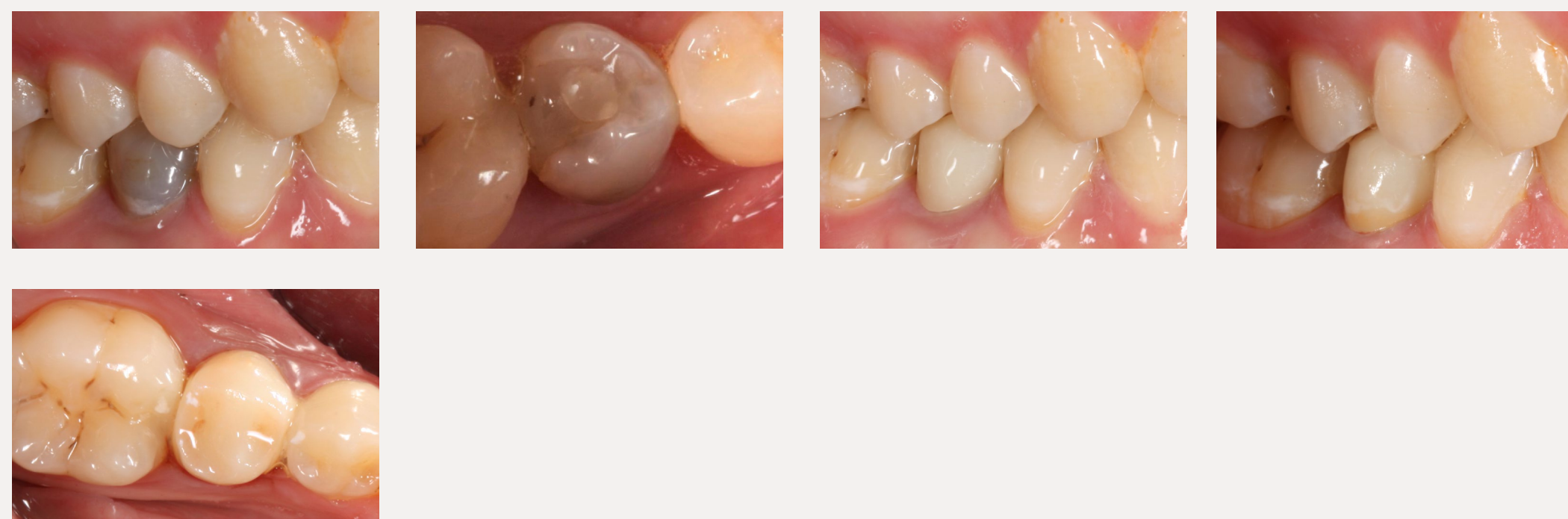
Before



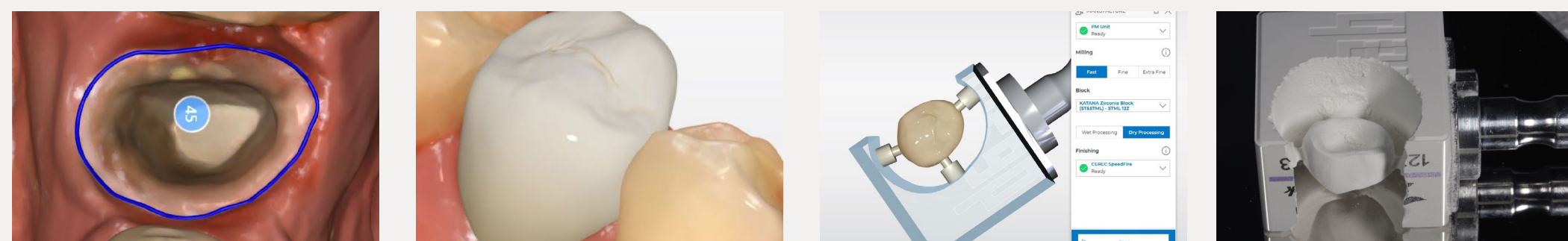
After



Clinical Images +



Workflow Images +





A Katana Zirconia STML single crown – First upper molar in 90 minutes



Dr. Mike Skramstad, DDS
Orono, USA

Case Description

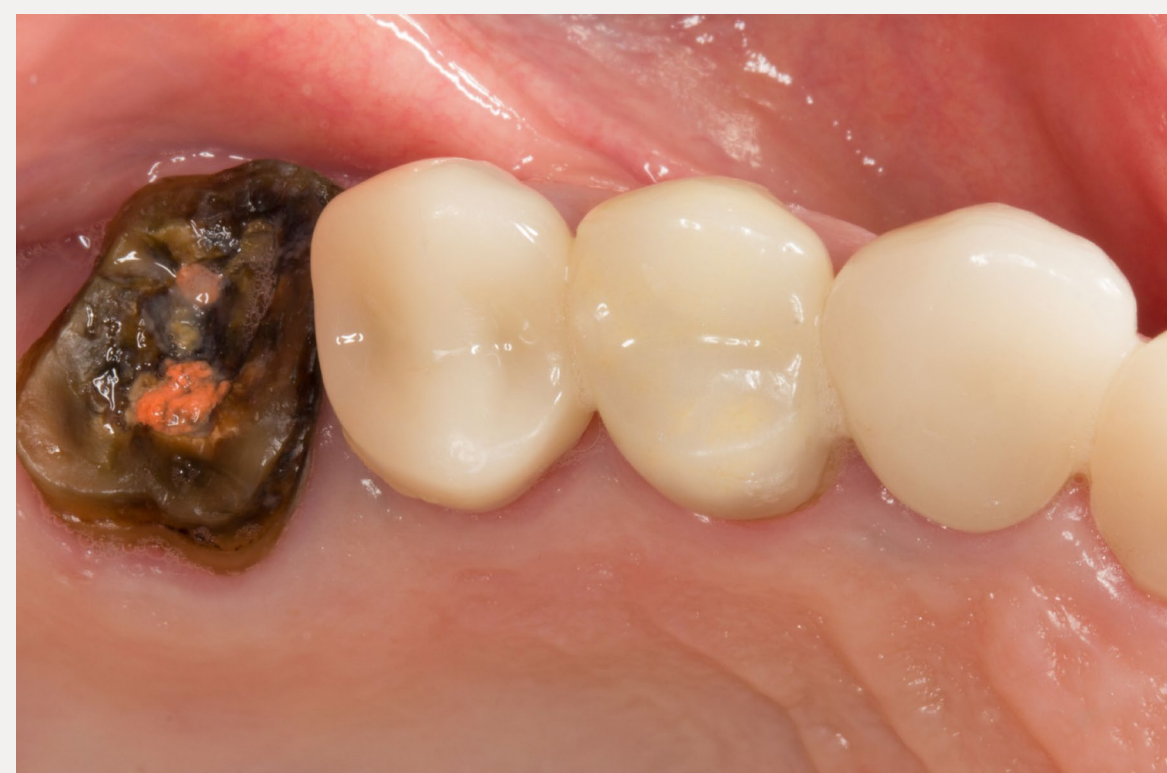A 72-year-old patient came to my practice with a fractured metal-ceramic crown on tooth 26, which had previously been treated endodontically. The tooth was free of caries and oral hygiene was very good. Our plan was to maximize the resistance and retention shape, and to fit the tooth with a new...

Discussion

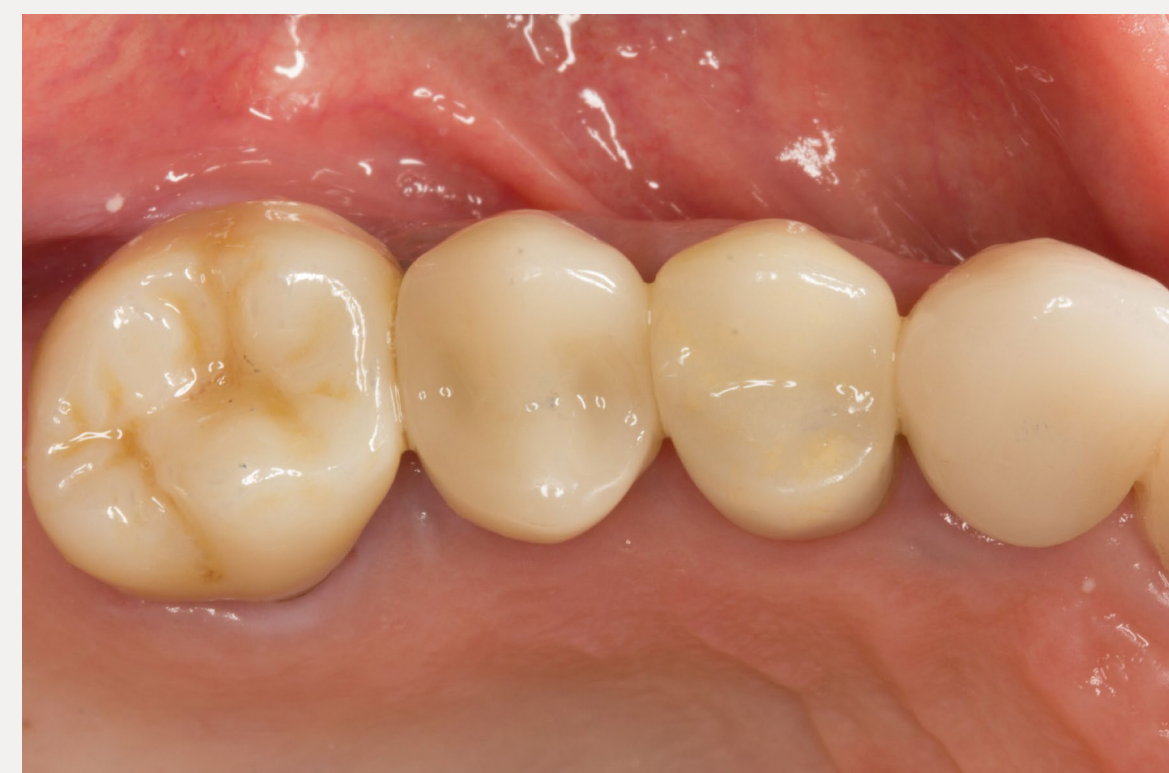The final restoration fit excellently and needed no post-cementation adjustments. The great thing about the Extra Fine milling mode is that it provides us with the option to create additional detail. The CEREC Primemill not only brings speed to the appointment, but also versatility in milling strategies...

Read more

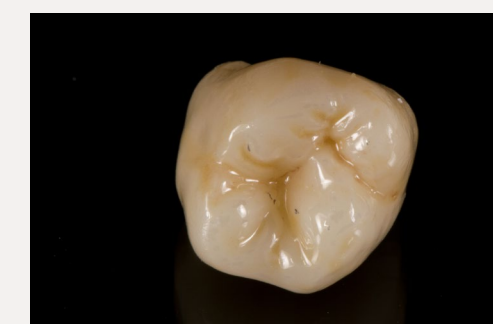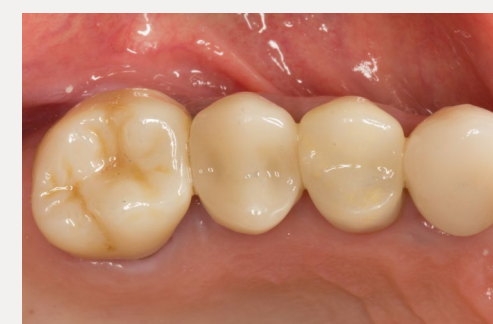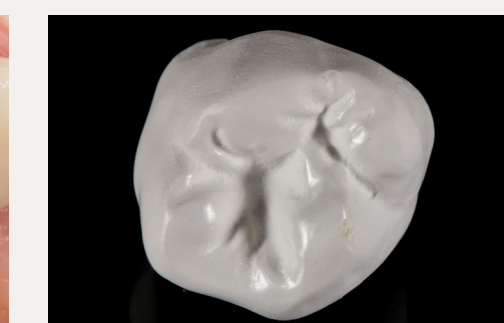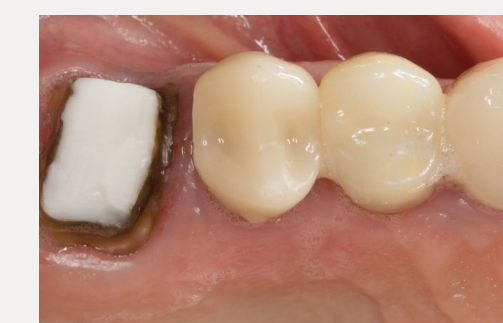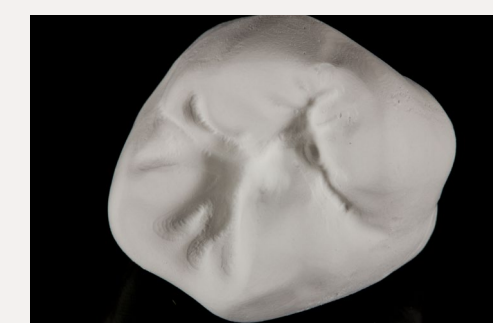
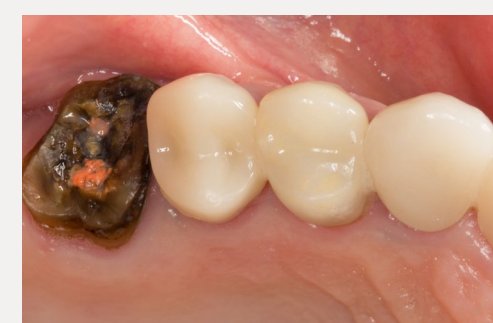Before



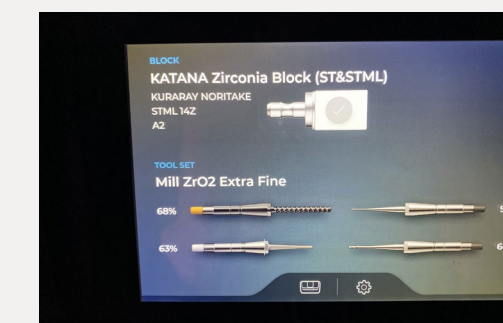
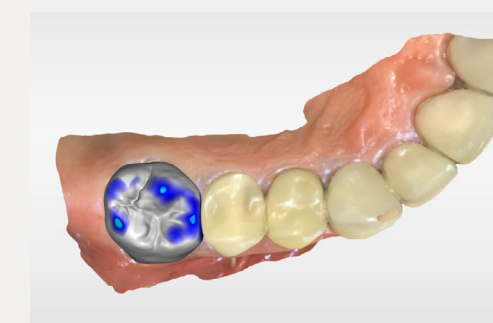
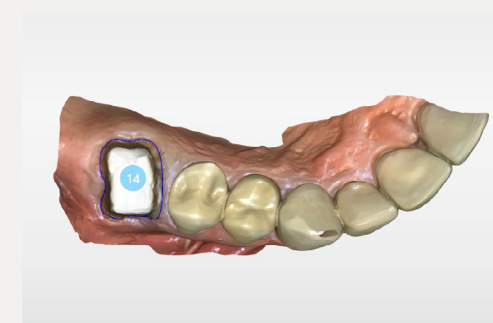
After



Clinical Images



Workflow Images

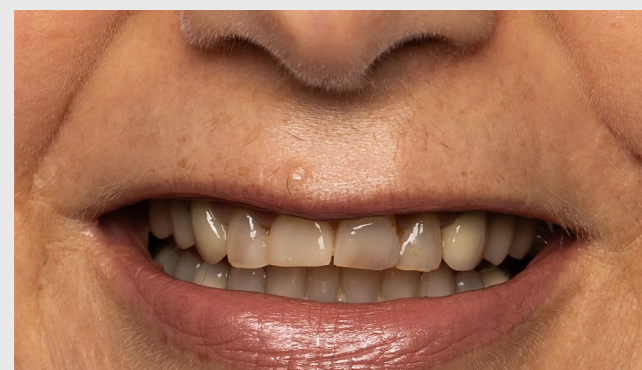



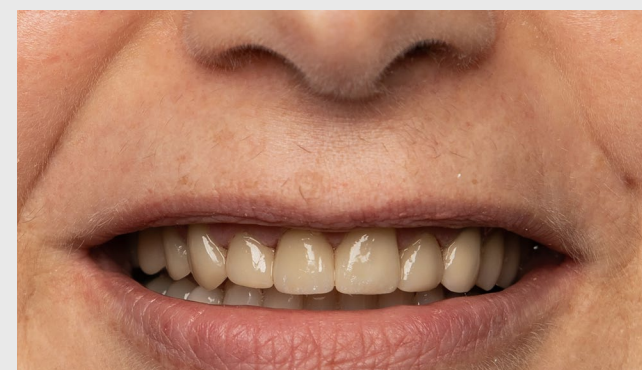Anteriors

Upper central incisors
IPS e.max CAD

1



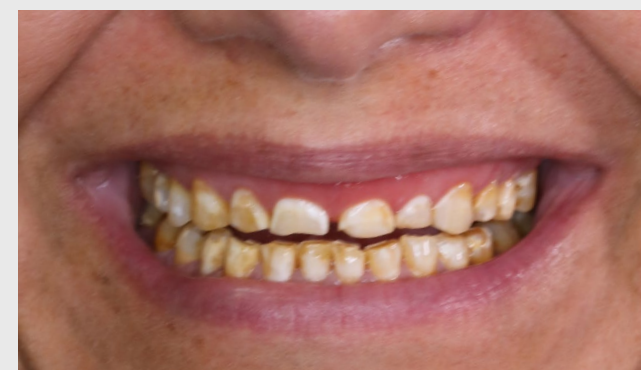before



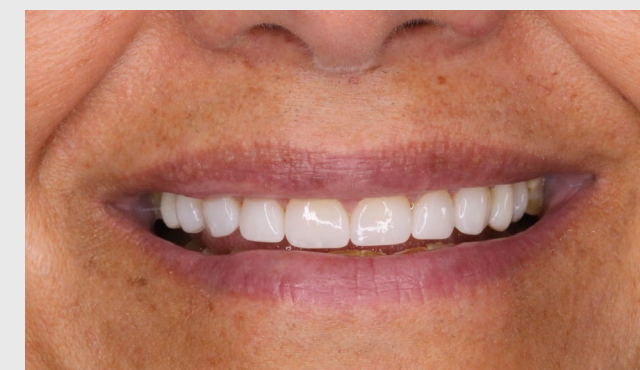after

Quadrant rehabilitation
VITA Suprinity PC

2



before



after



Four IPS e.max CAD single crowns – Upper central incisors in 4 hours



Claudia Scholz
Kiel, Germany

Case Description

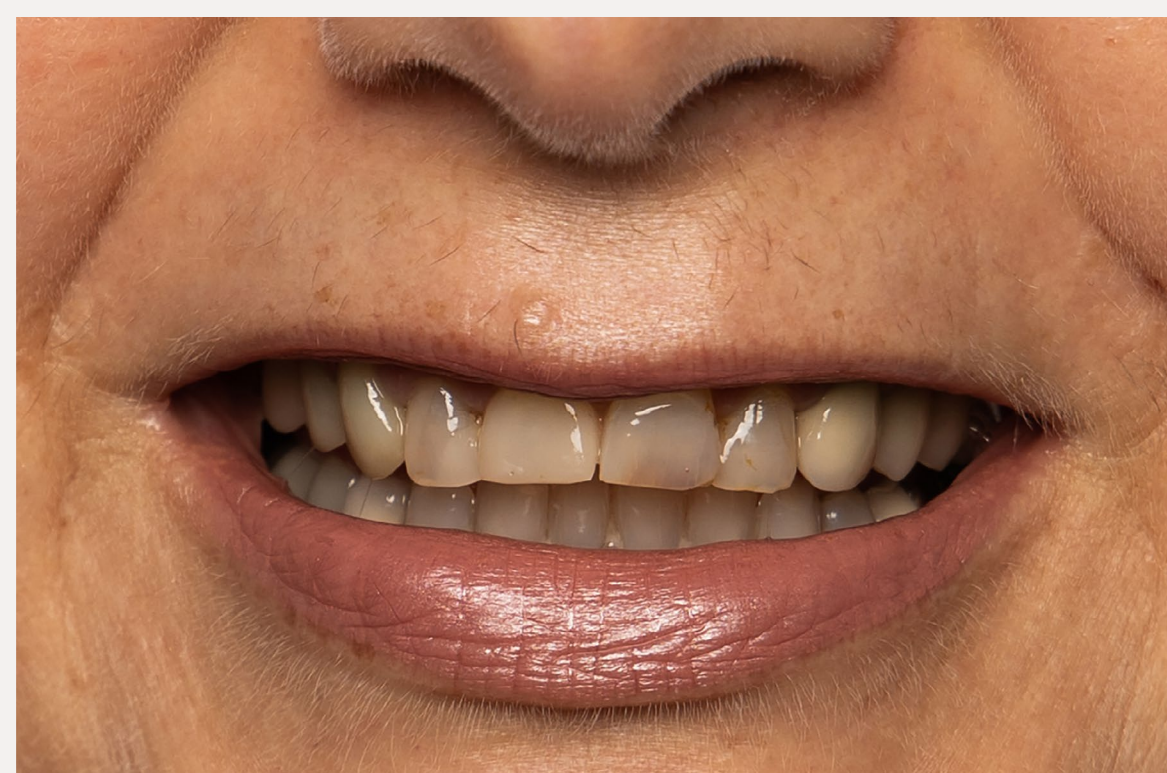A 53-year-old patient came to my practice with problems in her front teeth. The examination revealed inadequate fillings on teeth 12-22 and an uneven gingival line on 12 and 11. The patient turned down the option of a surgical adjustment...

Discussion

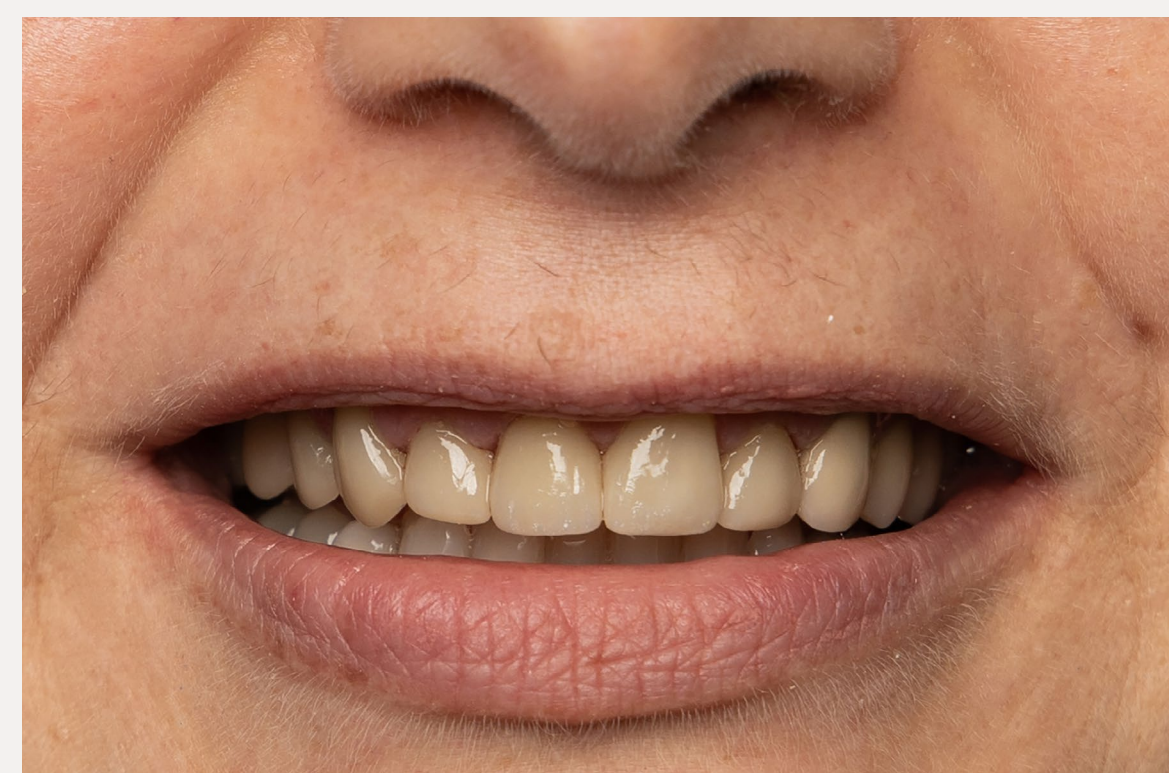For anterior teeth, particularly high esthetic requirements apply, which can also be met very well with ceramic-veneered metal or ceramic crowns. However, the disadvantage is that a conventional impression and a temporary restoration would have been necessary until the final restoration was completed in a lab.

[Read more](#)

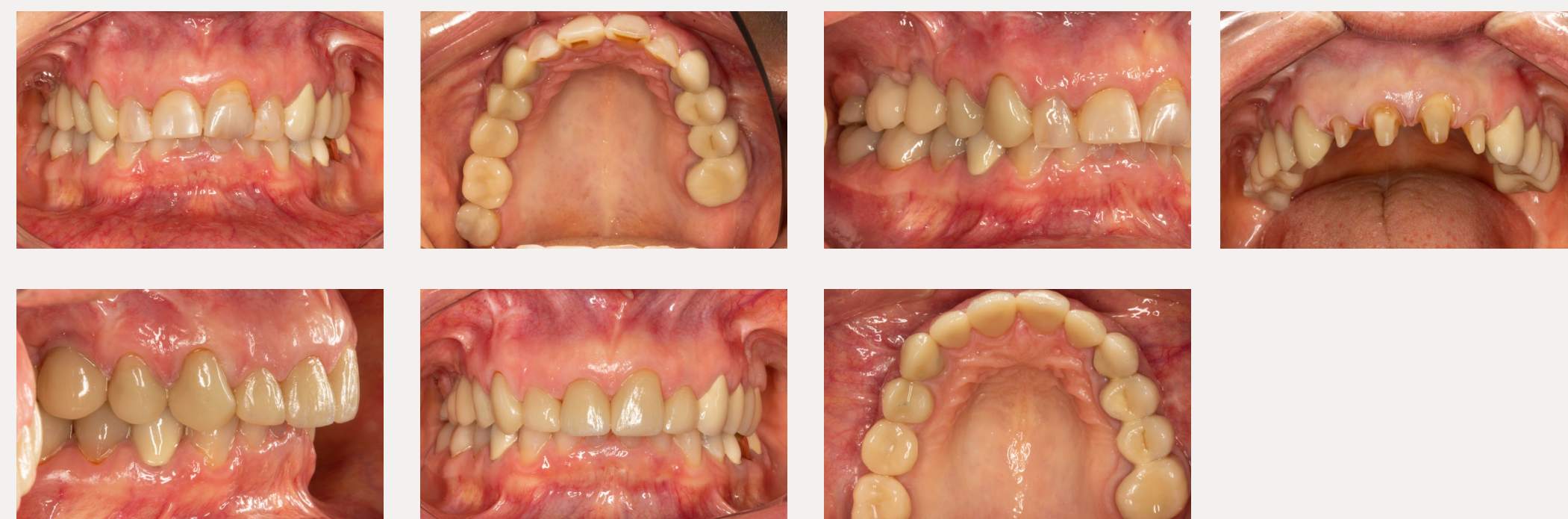Before



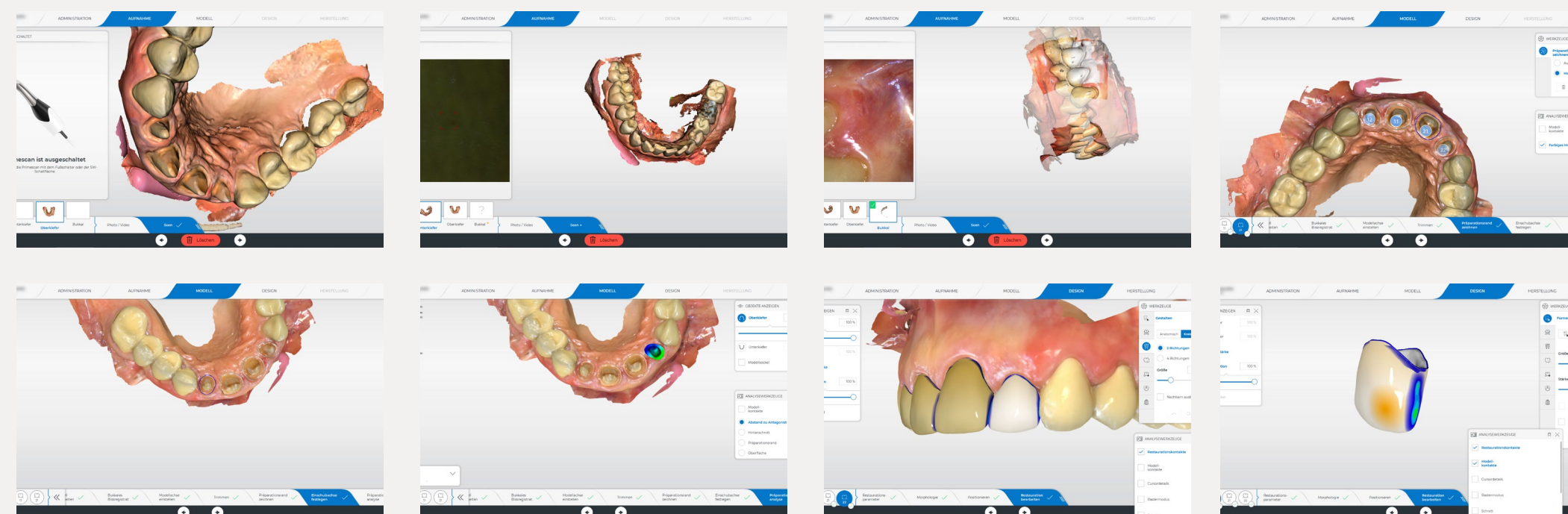
After



Clinical Images +



Workflow Images +





Ten VITA Suprinity PC single crowns – Quadrant rehabilitation in 2 sessions



Dr. Daniel Vasquez
San Diego, USA

Case Description

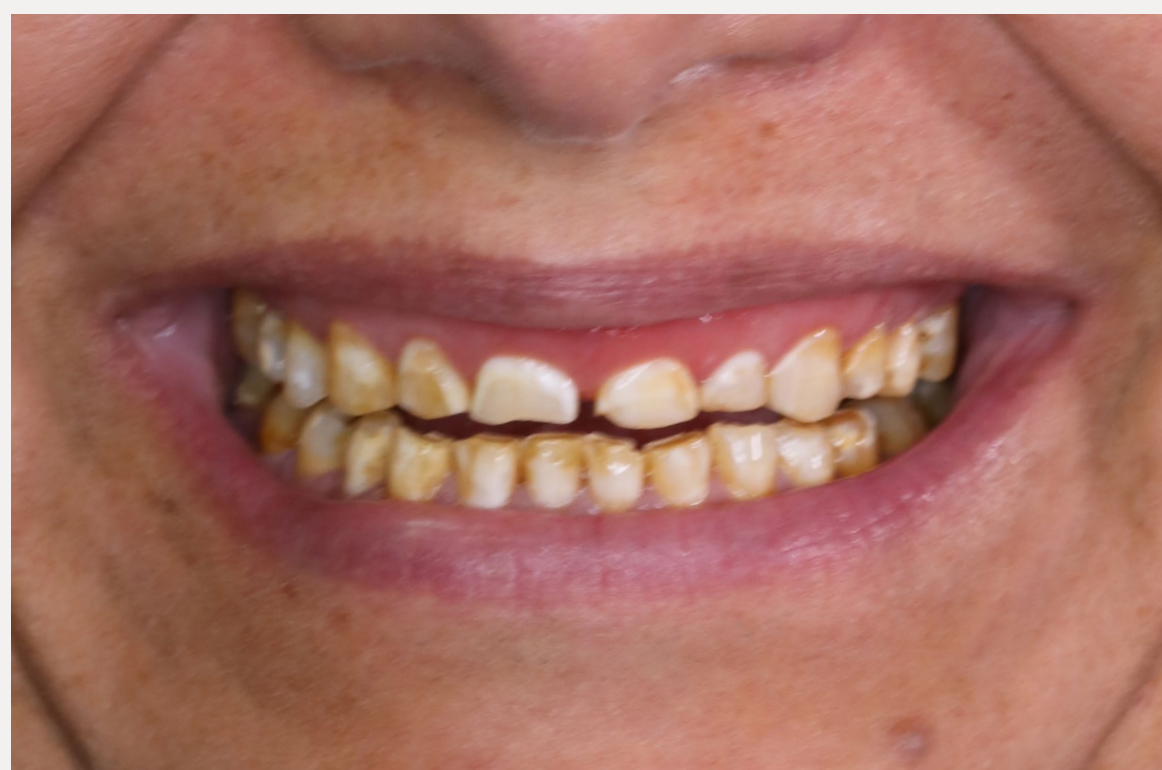A 62-year-old female patient came into my dental office for a check-up and dental cleaning. She has been a patient in the practice for seven years and now complains that she hardly dares to smile. She was dissatisfied due to discoloration and wanted to improve her smile...

Discussion

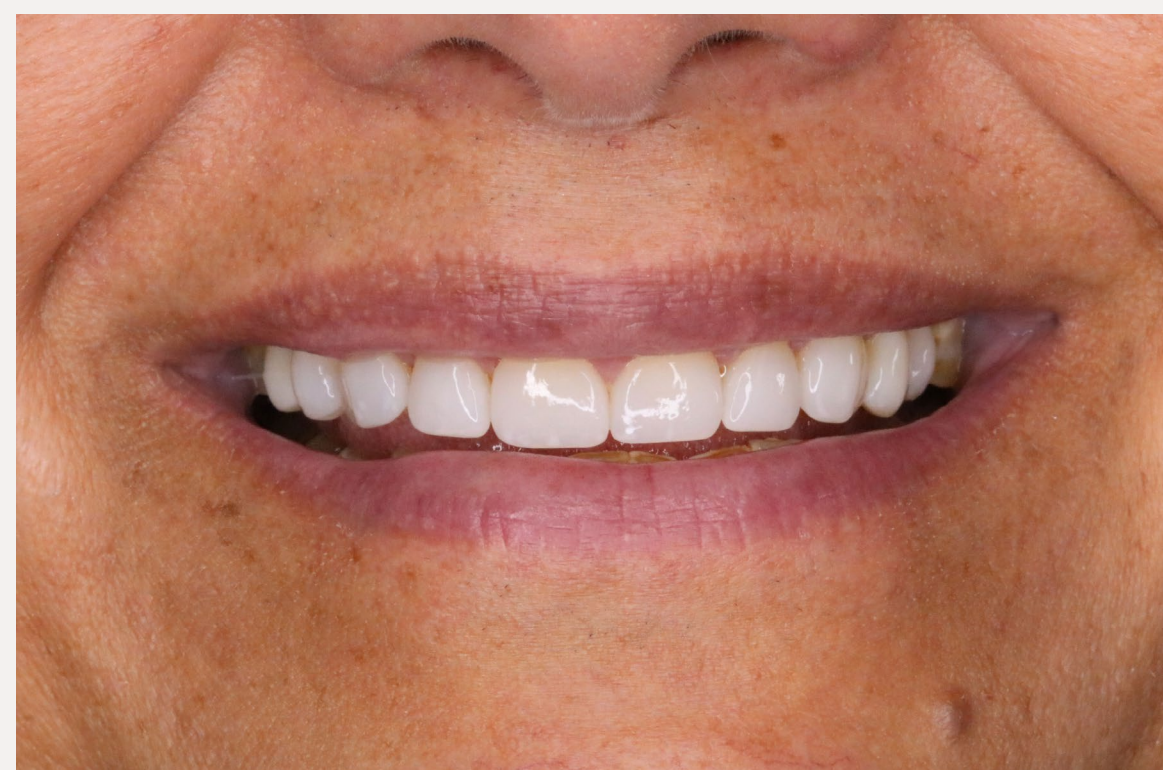The patient wanted a beautiful smile. As teeth 15 to 25 are all visible, the decision was made to use a highly esthetic ceramic for all 10 of them. Due to the extensive consultation and the implementation with a mock-up, the restoration was carried out in two sessions with CEREC. The patient was very satisfied with the result.

[Read more](#)

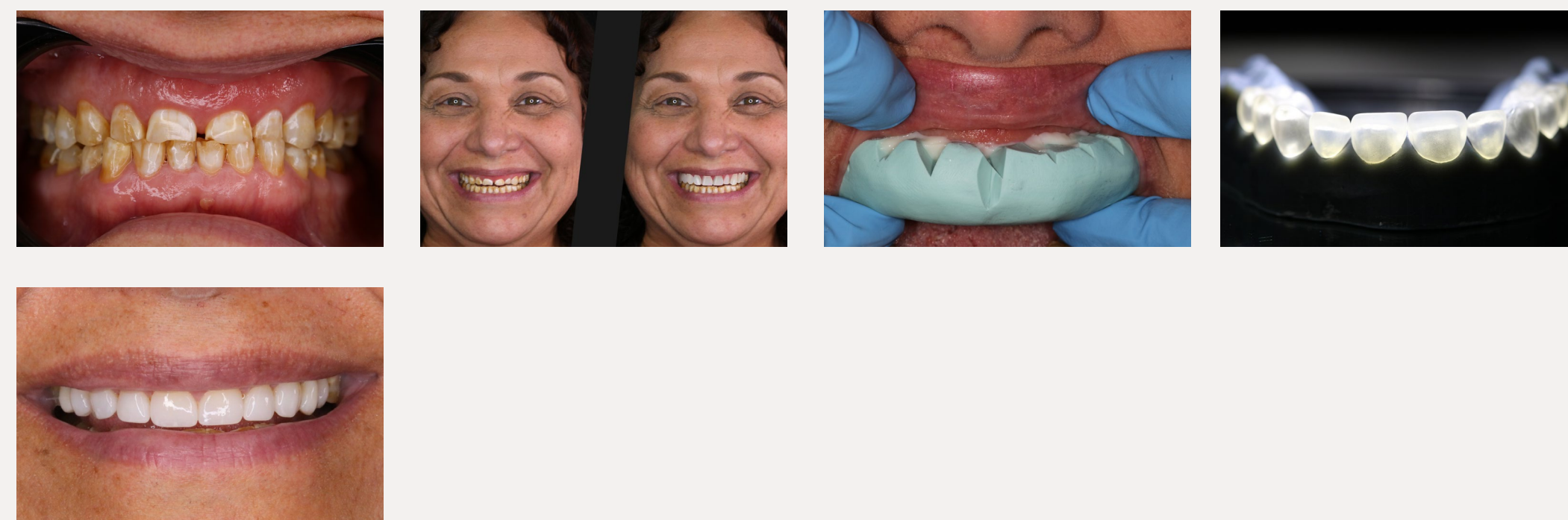
Before



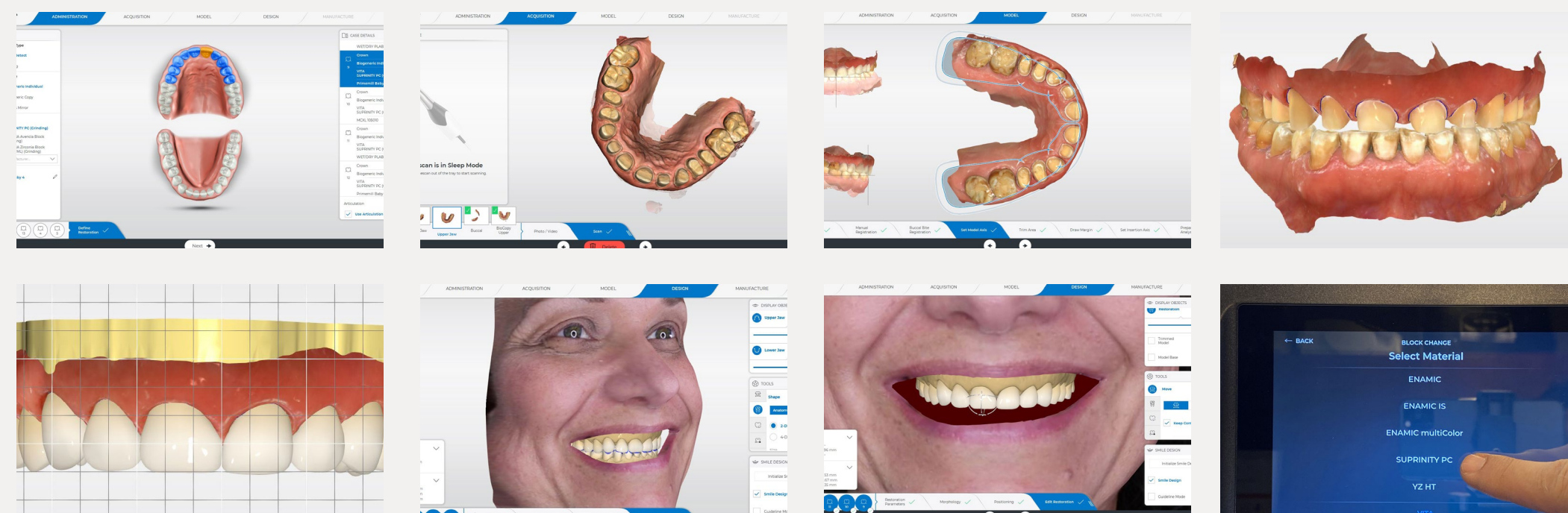
After



Clinical Images +



Workflow Images +

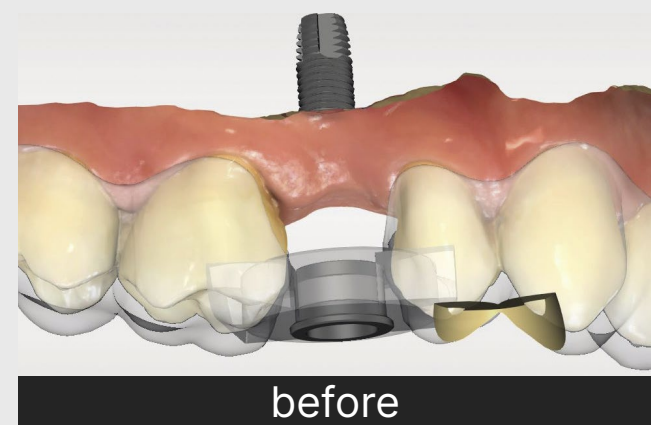




Implant

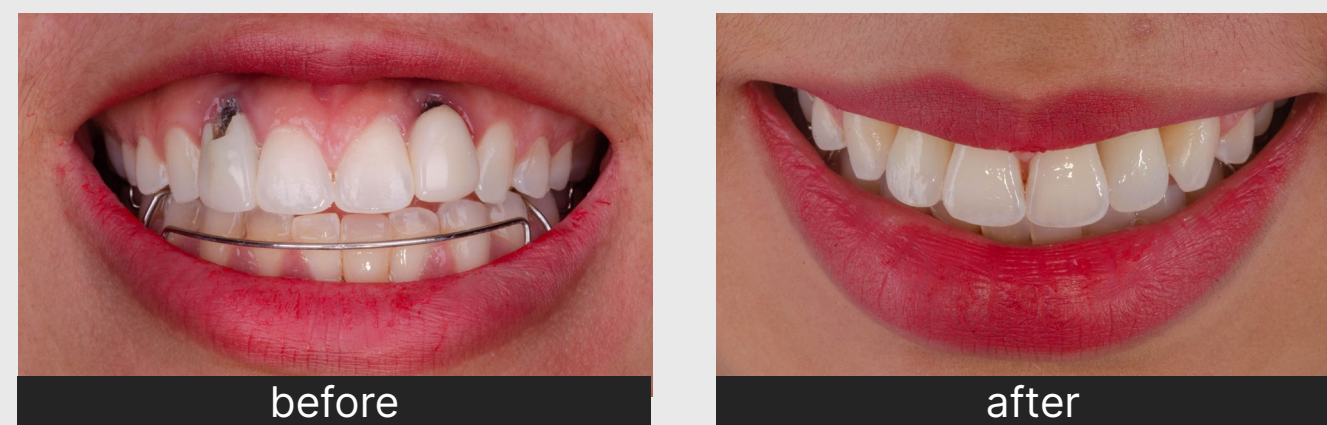1

Second upper premolar
Astra Tech and IPS e.max



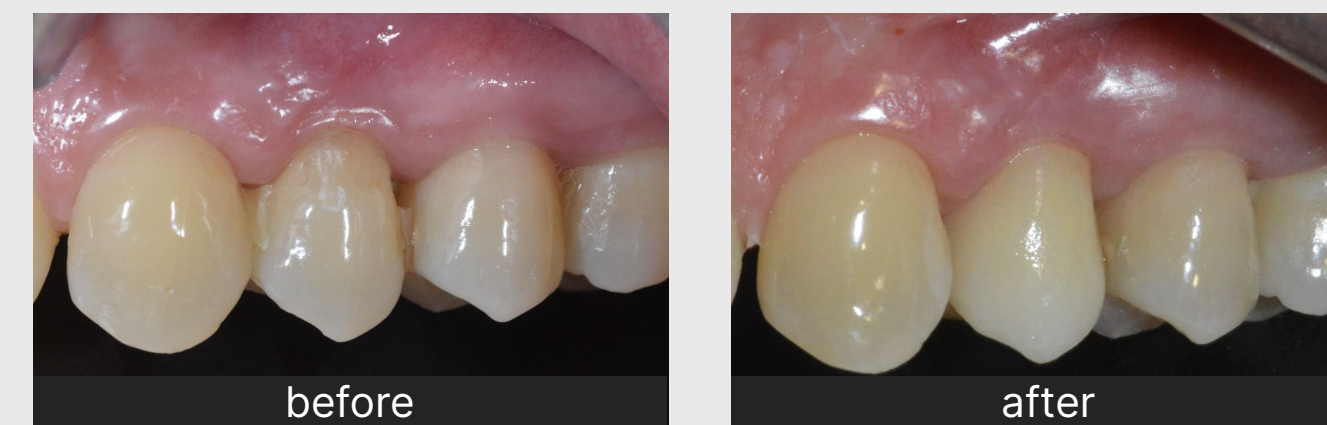2

Upper lateral incisors
Ankylos and Celtra Duo



3

First upper premolar
Ankylos and IPS e.max CAD





Astra Tech implant placement and an IPS e.max CAD single crown – Second upper premolar



Dr. Andreas Bindl
Zurich, Switzerland

Case Description

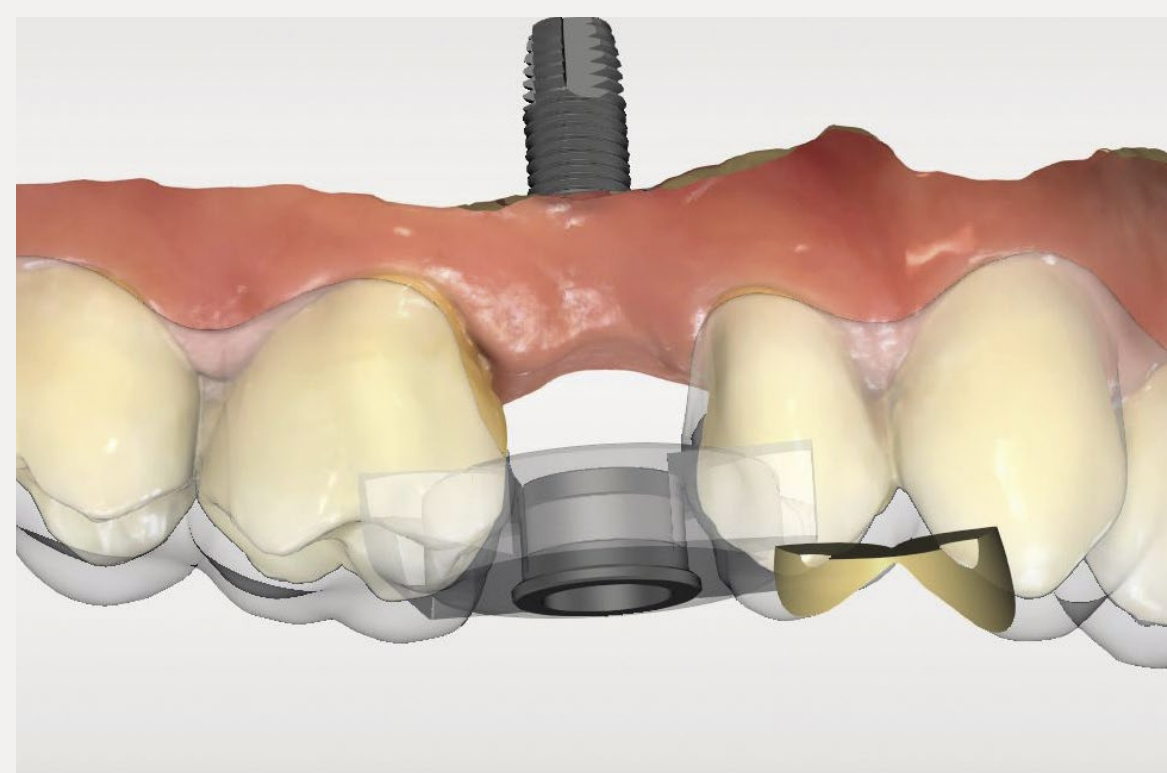
A 36-year-old patient came to our practice four months after the extraction of tooth 15 due to a longitudinal fracture. He wanted to close the resulting tooth gap. The patient was healthy and with good oral hygiene. Treatment with an implant or a bridge was considered...

Discussion

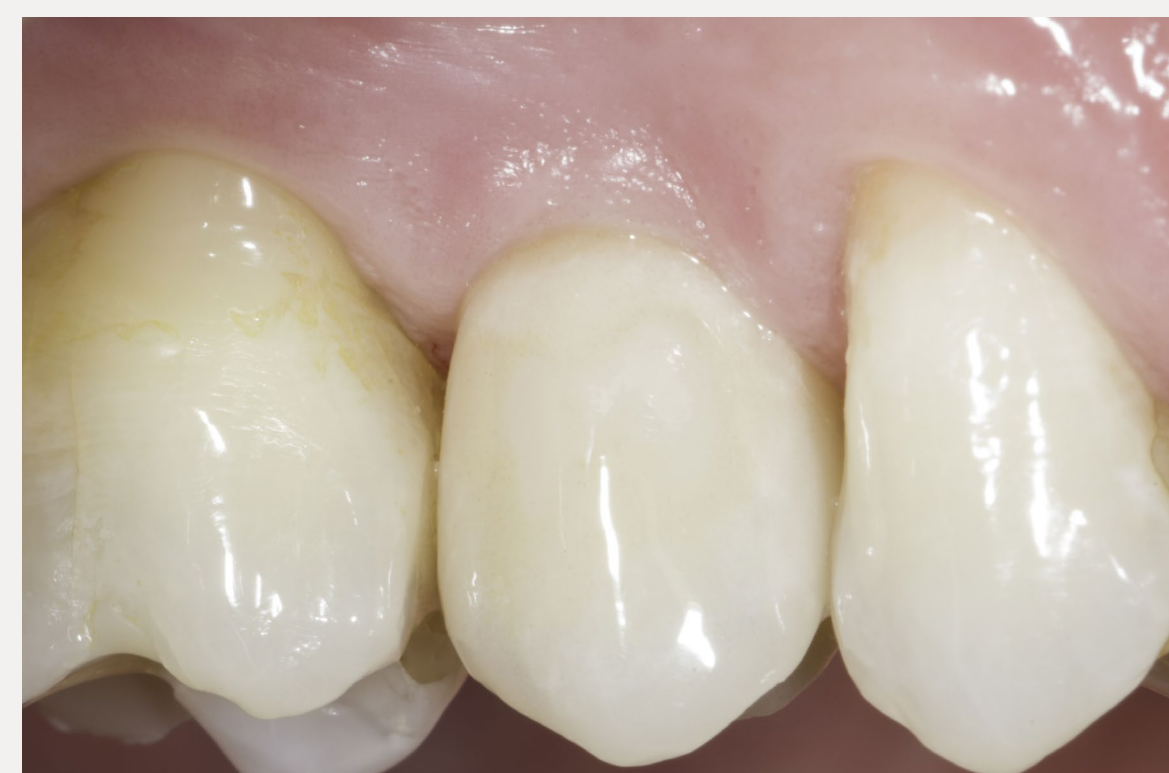The implant and screw-retained crown made of a high-quality glass-ceramic material provided the patient with a highly esthetic and long-term stable restoration without the need to prepare healthy natural tooth enamel. The guided procedure with CEREC Guide 3 provided a high level of safety during preparation...

[Read more](#)

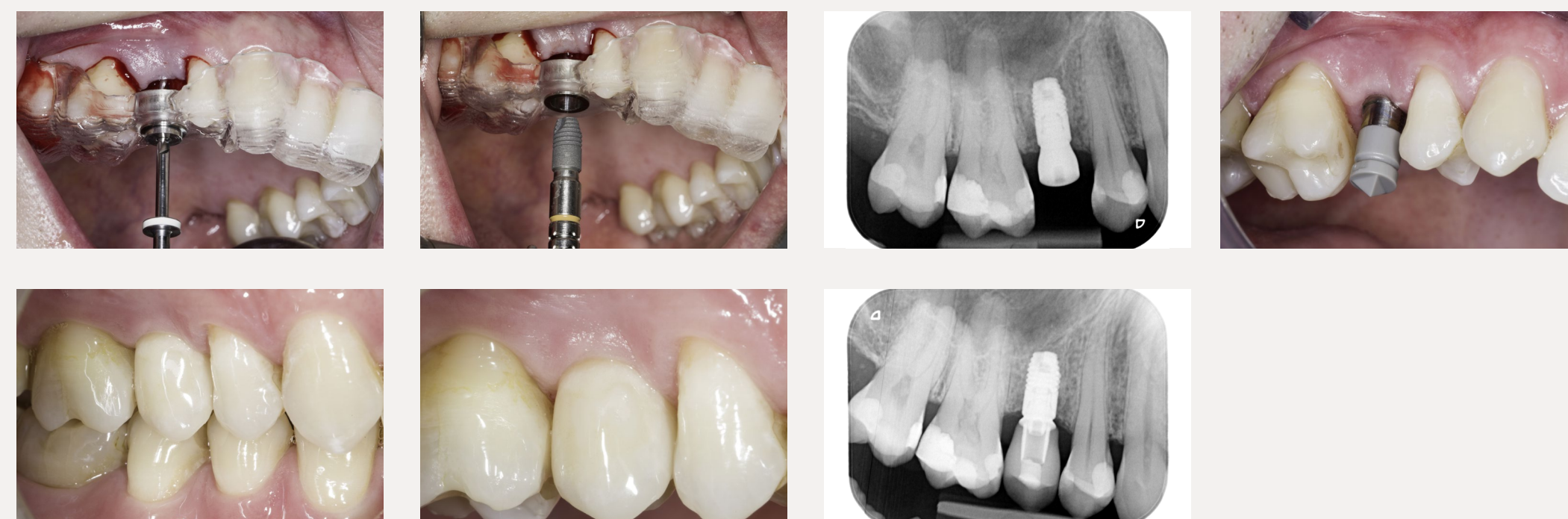Before



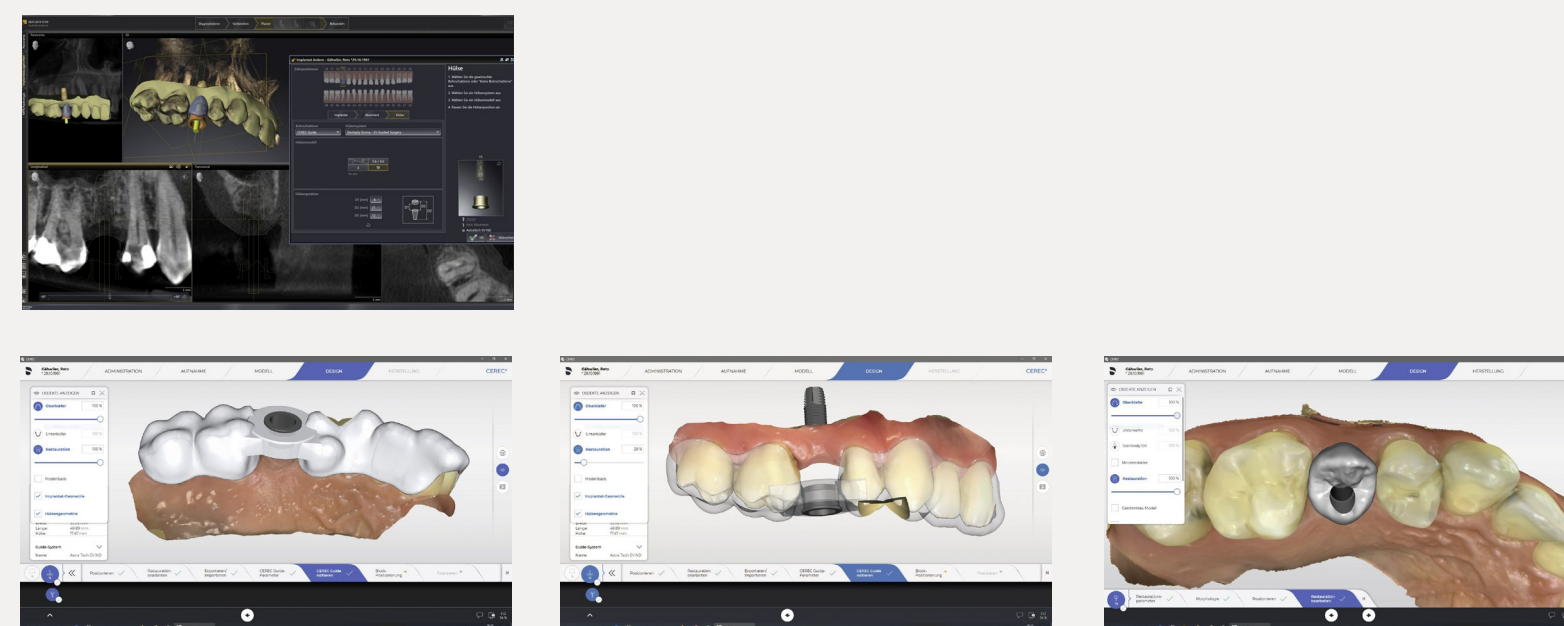
After



Clinical Images +



Workflow Images +





Ankylos implant placement and two Celtra Duo crowns – Upper lateral incisors in 180 minutes



Dr. Fernando Peixoto Soares
São Paulo, Brazil

Case Description

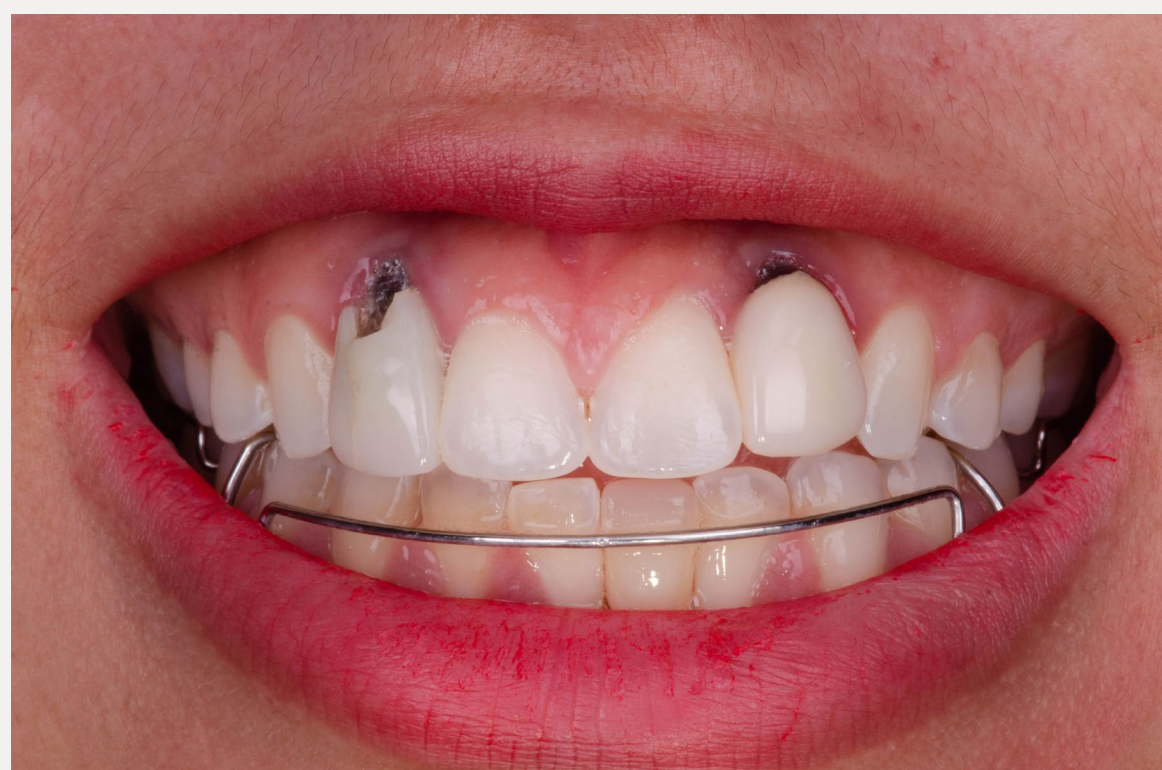A 22-year-old female patient came to my practice. Her medical history revealed that teeth 12 and 22 were missing due to dental agenesis and had been replaced by implants. This solution did not please the patient at all. She hid her smile and felt inhibited around company...

Discussion

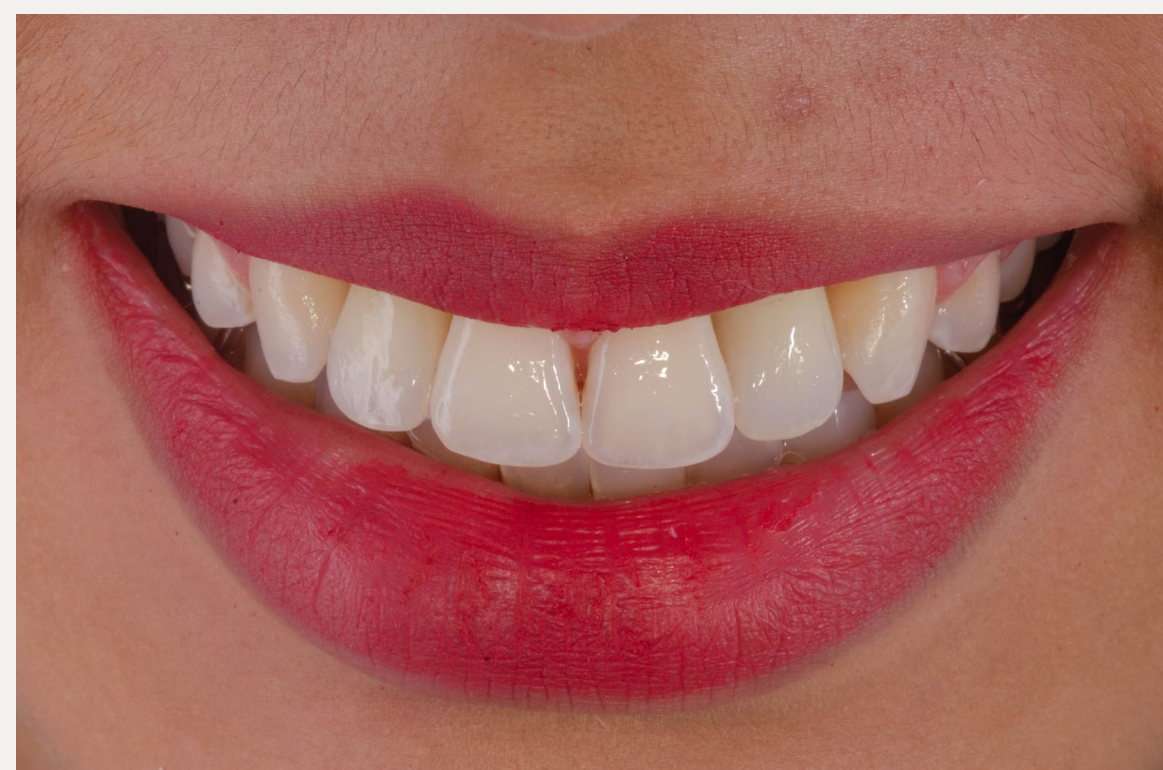For an adequate result from a functional and esthetic point of view, the removal of both previous implants was unavoidable. The treatment options were an orthodontic gap closure, a restoration with bridges, or two single-tooth restorations with implants and chairside-fabricated crowns, the latter of which...

Read more

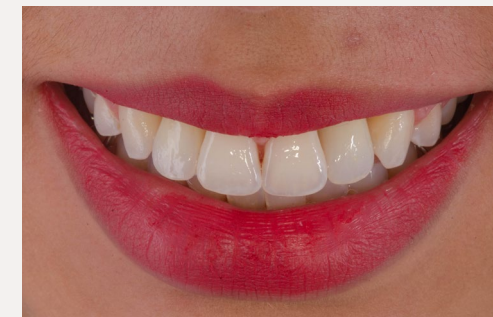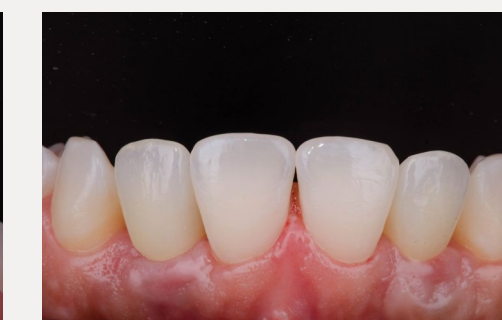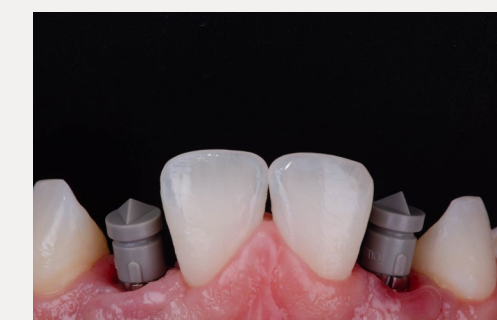
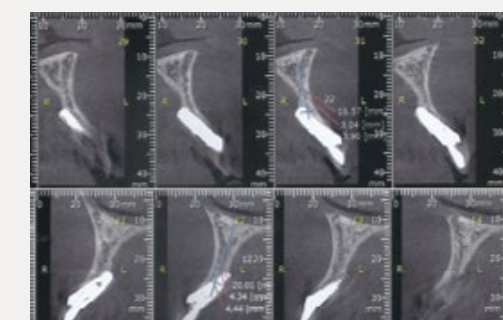
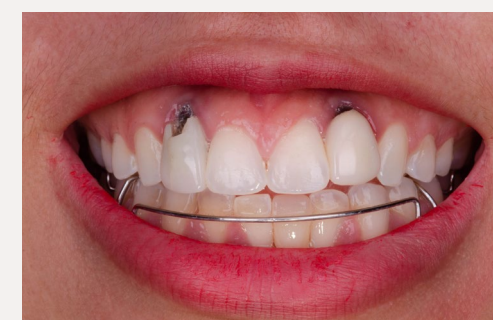Before



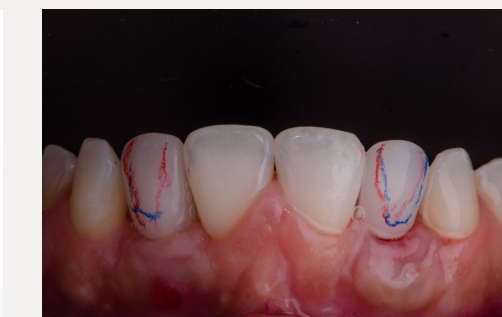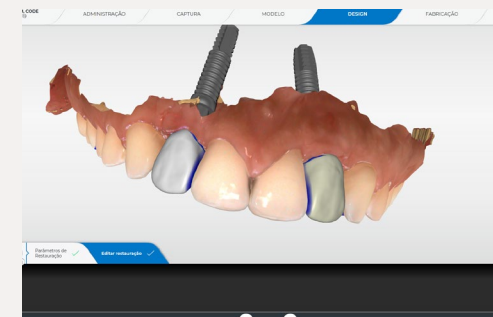
After



Clinical Images +



Workflow Images +





Ankylos implant placement and IPS e.max CAD single crown – First upper premolar in 90 minutes



Dr. Carlos Repullo
Sevilla, Spain

Case Description

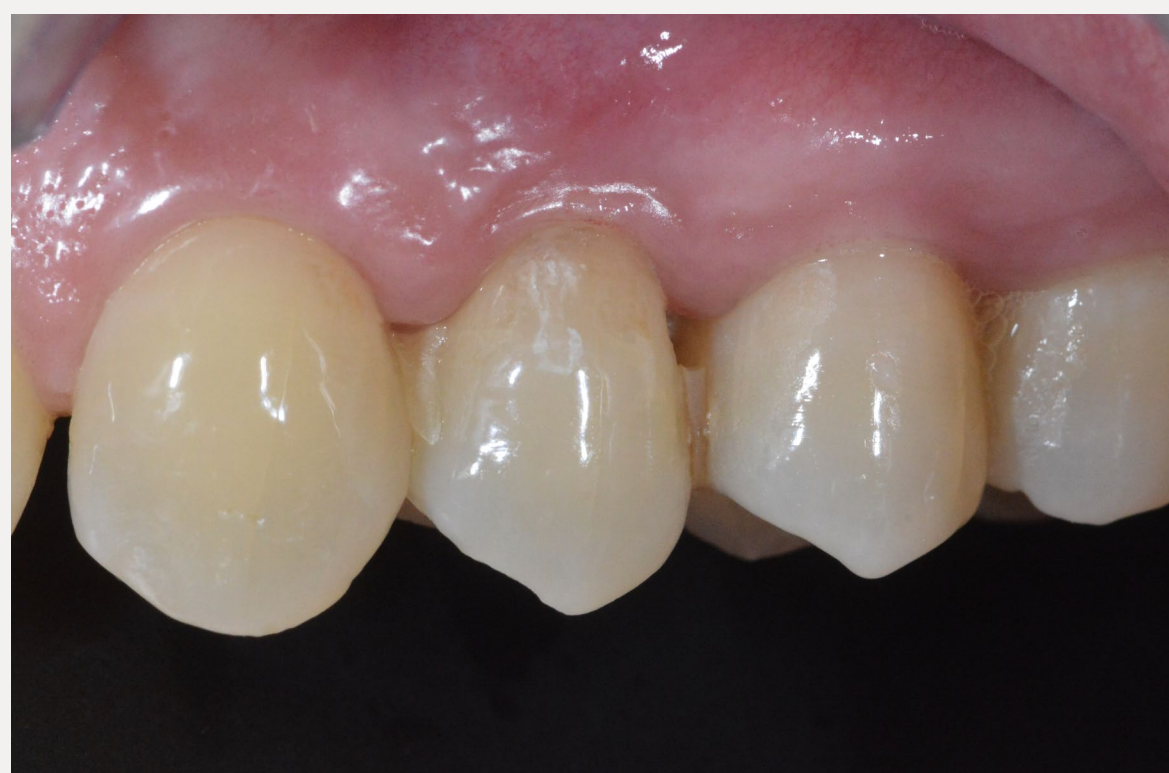A 56-year-old female patient came to my practice with pain and some loosening of tooth 24. After an initial examination, a CBCT scan was performed with Orthophos SL, which determined that a horizontal root fracture and a periapical infection were the cause of the problems...

Discussion

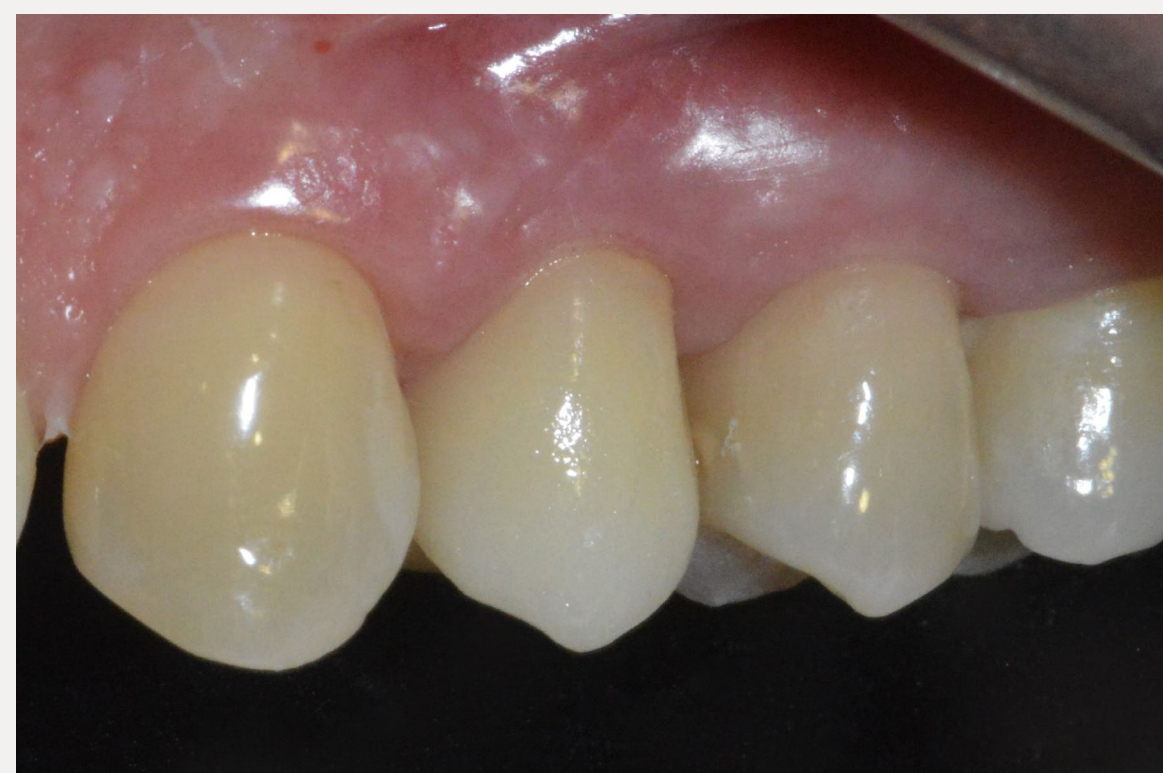A possible alternative would have been a conservative treatment approach with root canal treatment and stabilization of tooth fragments. However, the patient rejected this due to the relatively high risk of failure as well as a previous negative experience...

Read more

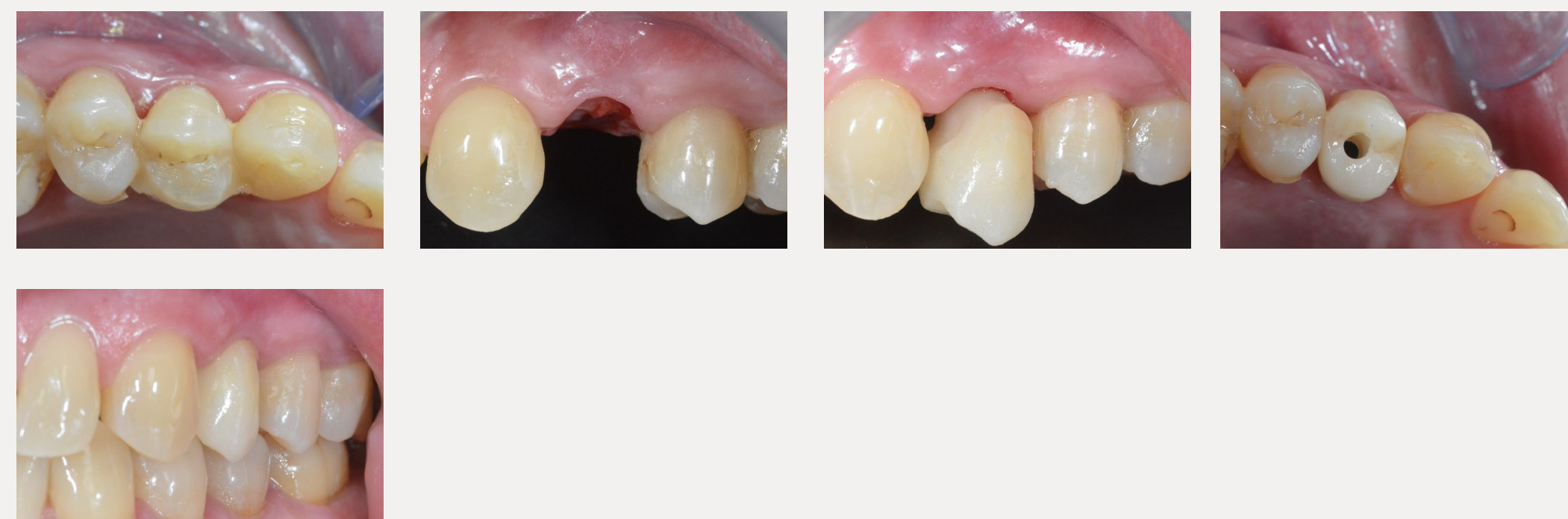Before



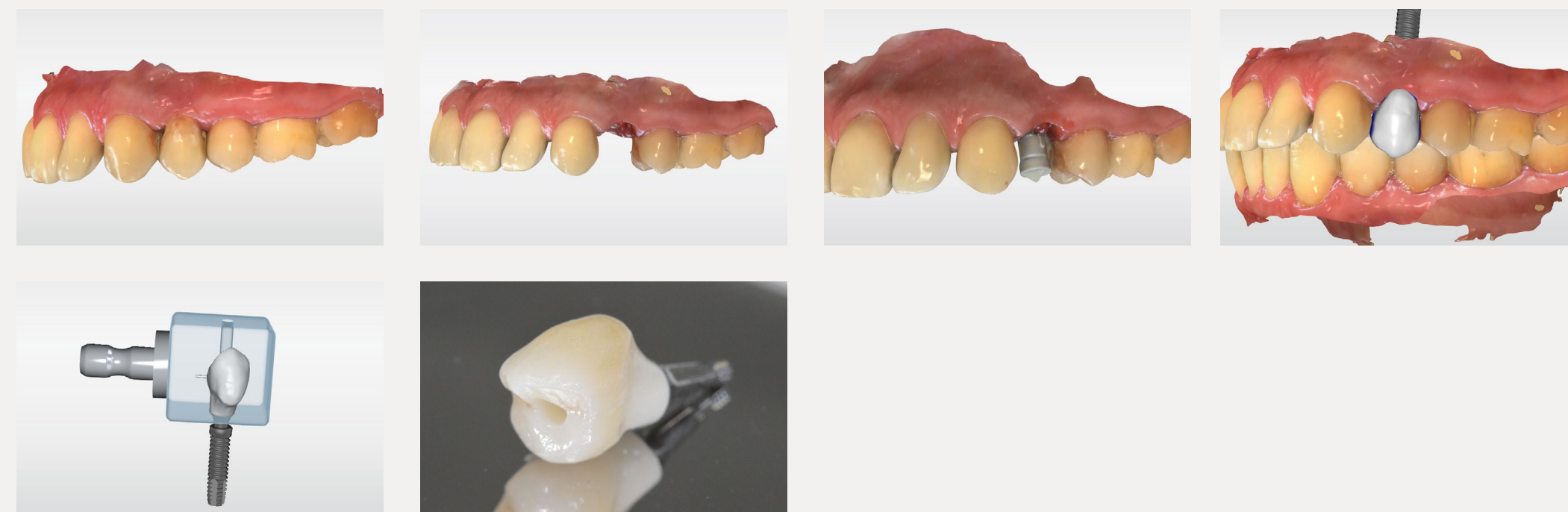After



Clinical Images



Workflow Images





CEREC Primescan

Accuracy. Usability. Speed.

An excellent choice for brilliant results: CEREC Primescan is your optimal starting point into digital dentistry. No matter how you would like to design your workflows, CEREC Primescan is the enabler for efficient digital workflows – both chairside in your practice and with your preferred partners.

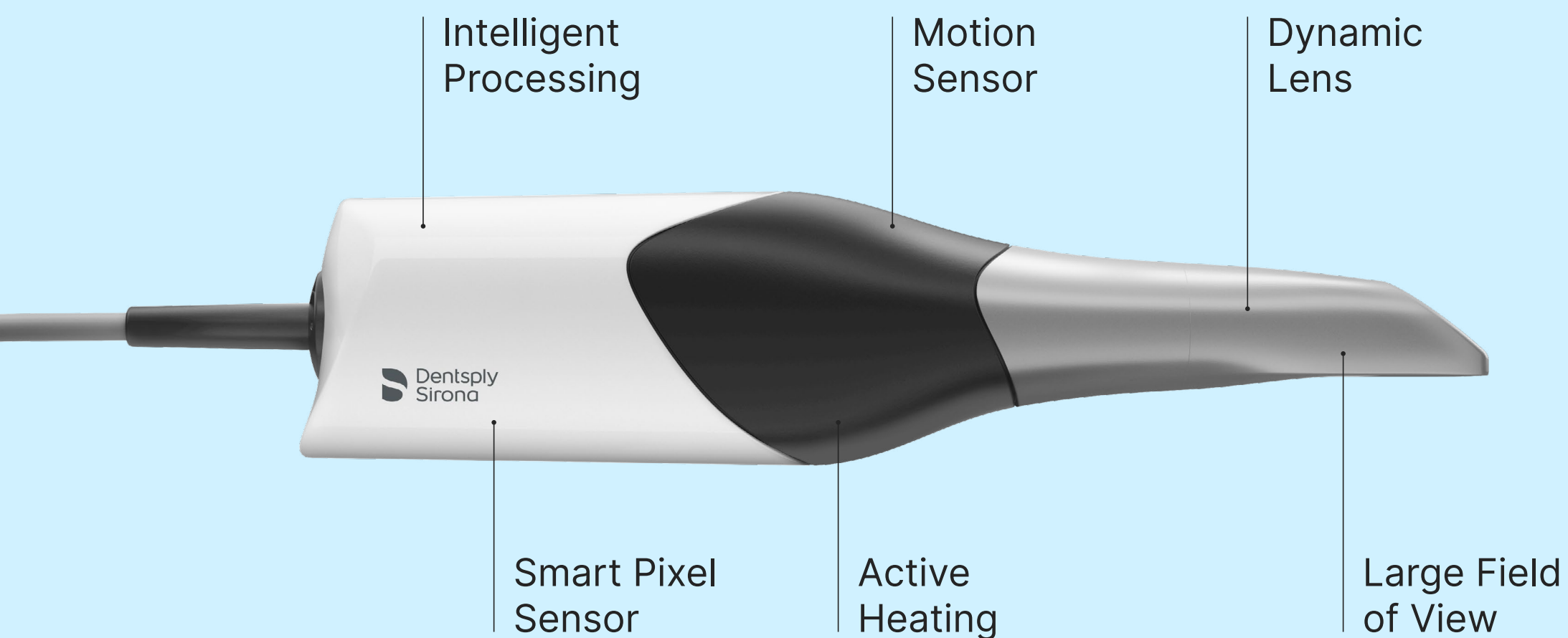
[Learn more >](#)

CEREC Primemill

Quality. Convenience. Speed. Versatility.

The grinding and milling unit utilizes state-of-the-art technology and CAM strategies to produce excellent chairside restorations more easily, with a high level of usability, precision and speed. A modern setup for achieving predictable results with enhanced quality chairside experience – for both the user and patient.

[Learn more >](#)





CEREC SpeedFire

Dental combination furnace for chairside digital dentistry

CEREC SpeedFire is a compact, fast sintering and glazing furnace enabling quick turnaround times for treatments in one single visit. CEREC SpeedFire can process a great variety of different materials, from Dentsply Sirona block materials to partner materials. All sintering and glazing programs have been tested and validated by the corresponding material partner for high esthetics and durable restorations.

[Learn more >](#)

Induction technology

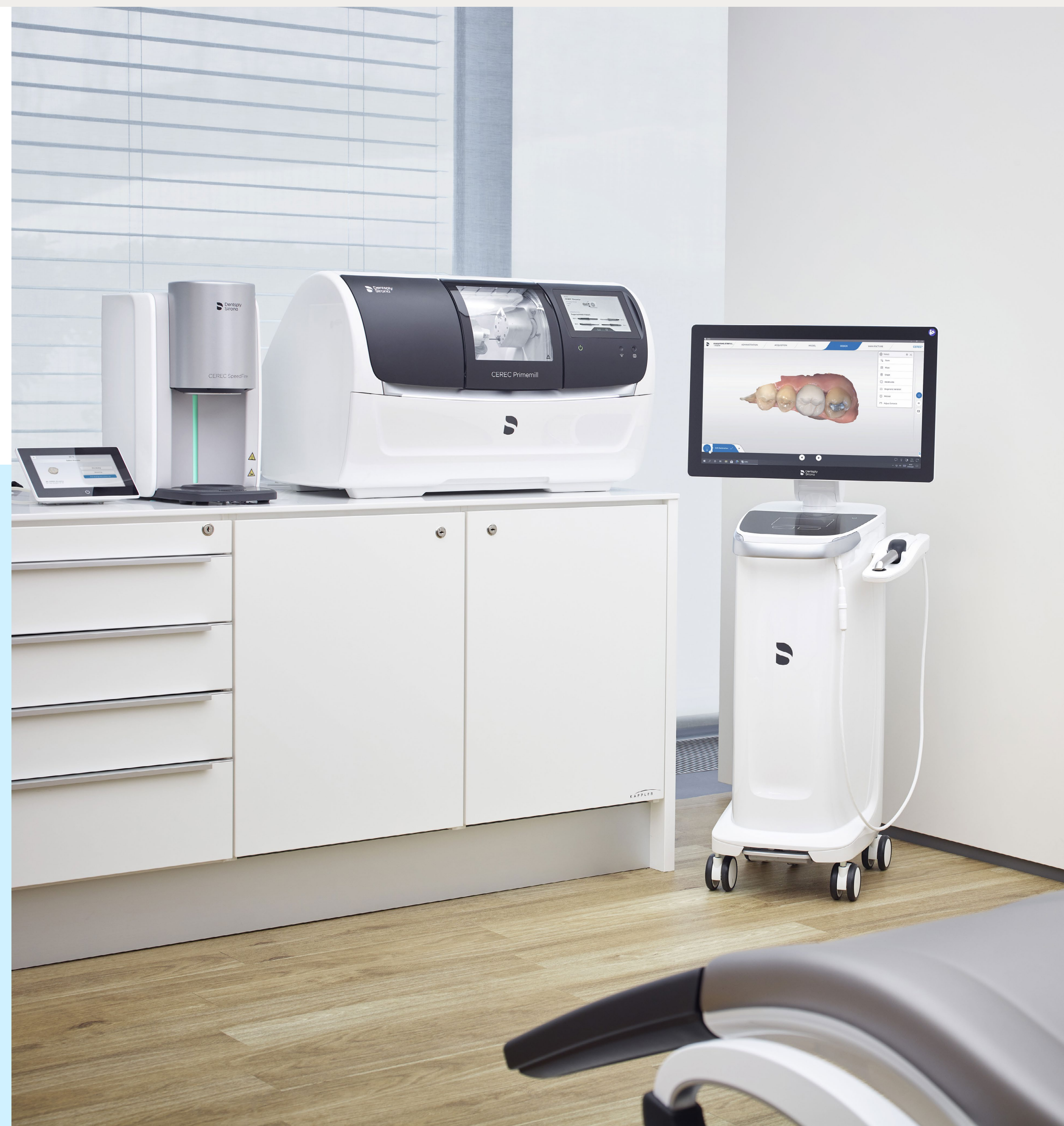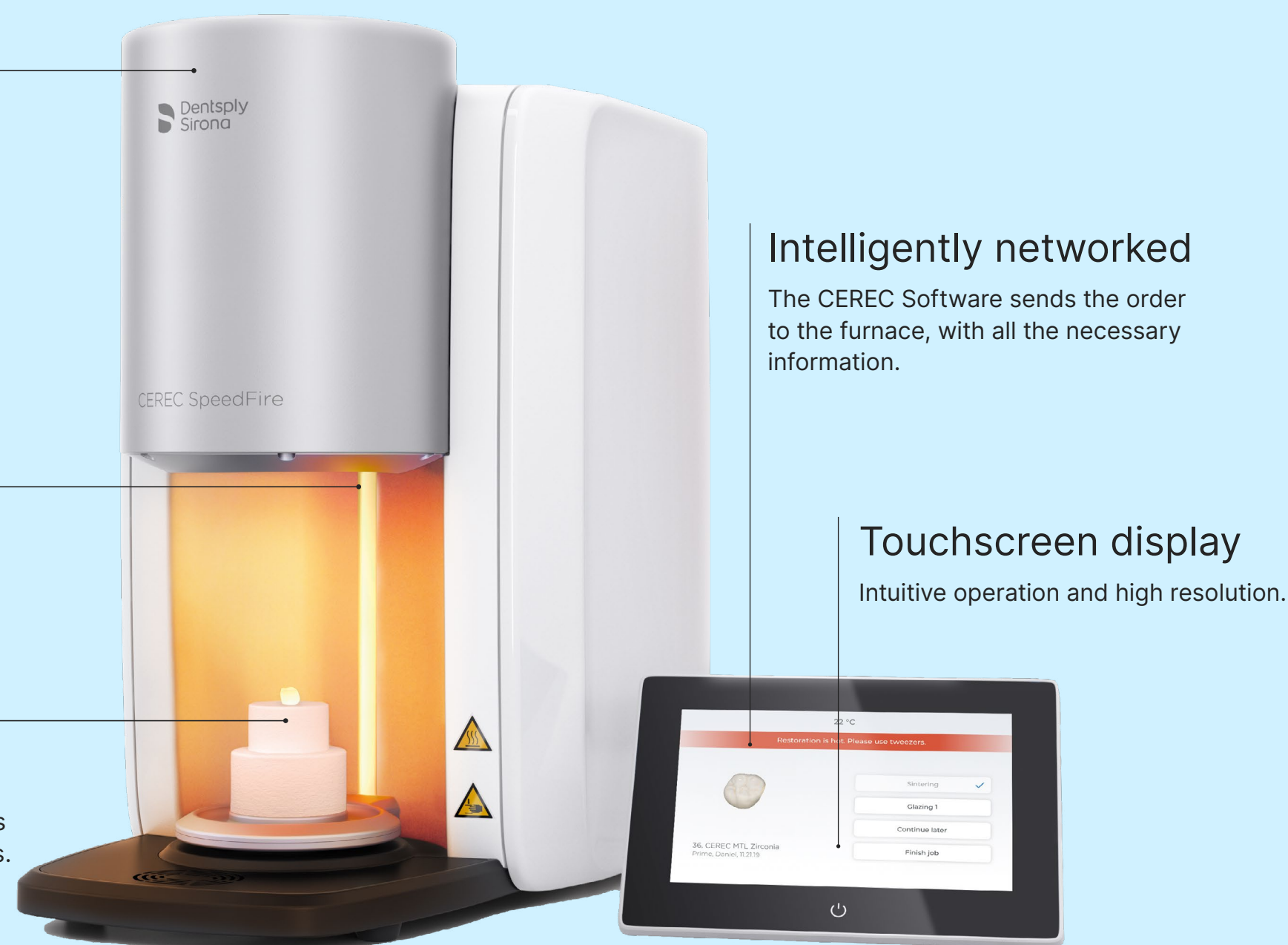Unparalleled short sintering and firing times.

LED status display

Differing colors indicate the current processing status.

Chamber

Space for up to three single crowns or for bridges with up to three units.





Introduction

Single posteriors

Anteriors

Implants

Product Information

Dentsply Sirona

Sirona Dental Systems GmbH
Fabrikstraße 31, 64625 Bensheim, Deutschland
dentsplysirona.com

Subject to technical changes and errors within the text, Order No. M43-C350-01-7600, 0623.

Procedural Solutions

Preventive
Restorative
Orthodontics
Endodontics
Implants
Prosthetics

Enabling Technologies

CAD/CAM
Imaging
Treatment Centers
Instruments

THE DENTAL
SOLUTIONS
COMPANY™





A CEREC Tessera crown – First upper molar in 90 minutes



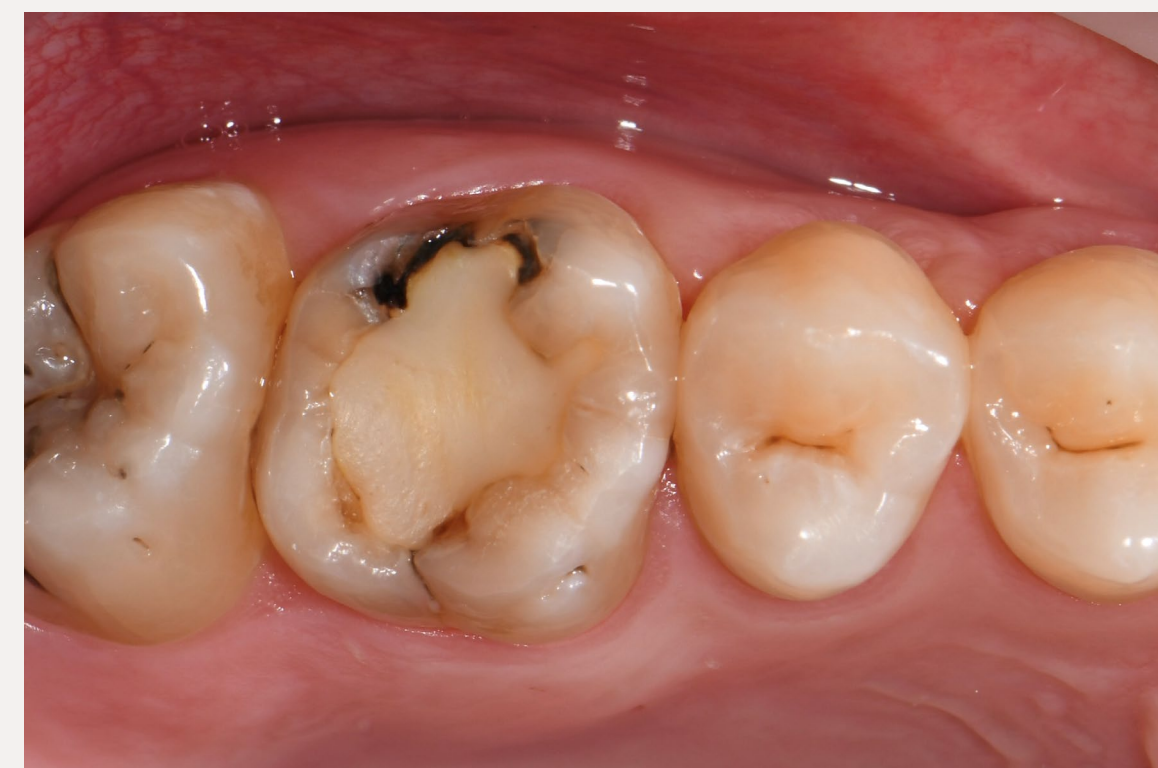Dr. Shivi Gupta
San Diego, USA

Case Description

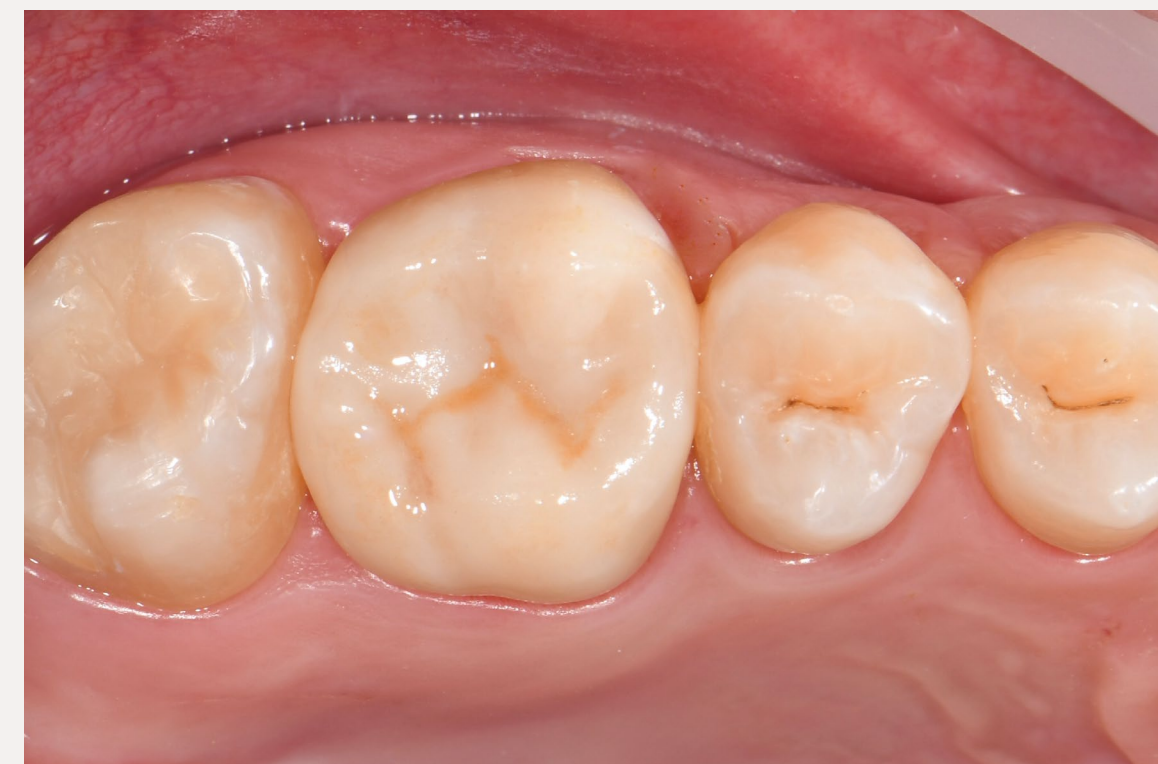A 49-year-old male patient visited my practice with pain in the first upper molar, which he described as occurring when he bit down. The tooth had been restored with an extensive yet insufficient composite filling that already showed visible fractures. The clinical examination also revealed a carious defect. A treatment plan was drawn up for a full-surface restoration. Because of the bite pain, this needed a high-strength material. As the tooth was visible during speech, the material also had to meet high esthetic standards. CEREC Tessera from Dentsply Sirona was selected in shade HT A2 – a material that met all the requirements in equal measure. CEREC Tessera is an advanced lithium disilicate ceramic for the CEREC workflow, offering a very good combination of strength and esthetics. After tooth preparation, the intraoral scan was performed with CEREC Primescan. The crown was then designed in the CEREC Software. CEREC Primemill was used for manufacturing: the CEREC Tessera block was placed in the milling unit and the crown was produced using the pre-touch mode. The result was impressive with its excellent marginal stability. In the following steps, the crown was first pre-polished, glazed and then customized with stain. The buccal stain consisted of a mixture of the Olive and Sunset shades (Universal Stains, Dentsply Sirona), while the Universal Stains Mahogany shade was best suited for the occlusal stain. The desired gloss was achieved by applying two coats of spray glaze (DS Universal Spray Glaze Fluo, Dentsply Sirona), one from the buccal side and one from the lingual side. After air drying, the crown was fired in CEREC SpeedFire. This process took only four and a half minutes. A post-polish concluded the manufacturing process. Prior to applying the crown, the enamel of the prepared tooth was selectively etched. The translucent Calibra Ceram cement from Dentsply Sirona enabled a stable final restoration. The patient was extremely positive about the short treatment time of only 90 minutes in total. He was interested in the digital technology used, followed the process with excitement, and was very satisfied with the esthetic result.

Discussion

The decisive factor for the restoration of the first upper molar with a crown was the patient's pain when biting down. Replacing the filling would have been only a temporary solution. The crown solves the problem from a functional point of view and offers excellent esthetics simultaneously thanks to the new material. Restoration in a single visit was possible due to the digital CEREC workflow, the efficient fabrication of the restoration with CEREC Primemill, and the glaze firing in CEREC SpeedFire, which took only a few minutes.



Before:
First upper molar had been restored with an extensive yet insufficient composite filling that already showed visible fractures.



After:
Chairside-fabricated restoration made from an advanced lithium disilicate ceramic, CEREC Tessera.



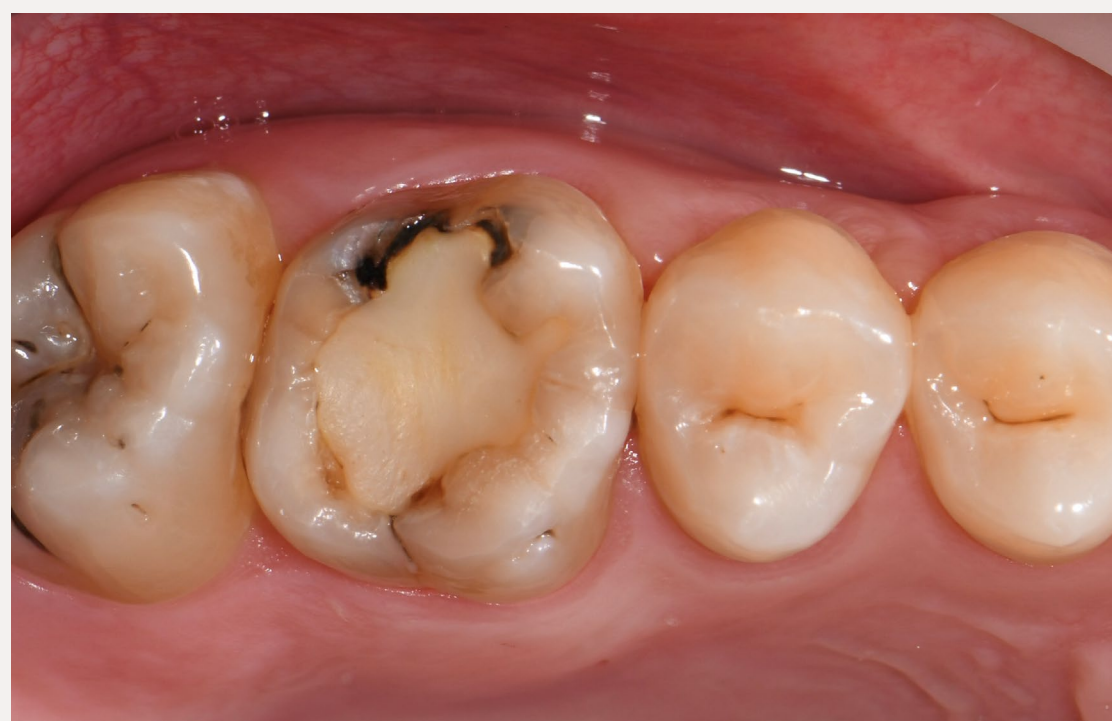

A CEREC Tessera crown – First upper molar in 90 minutes

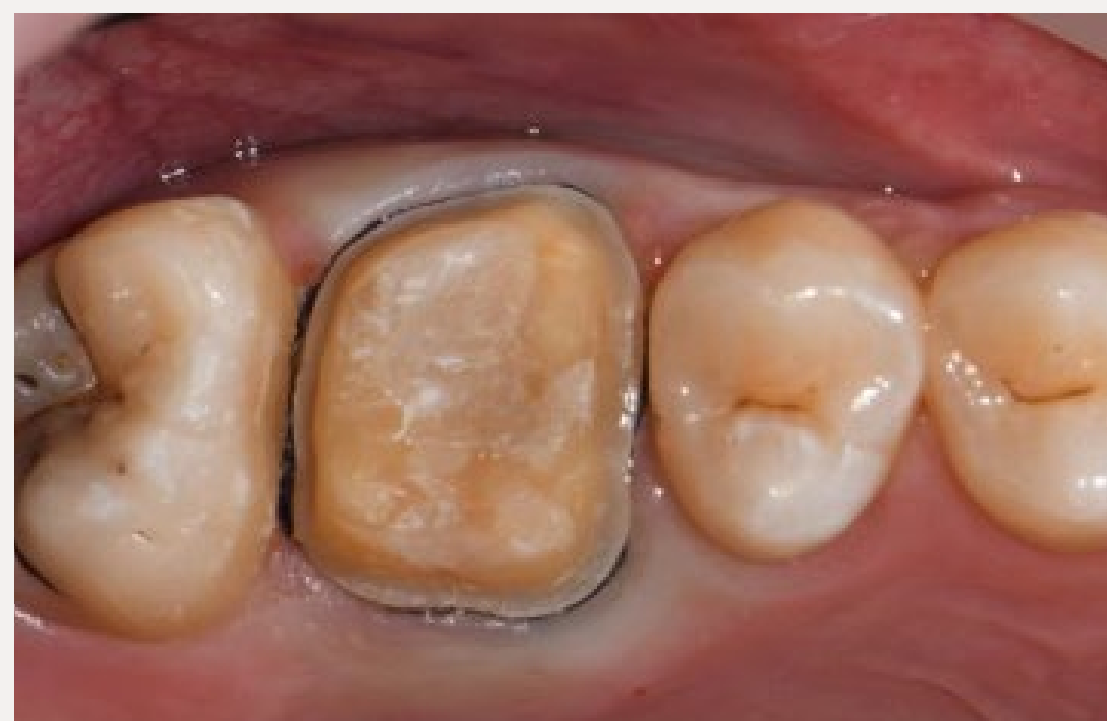

Dr. Shivi Gupta
San Diego, USA

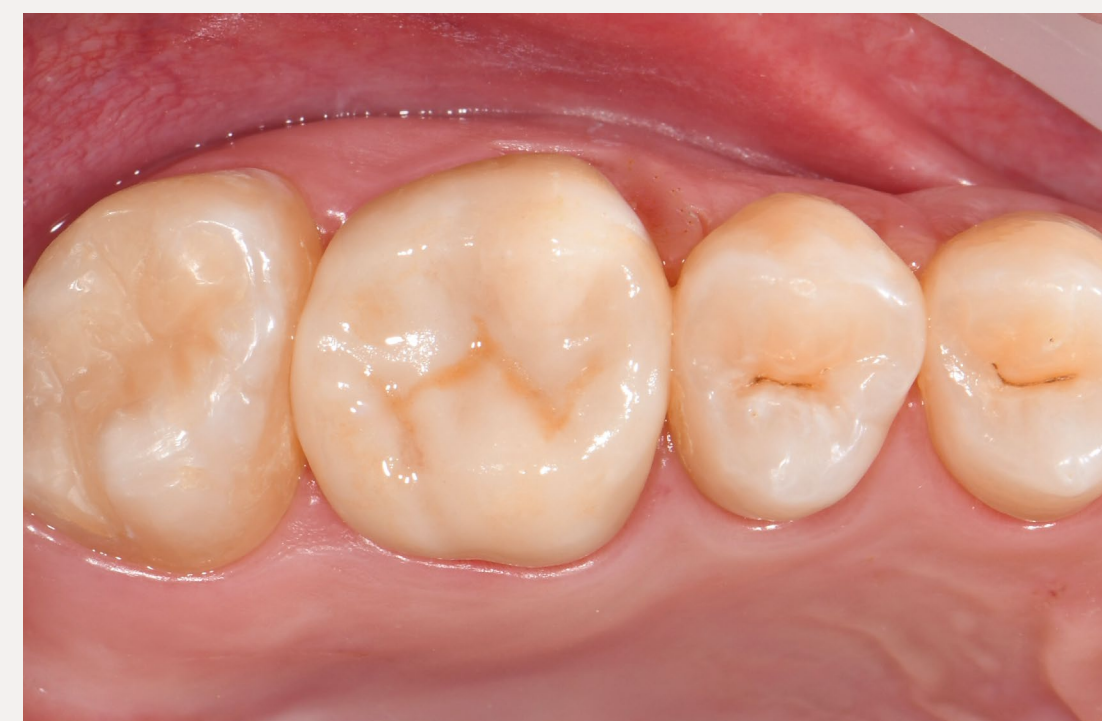Clinical Images



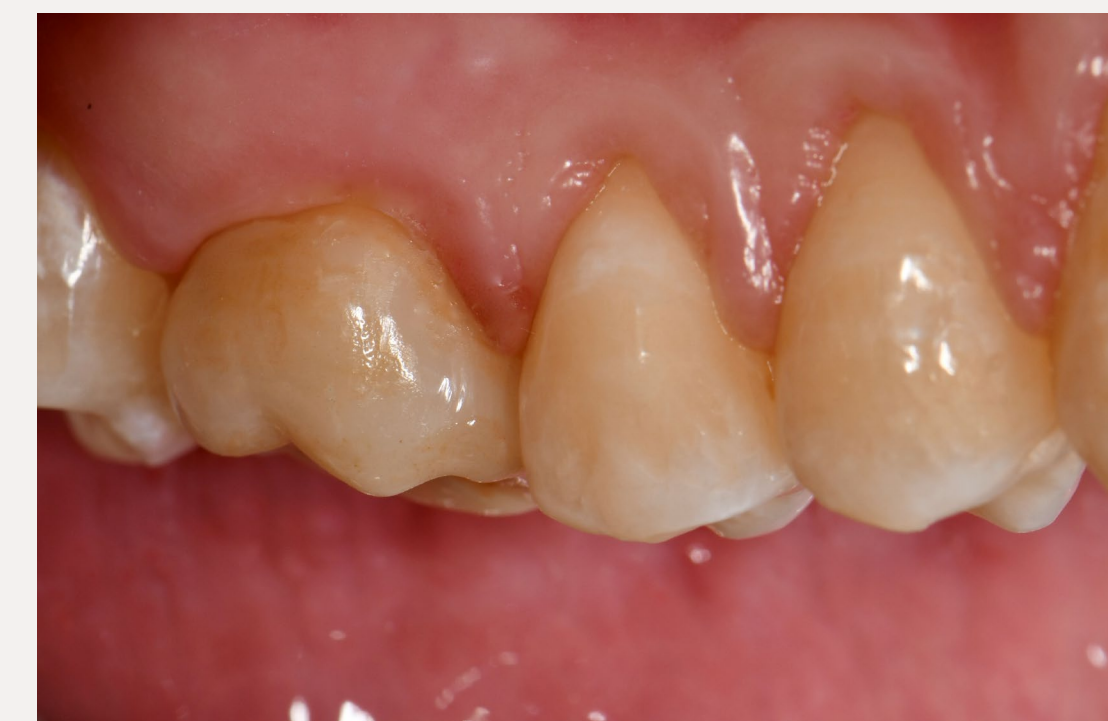Pre-op with decay and composite filling breaking down.



Crown preparation.



Final crown – occlusal.



Final crown – buccal.

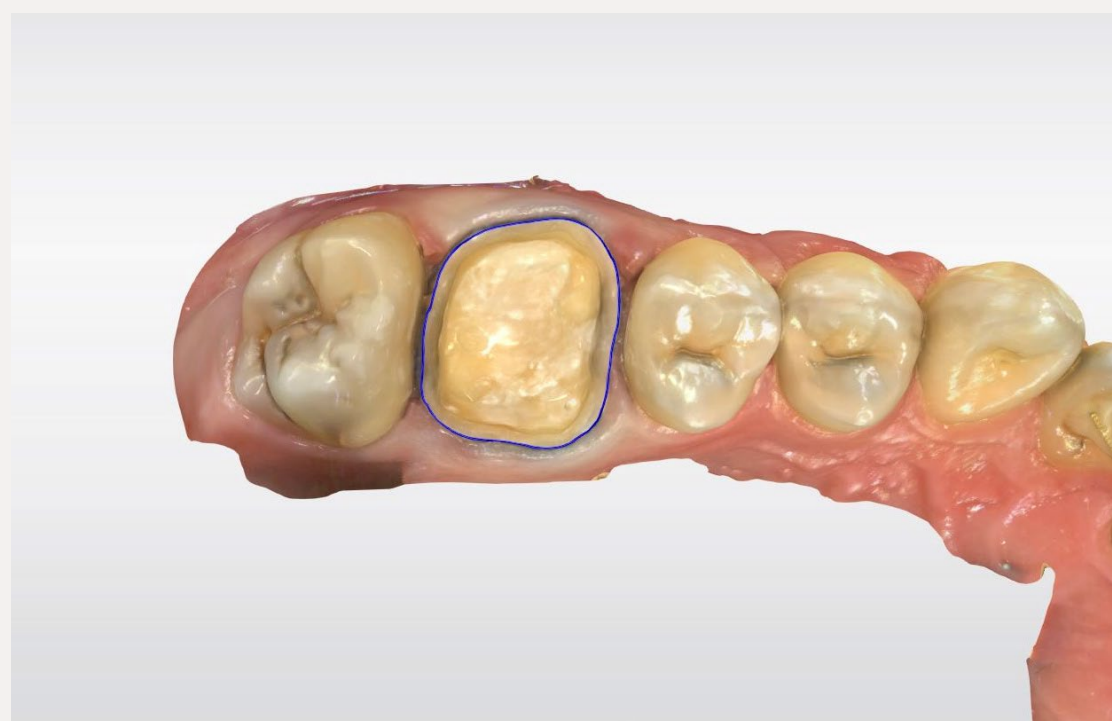

A CEREC Tessera crown – First upper molar in 90 minutes

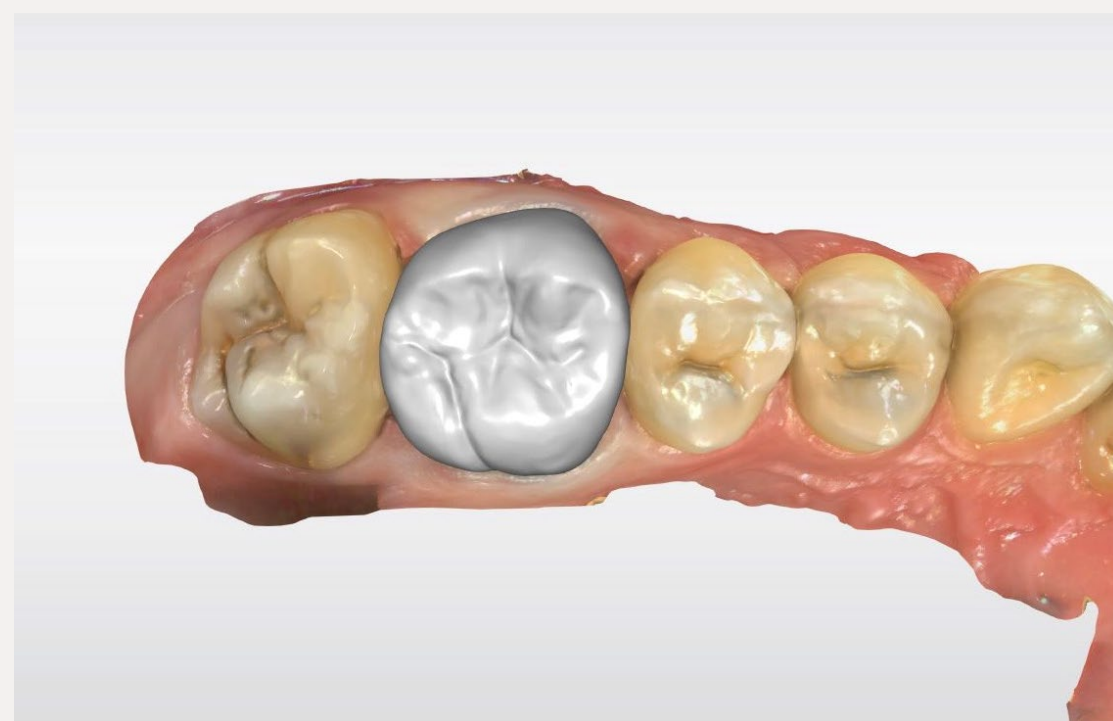


Dr. Shivi Gupta
San Diego, USA

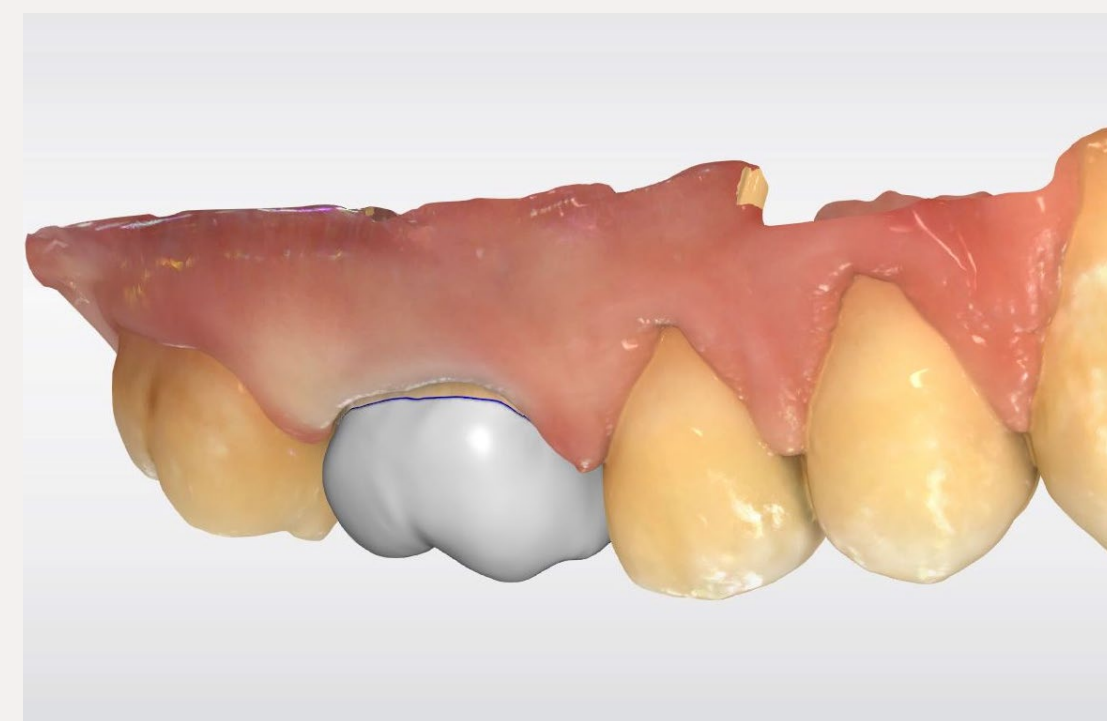
Workflow Images



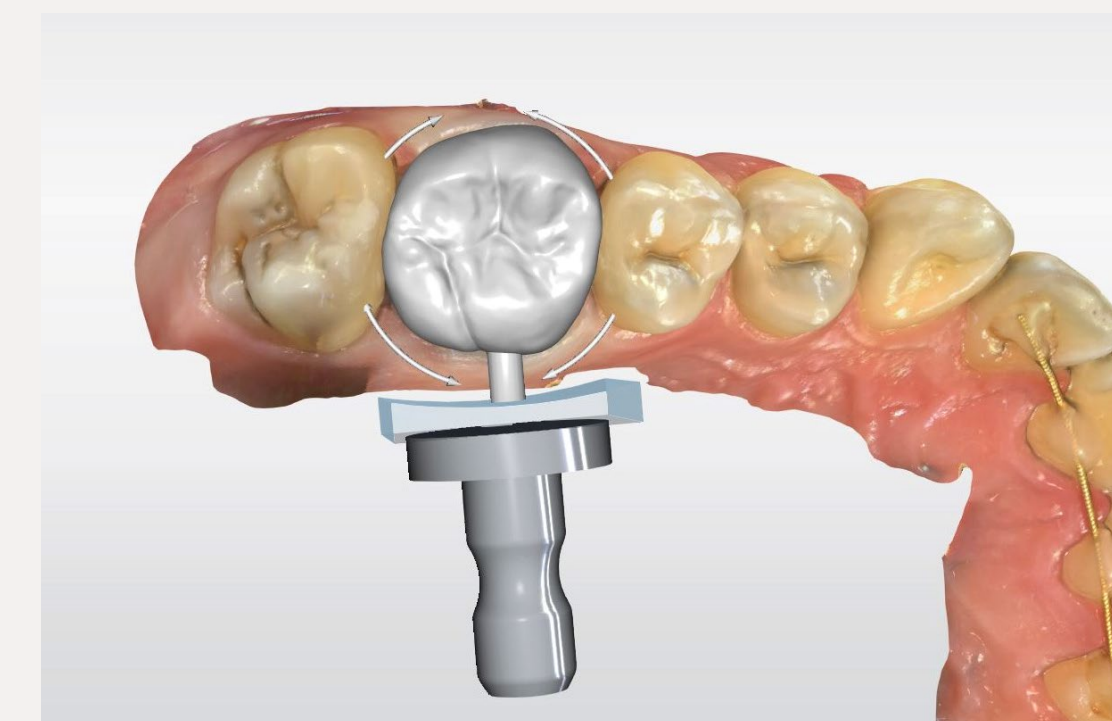
Crown margination.



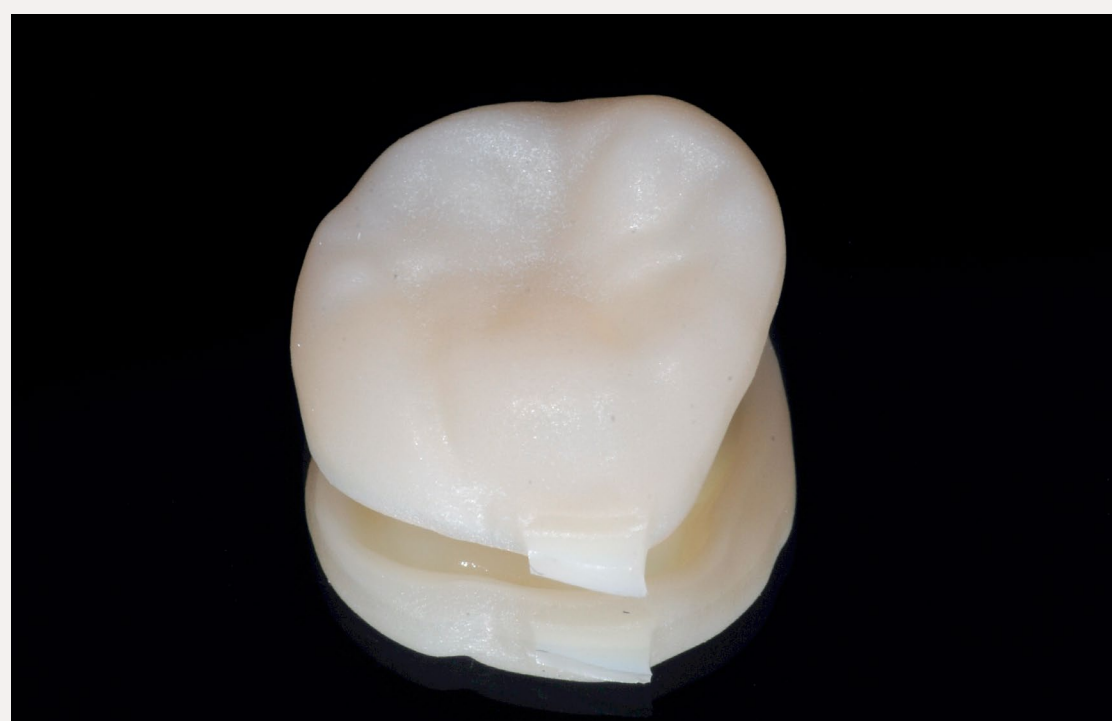
Final restoration – occlusal.



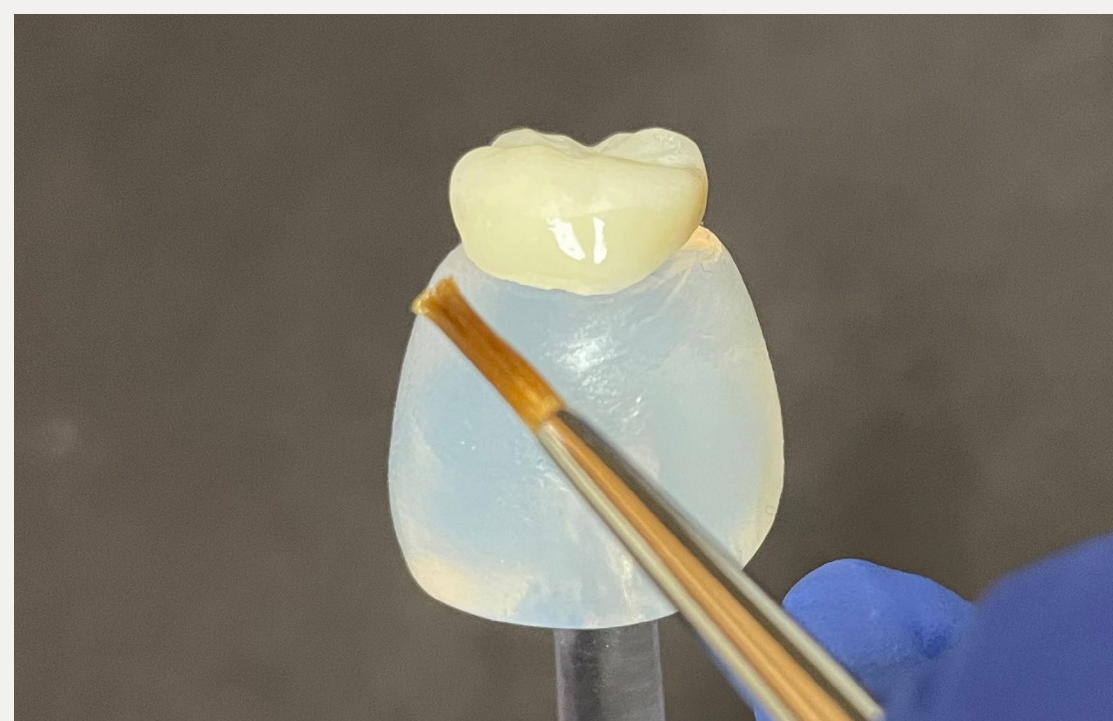Final restoration – buccal.



Manufacture preview of final crown.



Occlusal surface of milled crown. The sprue was removed, and it was pre-polished next.



For the glaze and optional stain step, the crown is placed on a moldable silicone. Buccal stain is added with a brush. A mixture of two shades – Olive and Sunset (Universal Stains by Dentsply Sirona) – was used.



The crown is placed on top of the CEREC SpeedFire honeycomb tray with a firing pad. It must be centered on the pad. The construction is then placed in CEREC SpeedFire.



A CEREC Tessera inlay – First upper molar in 100 minutes



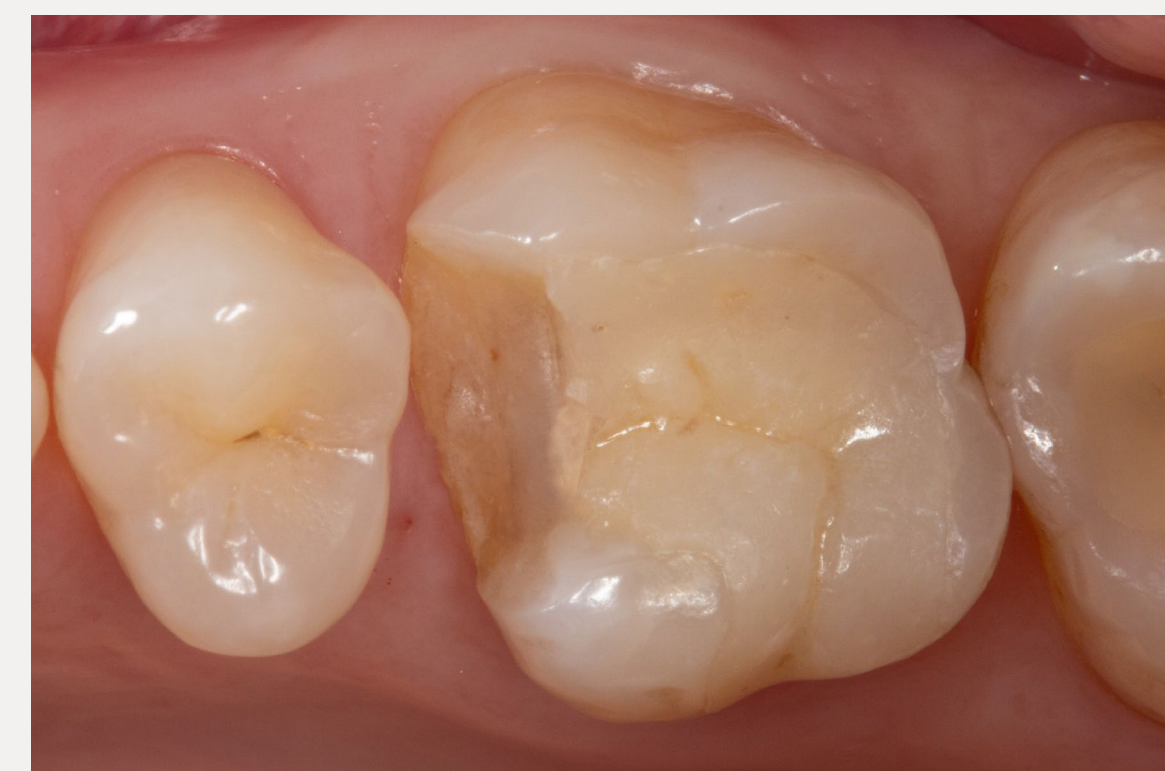Dr. Sven Rinke
Hanau, Germany

Case Description

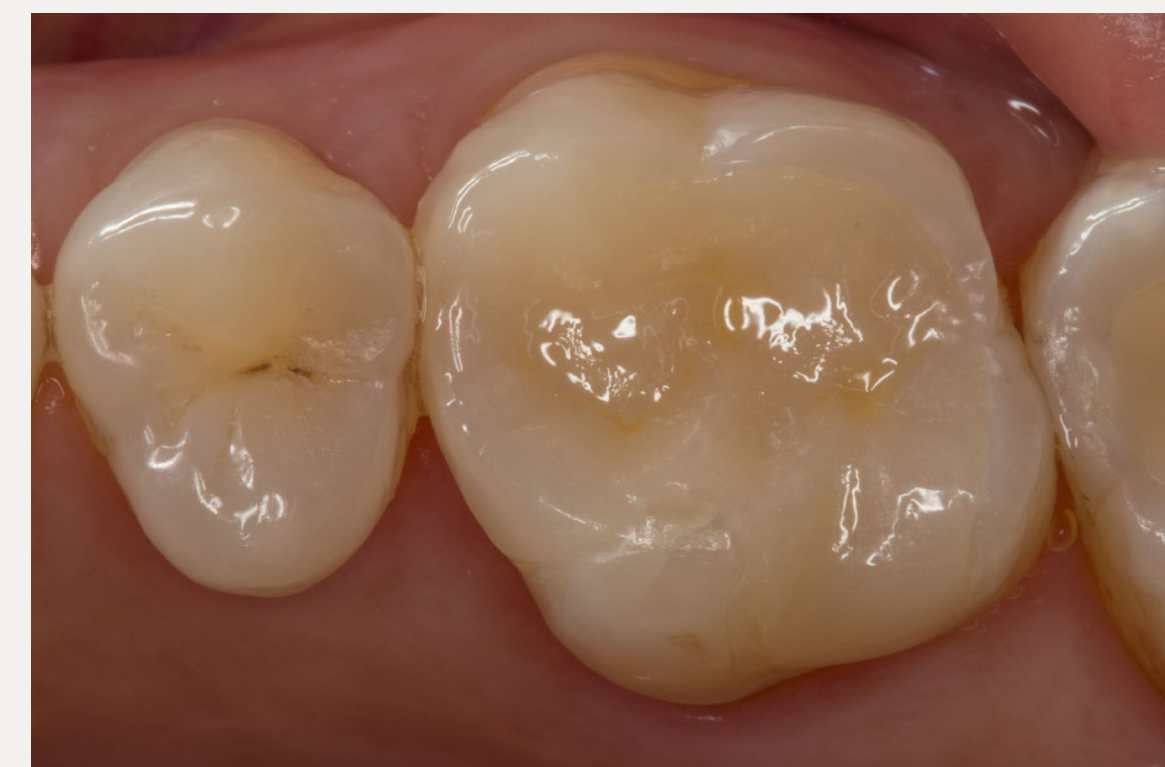A 42-year-old female patient came to my practice with mild pain and a bothersome feeling when chewing on tooth 26. On examination, a fractured ceramic restoration was revealed, but no secondary caries. The patient remembered having received this inlay 12 years ago. It consisted of a leucite-reinforced glass-ceramic, which was adhesively cemented. The patient wanted a replacement of the inlay made of tooth-colored material that would last as long as possible. A chairside-manufactured inlay made of a modern lithium disilicate material (CEREC Tessera) was planned. It offers a strong combination of improved fracture strength (>700 MPa) and translucency, enabling a reduced minimum material thickness of 1.0 mm for adhesively cemented posterior restorations. The good esthetic properties and short processing times predestined CEREC Tessera for this indication. First, the fractured inlay was removed. Subsequently, the margins were finished with fine-grained diamond instruments. The retraction cord placed on the mesial approximal surface was used to control moisture and shift the preparation margin. This was followed by intraoral scanning with CEREC Primescan, inlay design in the CEREC Software, and grinding with CEREC Primemill. The grinding process in Fine mode took just over ten minutes. The subsequent try-in focused on checking the occlusal contacts. This was possible because the material was ground out in a pre-crystallized stage. After application of a Spray Glaze with Fluorescence (DS Universal Spray Glaze Fluo, Dentsply Sirona), the restoration was fired in the pre-heated CEREC SpeedFire with the glaze program lasting four and a half minutes. The restoration was cemented using the total-etch technique with a universal bonding agent (Prime&Bond active) and an adhesive cement (Calibra Ceram). No further occlusal adjustments were necessary. Thanks to the excellent chameleon effect of CEREC Tessera, the restoration blended superbly with the natural dentition. The patient was very satisfied with the esthetic result.

Discussion

The chairside restoration of the tooth in a single visit proved to be a particularly effective and a convenient solution for this patient, as her commute to the practice was around 50 kilometers. CEREC Tessera was used, a material that offers a high level of fracture resistance. The rapid firing cycle further shortened the overall treatment time, enabling the patient to receive a highly esthetic and final restoration in just 100 minutes.



Before:
Fractured ceramic restoration made from a leucite-reinforced glass-ceramic after a clinical service time of 12 years.



After:
Chairside-fabricated restoration made from an advanced lithium disilicate ceramic, CEREC Tessera.



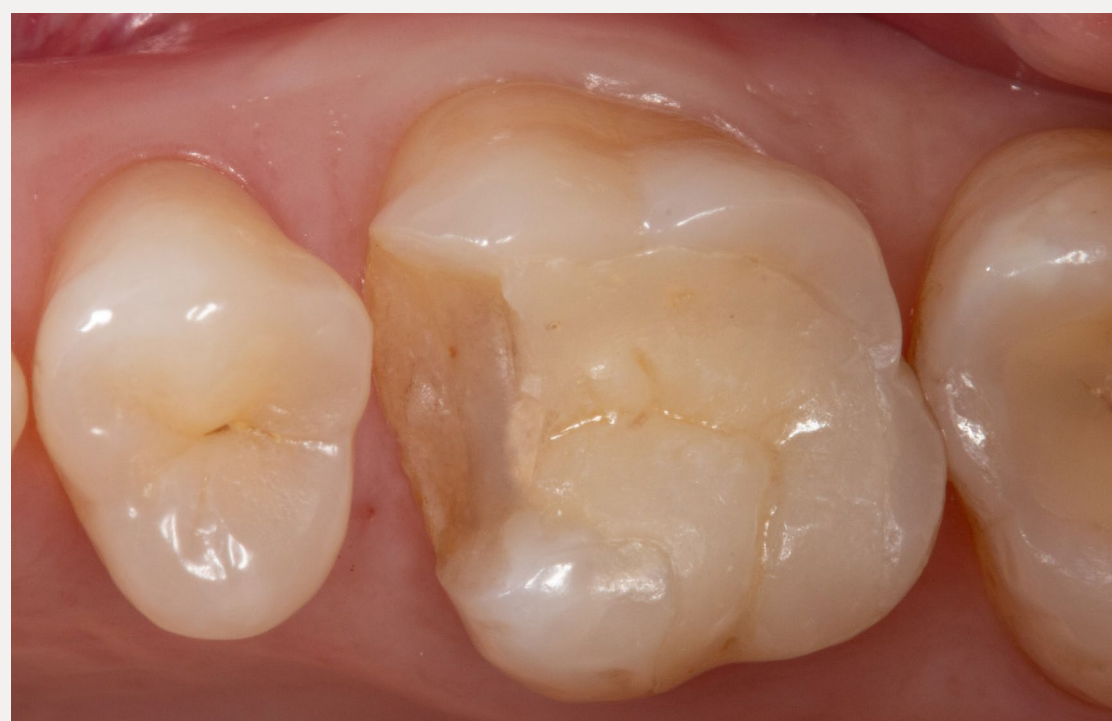

A CEREC Tessera inlay – First upper molar in 100 minutes

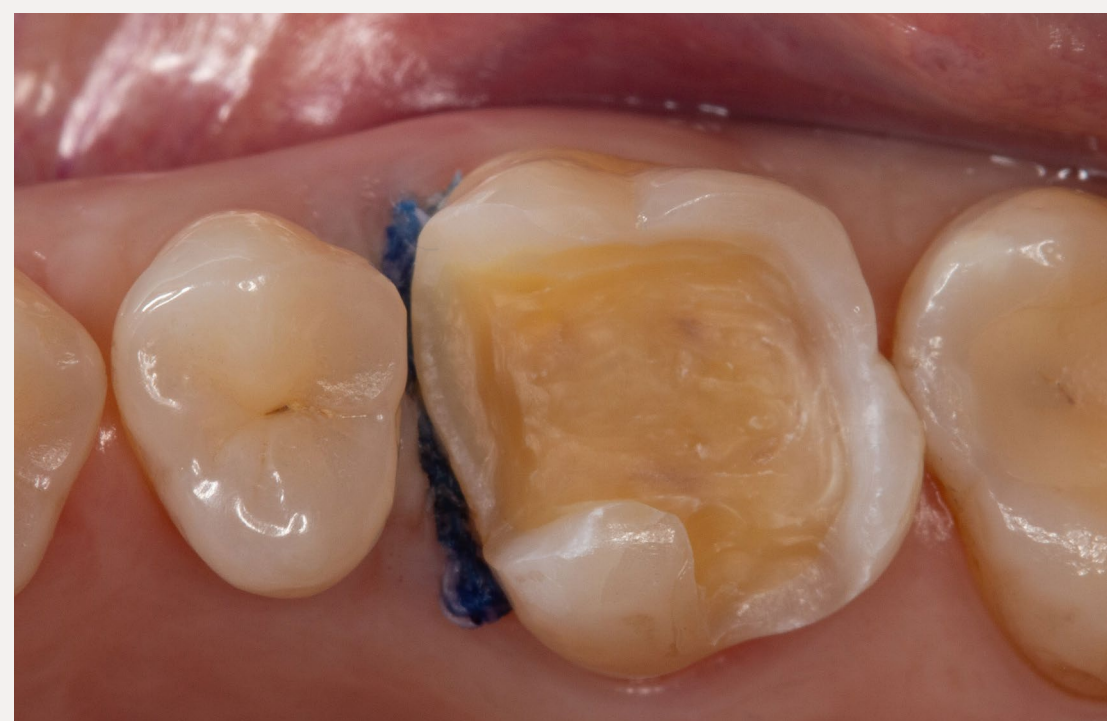

Dr. Sven Rinke
Hanau, Germany

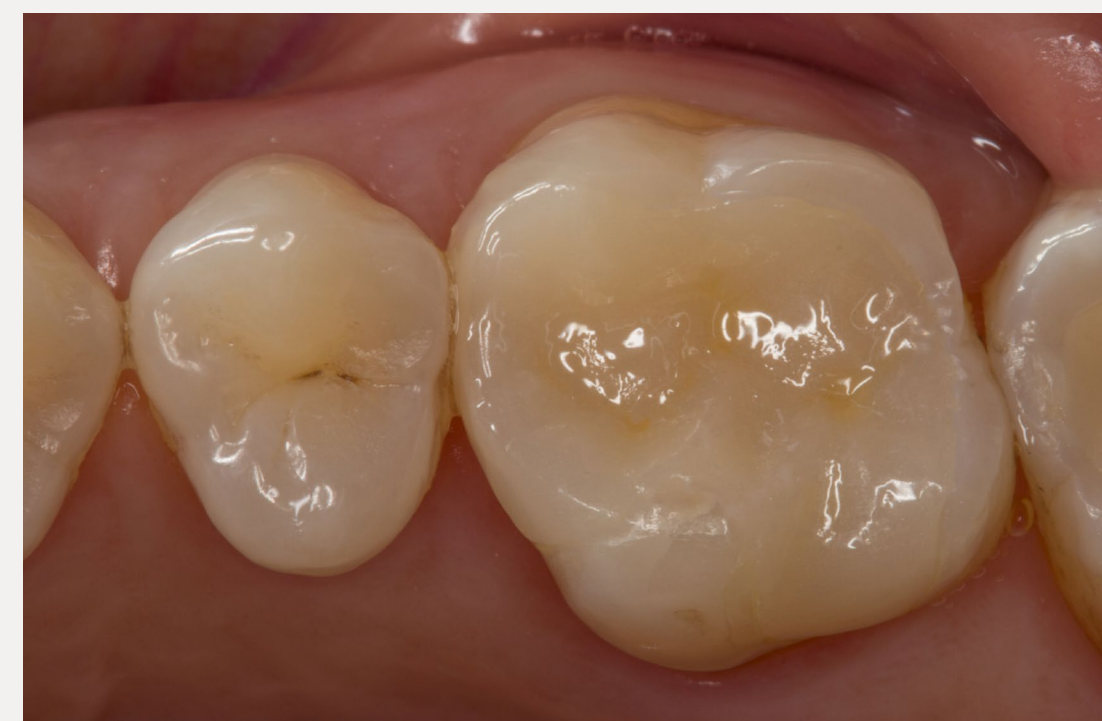Clinical Images



12-year-old inlay.



Preparation for a ceramic inlay and placement of a retraction cord prior to intraoral scanning.



Adhesively luted CEREC Tessera inlay. The inlay was luted with the total-etch technique in combination with a universal bonding agent (Prime&Bond active), and a dual-curing adhesive composite cement (Calibra Ceram).

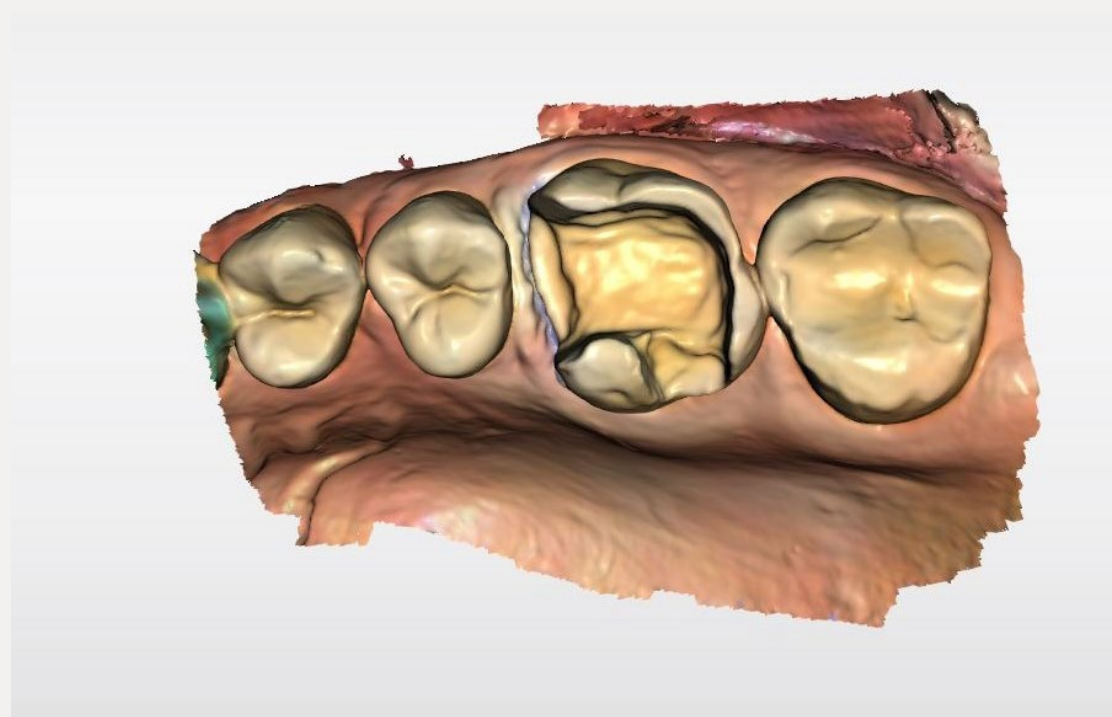


A CEREC Tessera inlay – First upper molar in 100 minutes

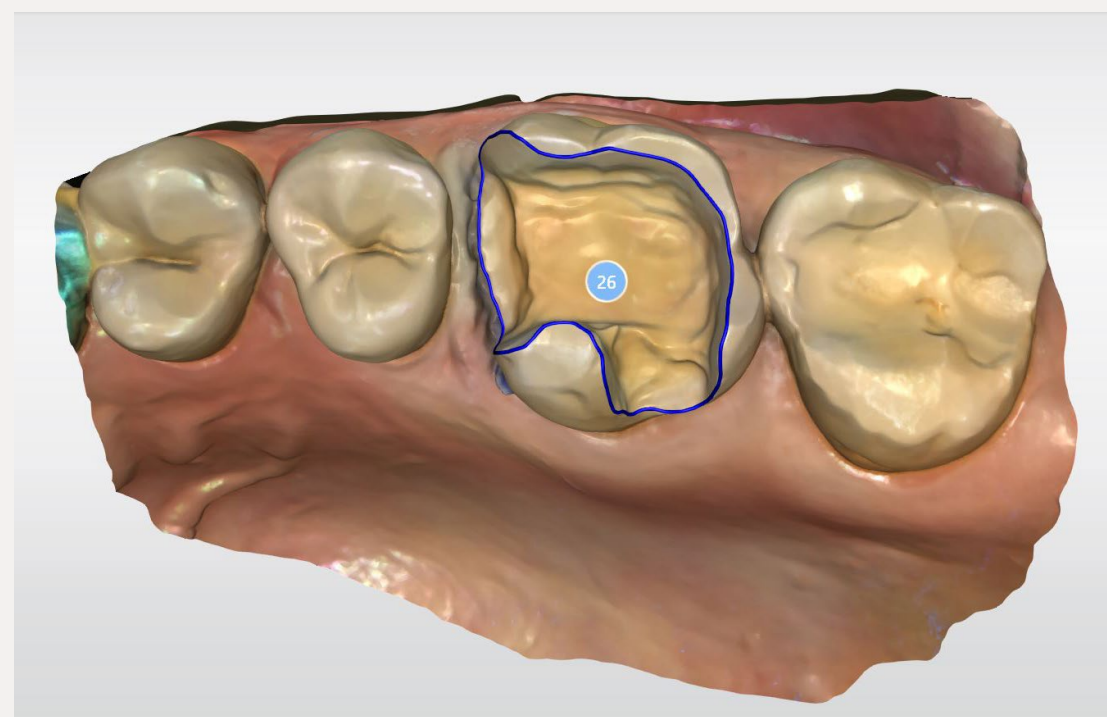


Dr. Sven Rinke
Hanau, Germany

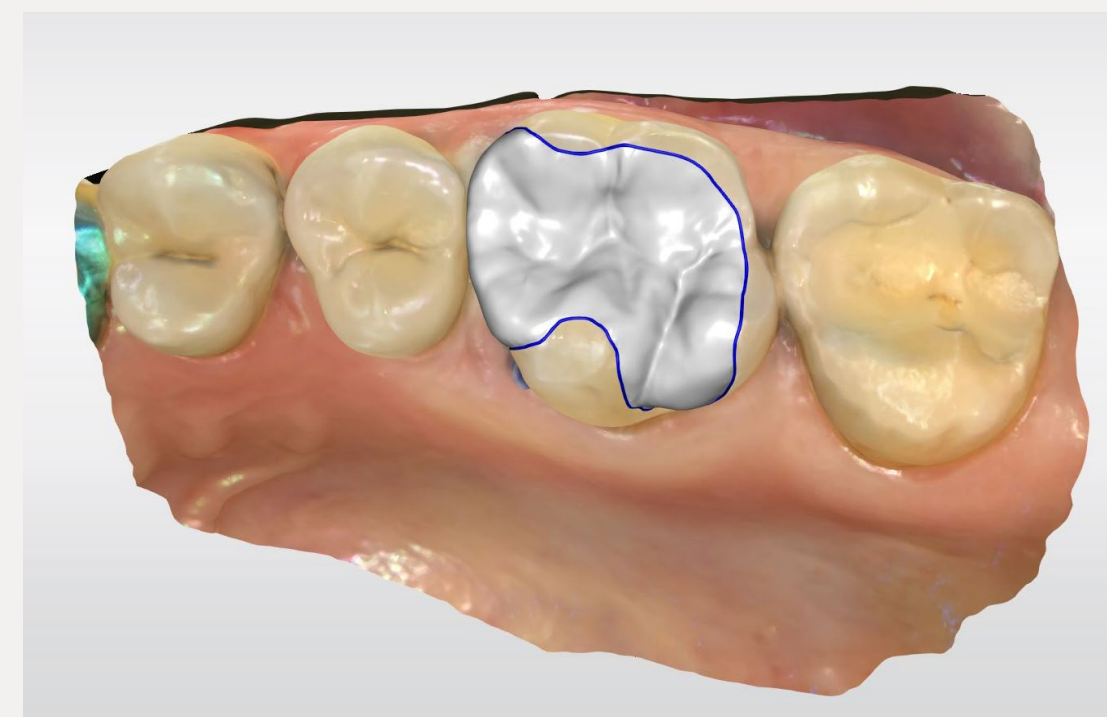
Workflow Images



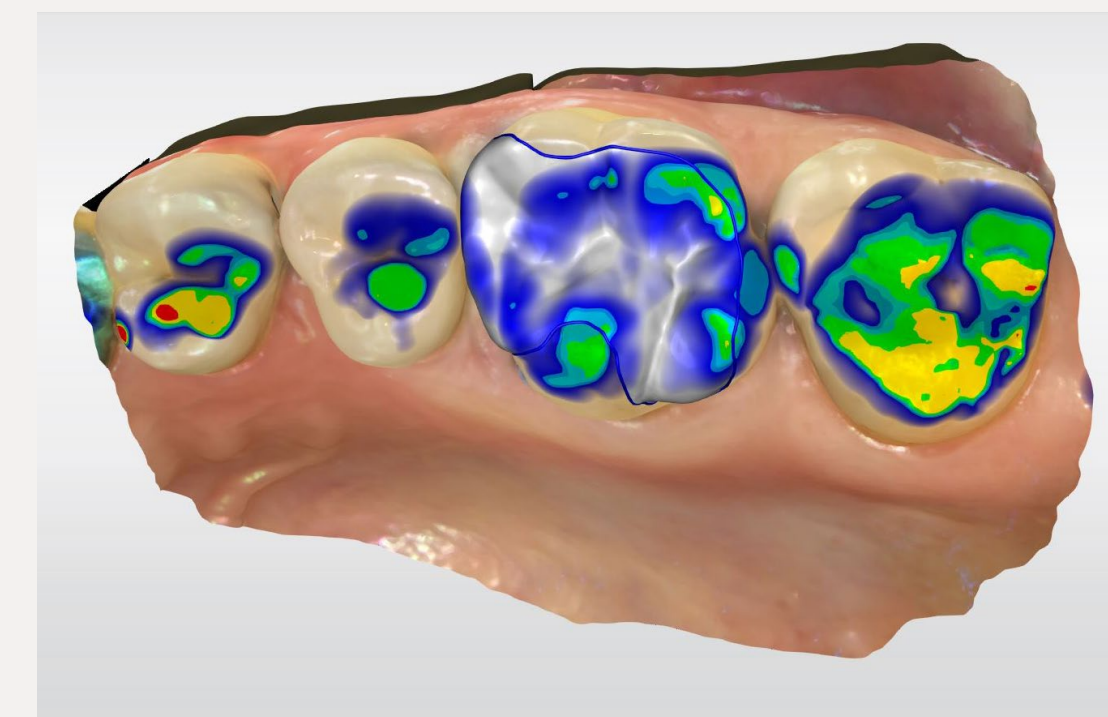
Intraoral scan of the upper and lower jaw using CEREC Primescan.



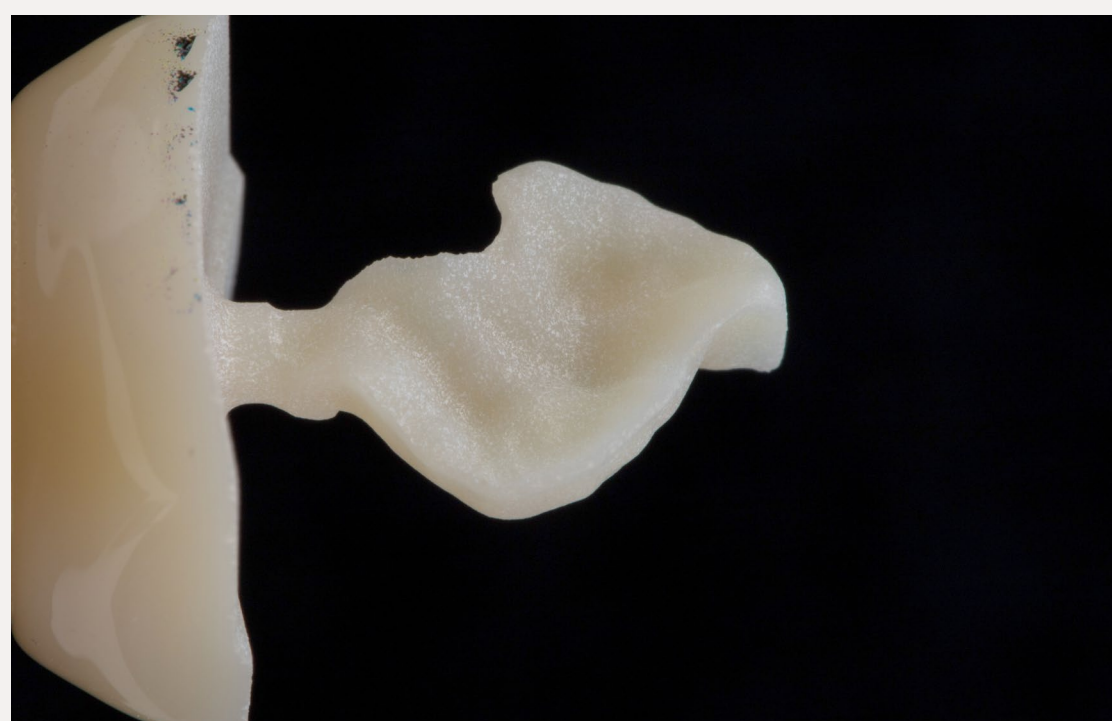
The preparation limit was automatically detected and marked by the CEREC Software.



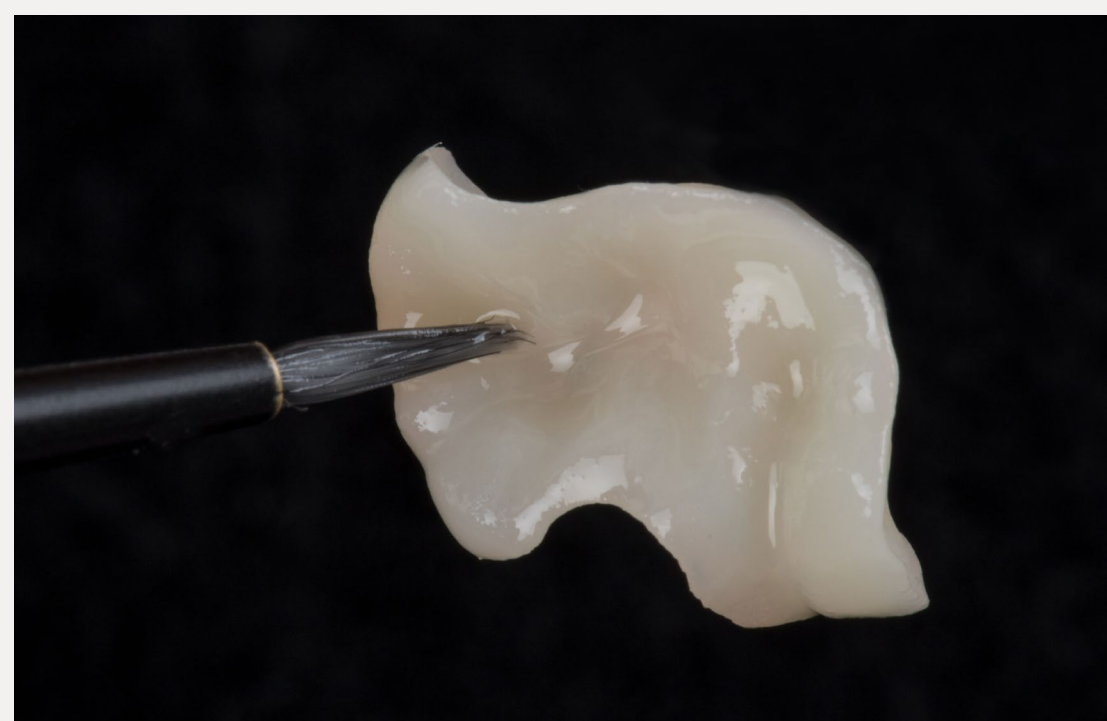
Design proposal generated with the "biogeneric individual" function.




Slight modification of the design proposal was needed to adjust the occlusal contacts.



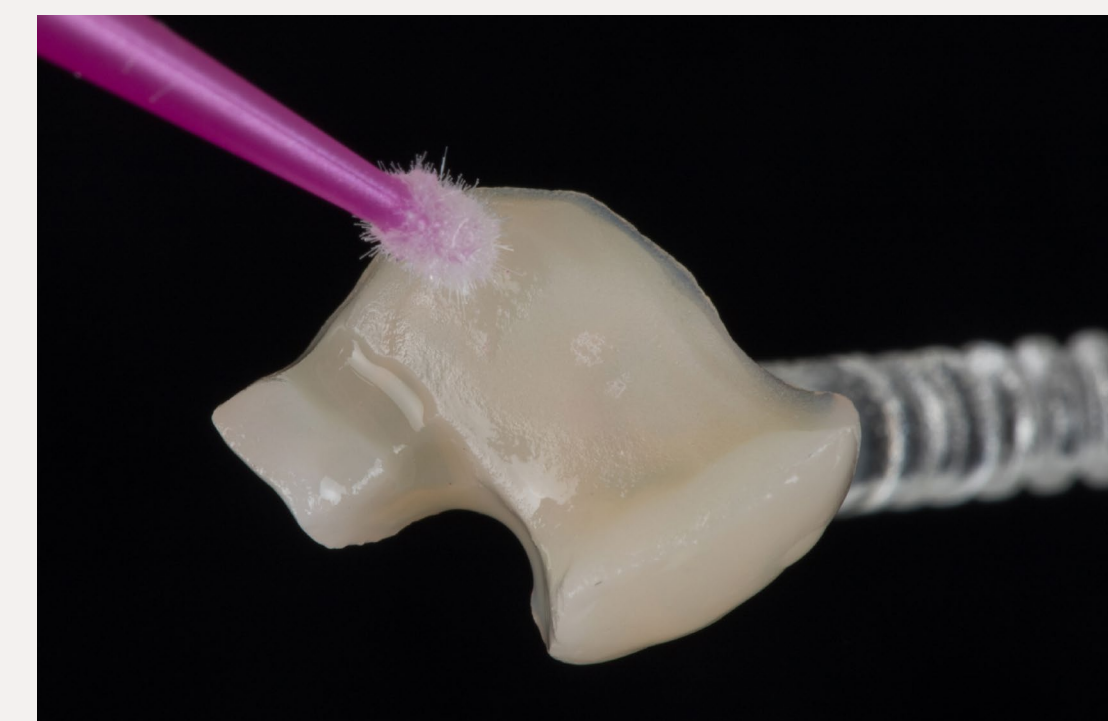Restoration milled from an advanced lithium disilicate ceramic (CEREC Tessera) in CEREC Primemill.



For the final step, a glaze firing (with e.g. DS Universal Stain & Glaze System) is mandatory.



The internal surface of the inlay restoration is etched with 5% hydrofluoric acid for 30 seconds.



A silane coupling agent (Calibra Silane, Dentsply Sirona) was applied prior to adhesive luting of the restoration.



A CEREC MTL Zirconia crown – Second upper premolar in 90 minutes



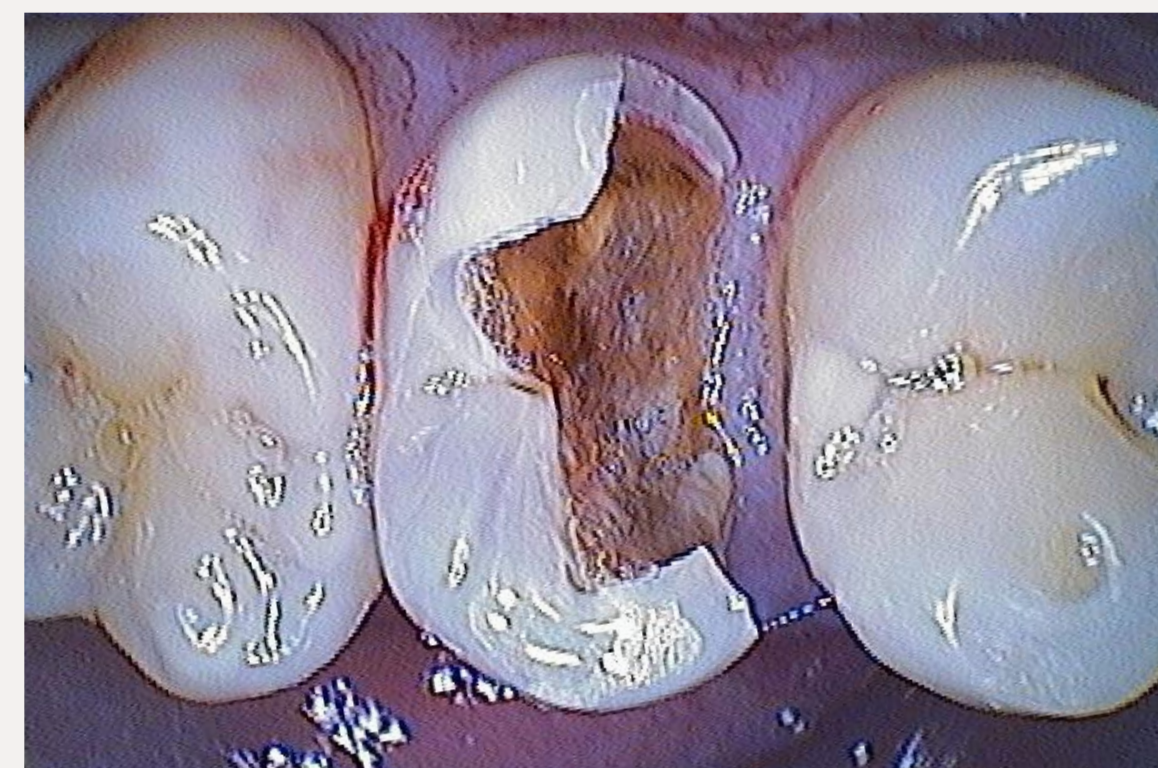Dr. Cecilie Terjesen
Arendal, Norway

Case Description

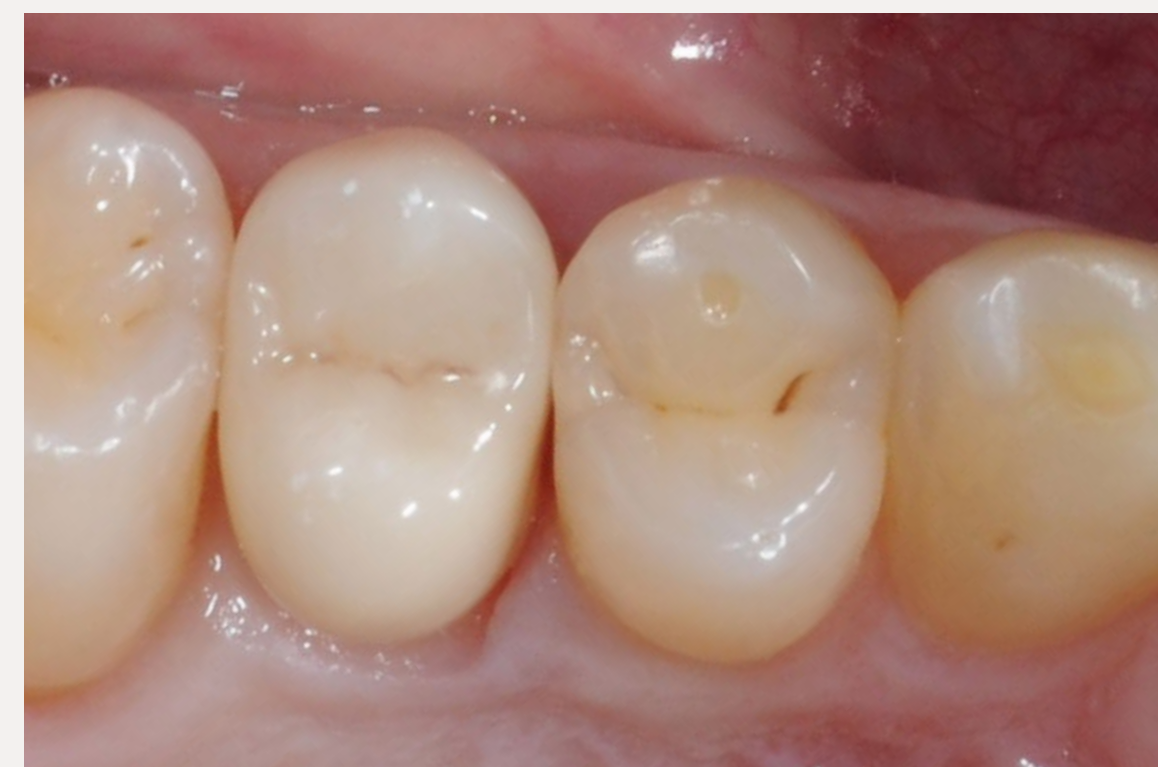A 32-year-old male patient came to the clinic for a check-up after putting off going to the dentist for seven years. He presented with a large carious mesial lesion on tooth 15. The tooth showed asymptomatic apical periodontitis and a significant loss of tooth structure. The patient was motivated for treatment. First, the tooth was treated endodontically. A fiber post was inserted to build up the core. Finally, the tooth was to be restored with a crown. At the beginning of the restorative treatment, the patient received local anesthesia. While the anesthetic was taking effect, a preoperative scan was performed with CEREC Primescan. After preparation, another scan was taken. The CEREC Software provided effective support in defining the preparation margins. The restoration was then designed using the Biogeneric individual function. CEREC MTL Zirconia was the material selected because it promises both high strength and exceptionally good esthetics. The crown was milled in shade A3 in the CEREC Primemill in Fine mode. This process took about 12 minutes. The result was a restoration with a filigree crown margin. After polishing the occlusal surface, the crown was sintered in CEREC SpeedFire, which took approximately 21 minutes. For individualization, the crown was glazed with the DS Universal Stains & Glaze System. The interproximal surfaces and cervical areas that were in contact with the gingiva were left out of the glaze. Only polishing was performed in this area. Finally, the inner surfaces of the restoration were sandblasted with 50 µm aluminum oxide at a pressure of 2 bars and then vaporized. After cleaning, the restoration was incorporated and cemented in place. The treatment lasted around 90 minutes in total. The patient was pleased that he received a complete restoration in a single visit. He was very satisfied with the function and esthetics of the final result.

Discussion

Together with the patient, the decision was made in favor of tooth-preserving treatment. The alternative would have been to extract the tooth and replace it with an implant or a bridge restoration. However, this was rejected due to the patient's young age.



Before:
A large carious mesial lesion on tooth 15. The tooth showed asymptomatic apical periodontitis and a significant loss of tooth structure.



After:
Chairside-fabricated restoration designed using the Biogeneric individual function. CEREC MTL Zirconia was the material selected because it promises both high strength and exceptionally good esthetics.



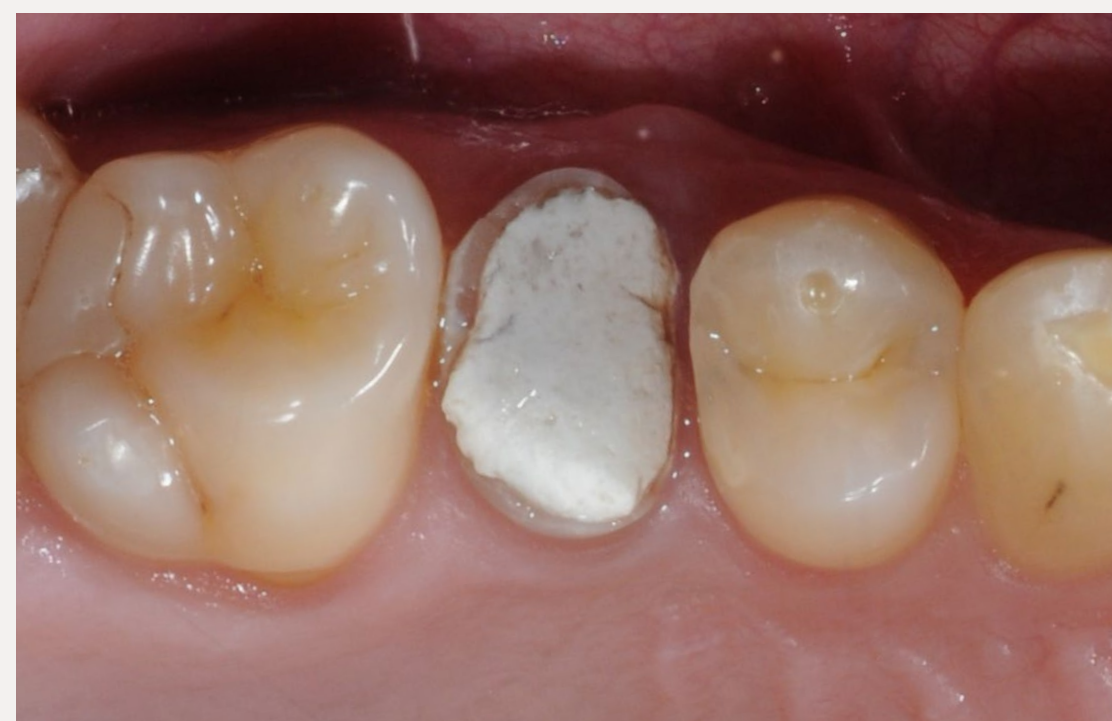

A CEREC MTL Zirconia crown – Second upper premolar in 90 minutes

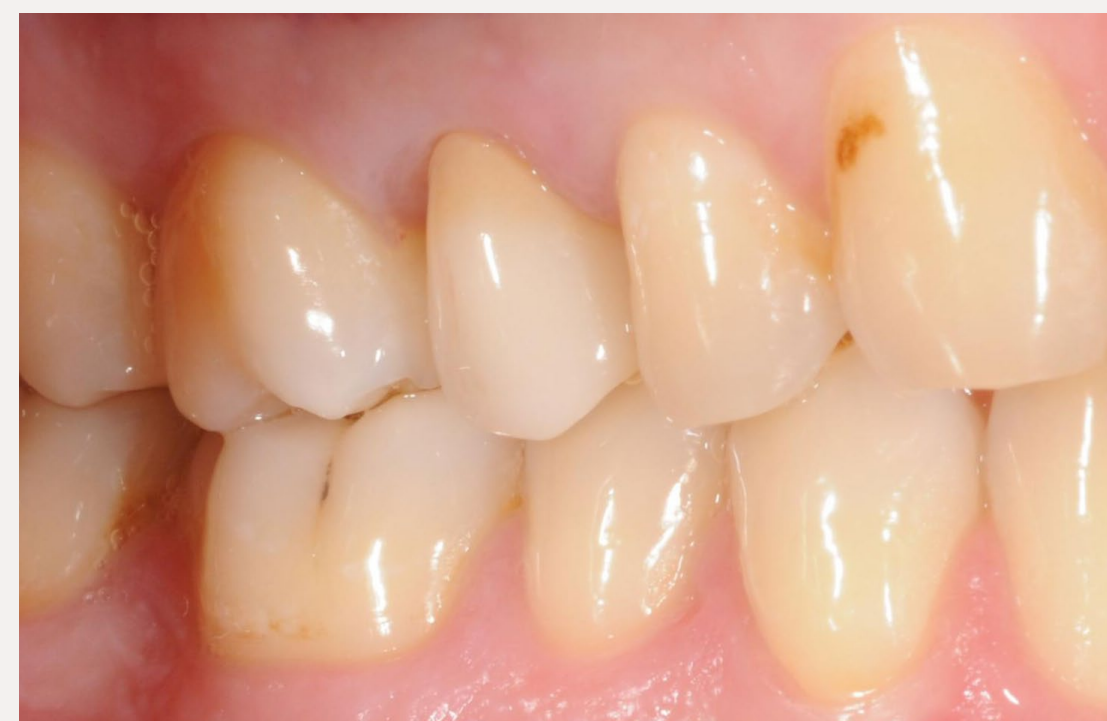

Dr. Cecilie Terjesen
Arendal, Norway

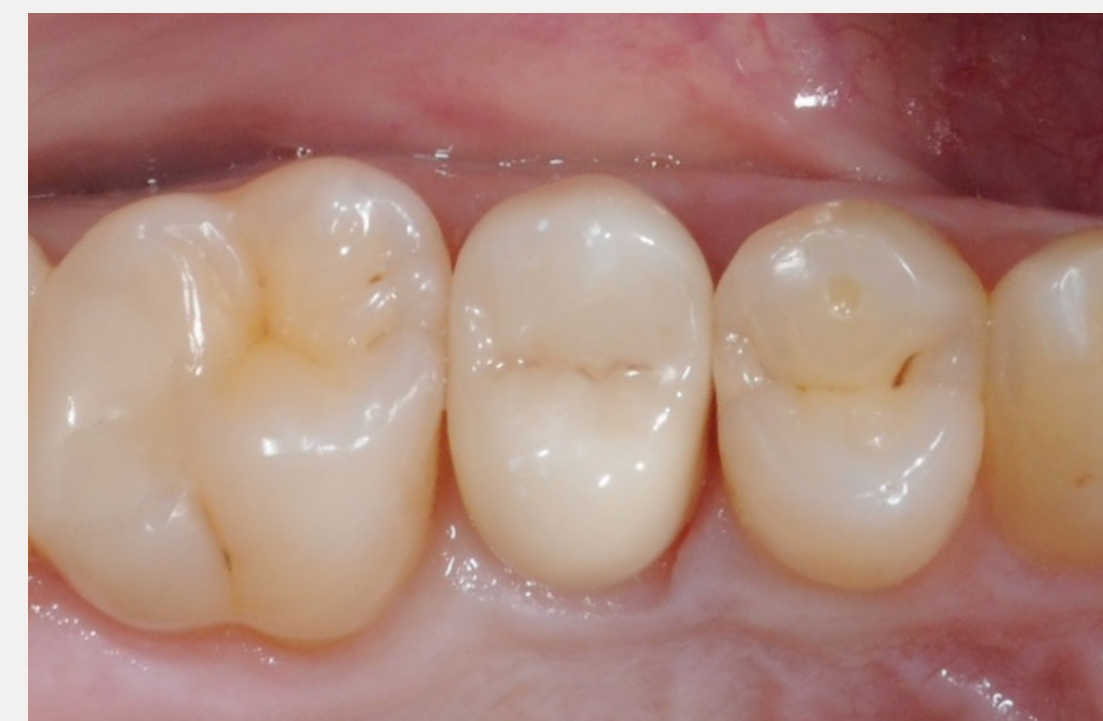Clinical Images



Initial situation after endodontic treatment: the mesial wall was temporarily built up here with composite for rubber dam placement.



Final crown – buccal.



Final crown – occlusal.

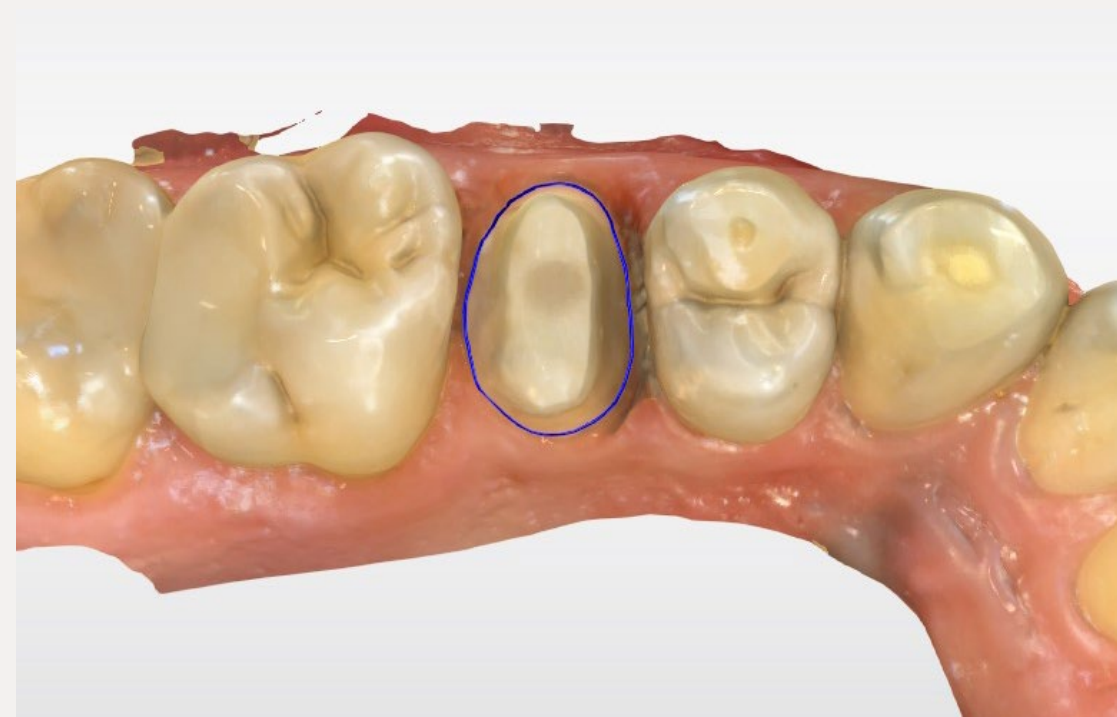

A CEREC MTL Zirconia crown – Second upper premolar in 90 minutes



Dr. Cecilie Terjesen
Arendal, Norway

Workflow Images



Crown margination.

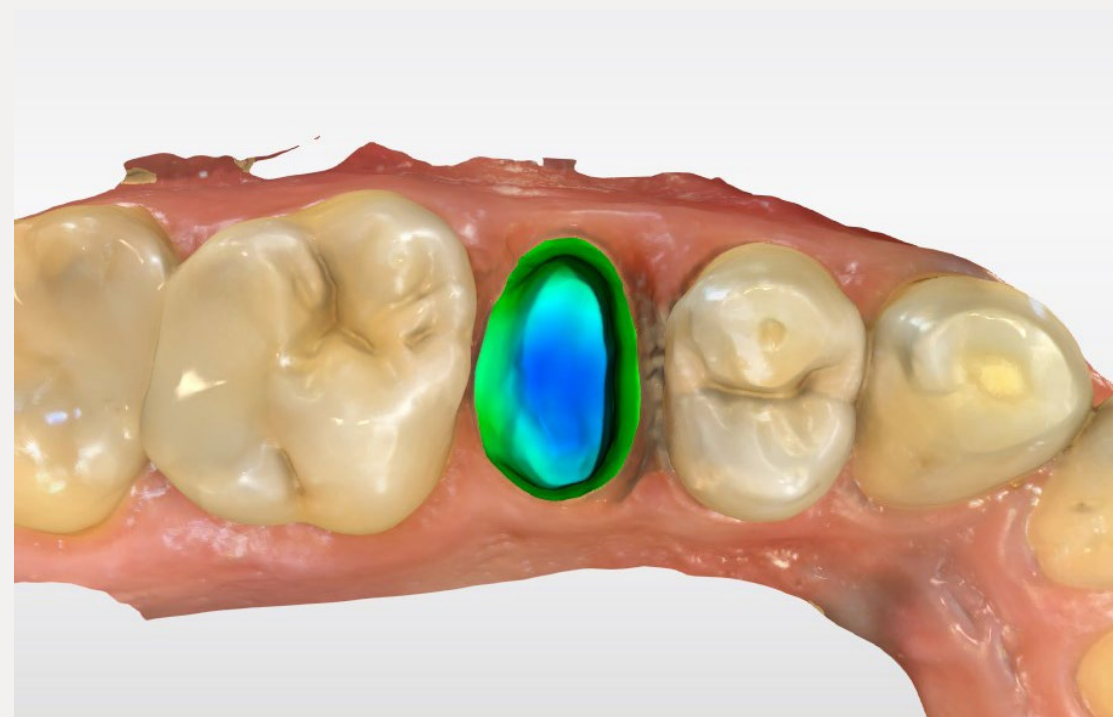
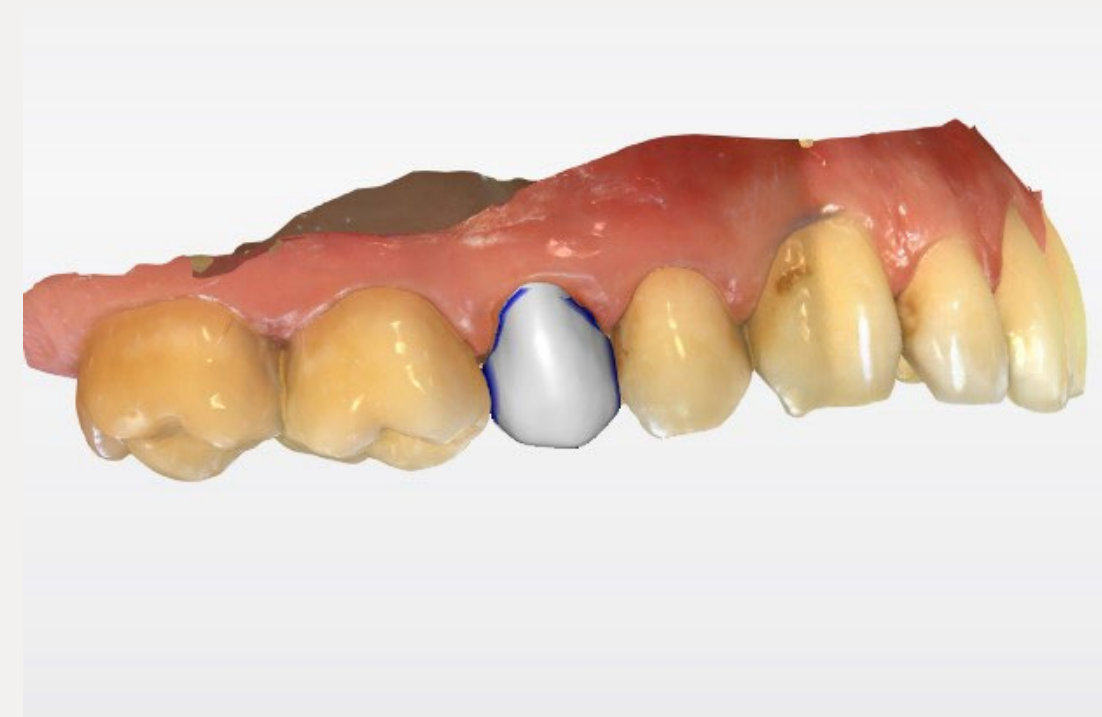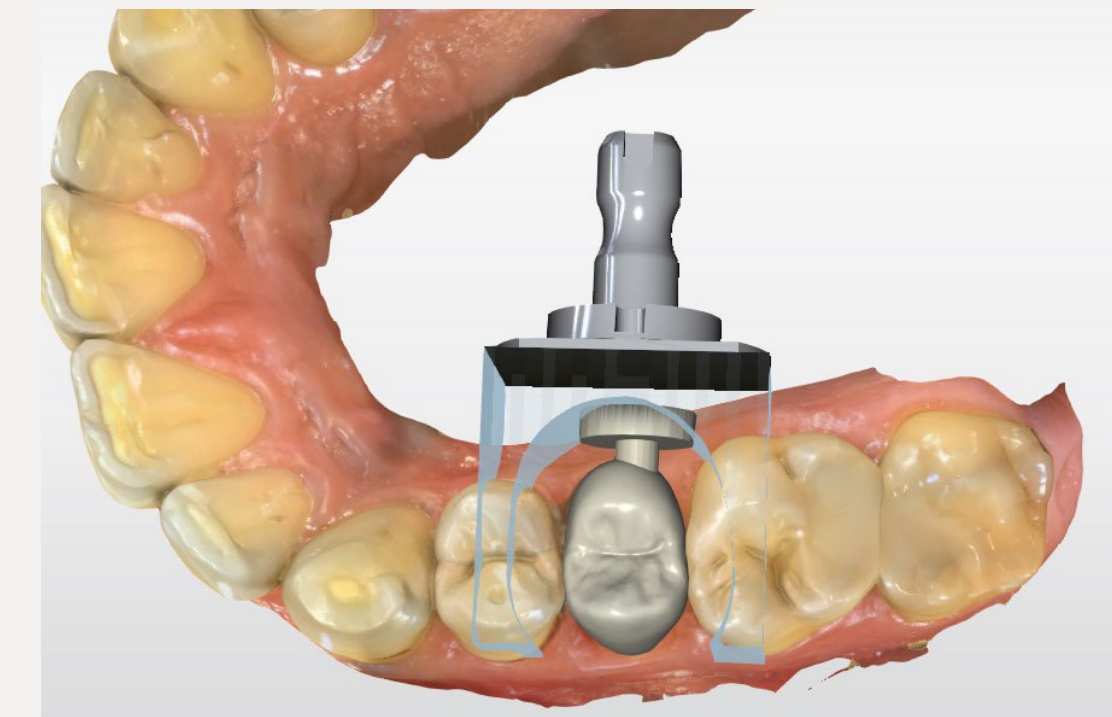



Image of crown preparation.




Design check – buccal.



Manufacture preview of final crown.



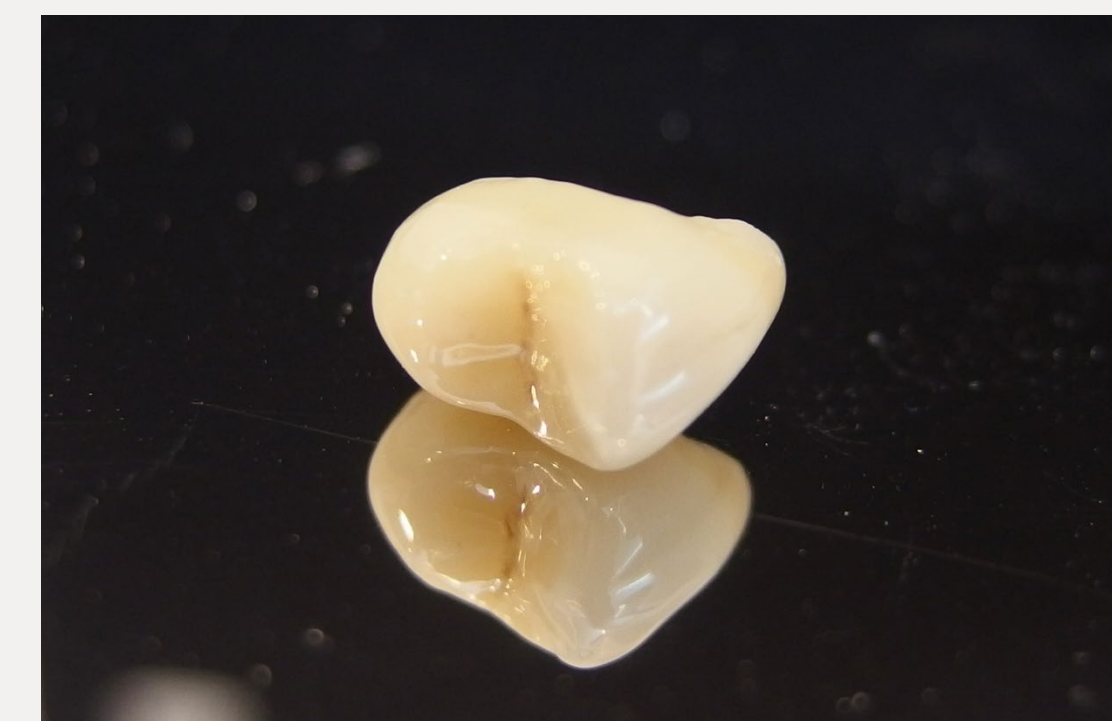Crown milling with CEREC MTL Zirconia in CEREC Primemill.



The crown right before sintering.



The crown is placed in CEREC SpeedFire.



Final crown.



Two CEREC Tessera crowns and two inlays – Quadrant rehabilitation



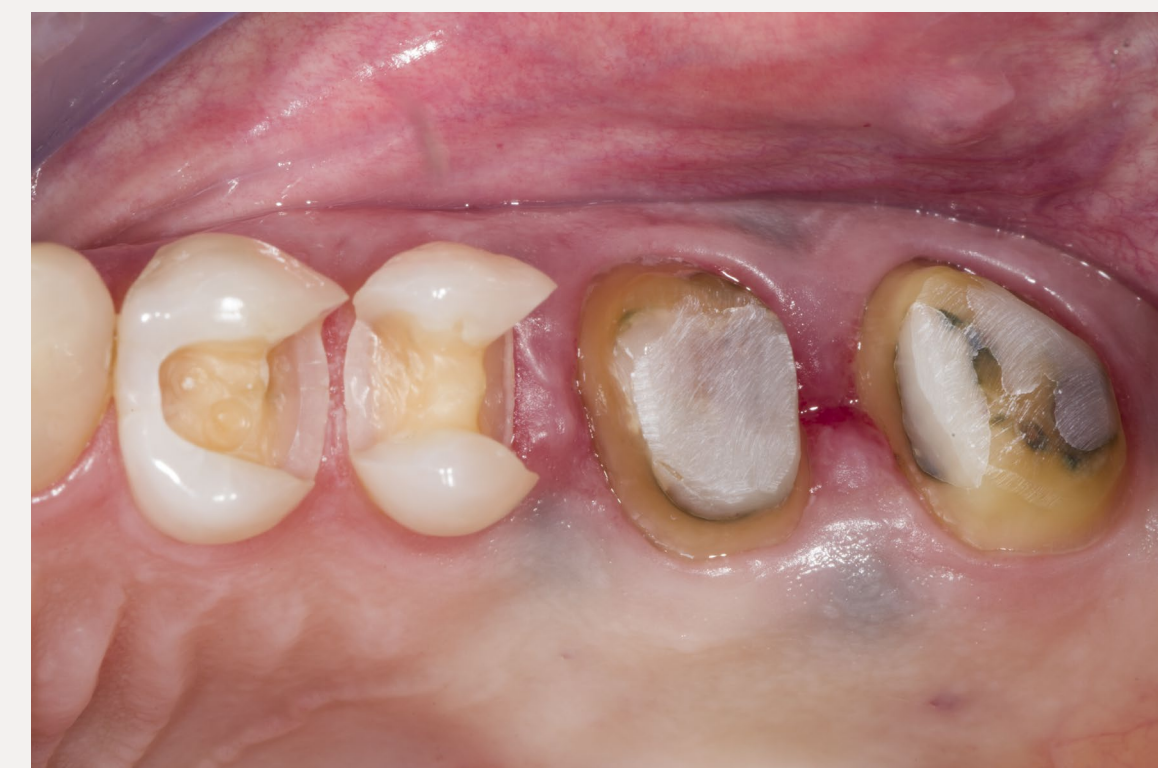Dr. Andreas Bindl
Zurich, Switzerland

Case Description

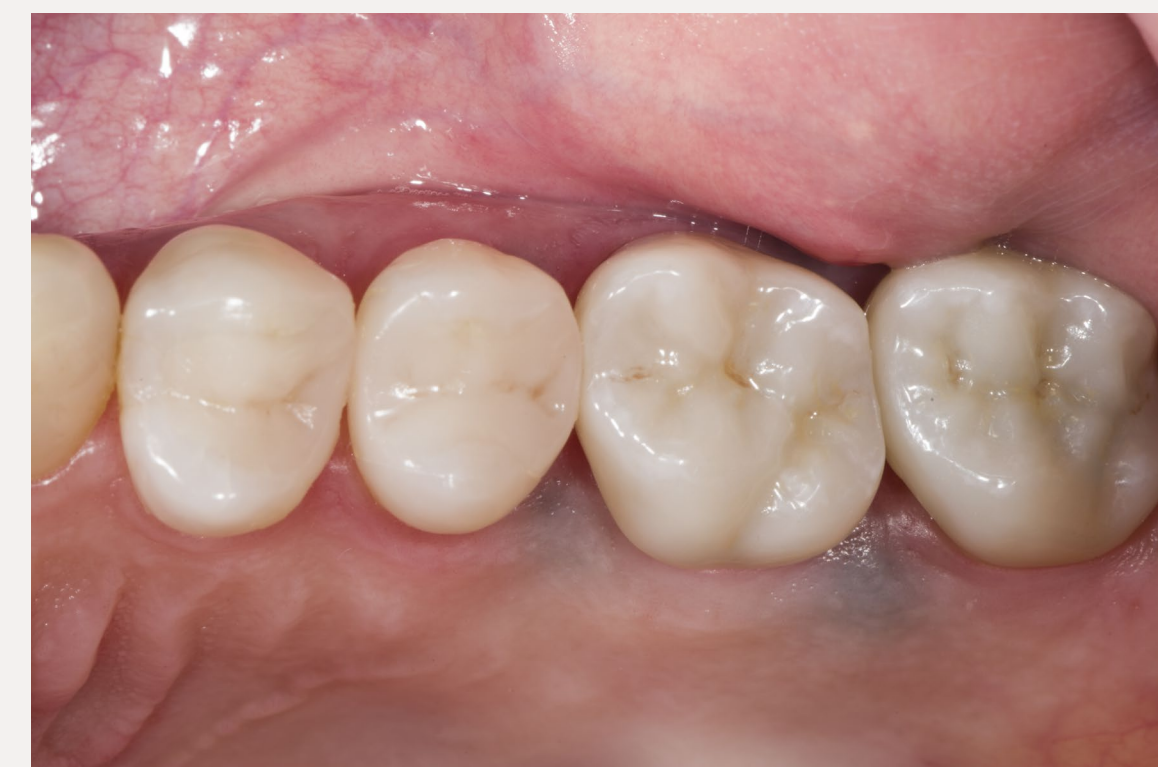A 53-year-old female patient visited my practice with insufficient fillings in the second quadrant. According to the patient, the restorations were about 15 years old. She wanted them to be completely rehabilitated and restored metal-free. At a follow-up visit, she complained about inflamed gingiva in the area of the two left upper molars, and she was also troubled by the inadequate esthetics of the PFM crowns on teeth 26 and 27. The clinical examination revealed relatively severe bleeding on probing, with open crown margins. The intraoral radiograph confirmed these findings. Probing depths were between 2-4 mm. Iatrogenic gingivitis was diagnosed; the patient's oral hygiene was very good. The composite filling on tooth 25 showed an open discolored joint with incipient secondary caries, and a distinct step was palpable toward the cervix of tooth 24 on the filling. All teeth were vital and pain-free. Due to the small interocclusal distances, it was clear that very little space would be available for new crowns. For this reason, a medium-strength ceramic was required to fabricate the crowns for teeth 26 and 27 in a correspondingly thin layer of thickness. Teeth 24 and 25 would each receive an inlay to restore optimum function. After the preparation of all four teeth, an intraoral scan with CEREC Primescan was performed and completed in under three minutes. The inlays and crowns were then designed in the CEREC Software. In the lateral view, the final bite position could be displayed and precisely checked. The crowns were produced in CEREC Primemill using the Extra Fine grinding mode from the advanced lithium disilicate block CEREC Tessera in 15 minutes each. The filigree crown margin was a particularly impressive feature. The high accuracy of fit achieved in this way made post-processing virtually superfluous. Prior to cementation, the crowns were treated with the DS Universal Stain and Glaze System (Dentsply Sirona) and fired in CEREC SpeedFire. Adhese Universal and Variolink Esthetic (Ivoclar Vivadent) were used for cementation. Due to the shallow cavity depth for the inlay preparations and because of the thin tapered margins of the inlays, it was not possible to use a ceramic for this, as the layer thickness would not have been sufficient. Instead, they were milled out of a composite block (Tetric CAD, Ivoclar Vivadent) in Extra Fine mode and adhesively cemented with Adhese Universal & Variolink Esthetic (Ivoclar Vivadent).

Discussion

The restoration of the second quadrant with two inlays and two full crowns was carried out chairside in a single visit of about four hours. This was possible due to the time-saving fabrication of the restorations with CEREC Primemill. The main challenges were the very low dye height at 26 and 27, and the shallow cavity depth for the inlays. These circumstances led to the decision to restore the teeth with different materials that give a very good esthetic result, which also pleased the patient.



Before:
Insufficient fillings in the second quadrant. The restorations were about 15 years old.



After:
Chairside-fabricated crowns made from CEREC Tessera (teeth 26/27). Inlays for teeth 24 and 25 with Tetric CAD, Ivoclar Vivadent.



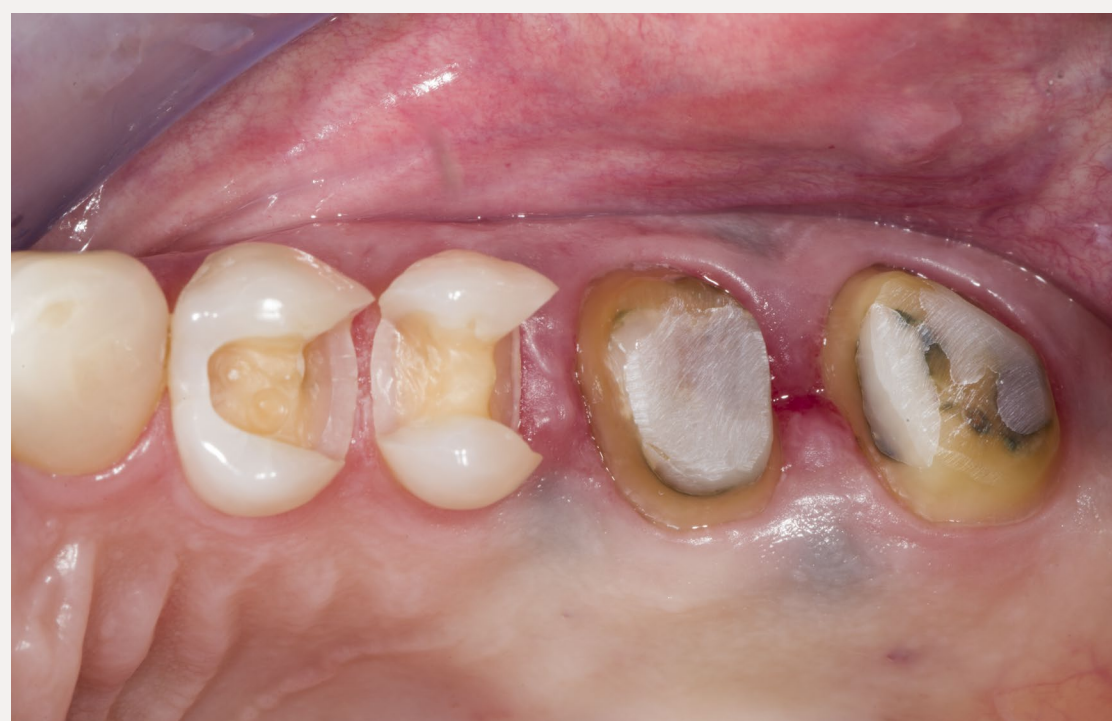

Two CEREC Tessera crowns and two inlays – Quadrant rehabilitation

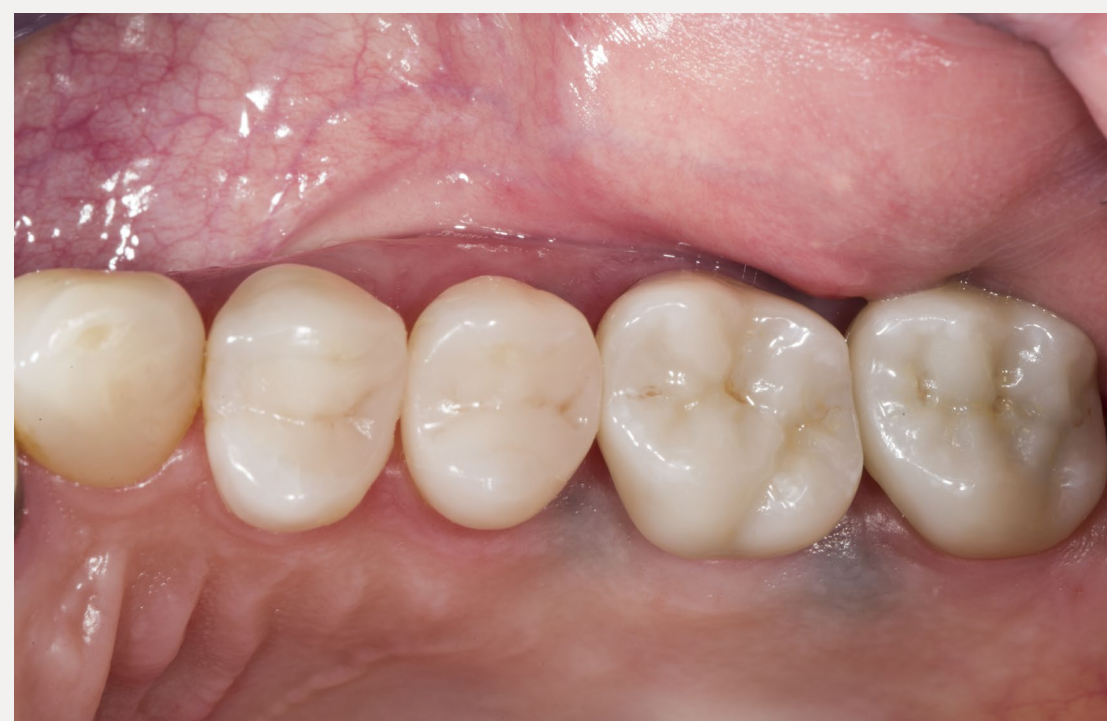

Dr. Andreas Bindl
Zurich, Switzerland

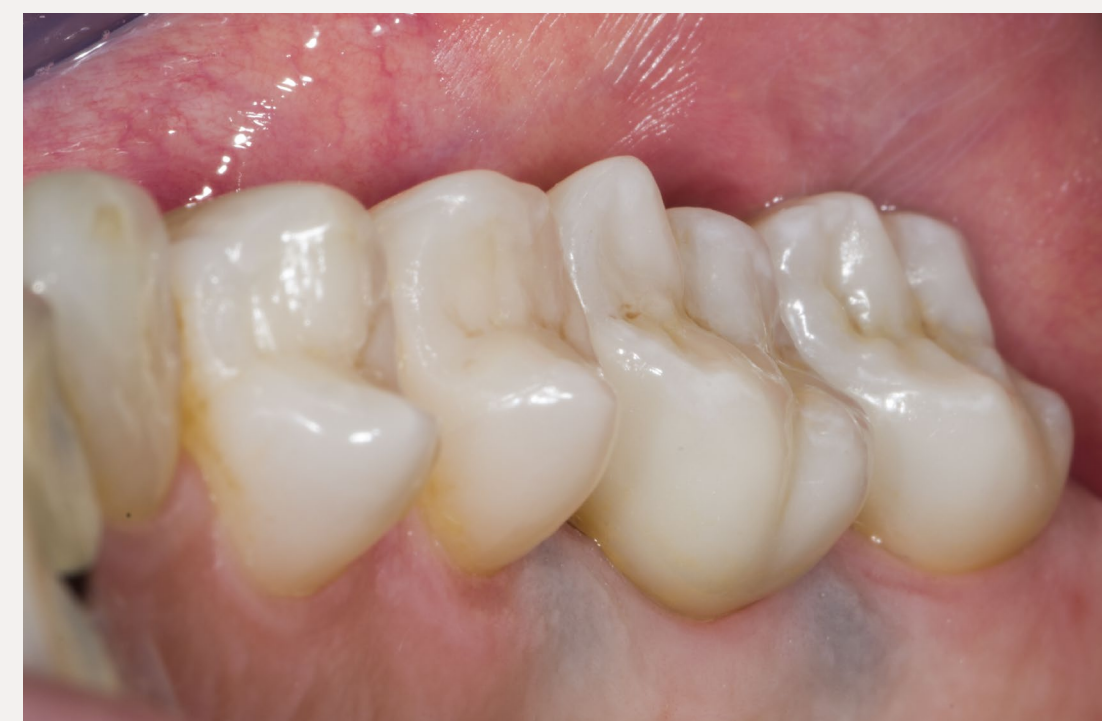Clinical Images



Patient with insufficient fillings in the second quadrant and inadequate esthetics of the PFM crowns on teeth 26 and 27. The composite filling on tooth 25 showed an open discolored joint with incipient secondary caries, and a distinct step was palpable toward the cervix of tooth 24 on the filling.



Final crown and inlays – occlusal.



Final crown and inlays – palatal.

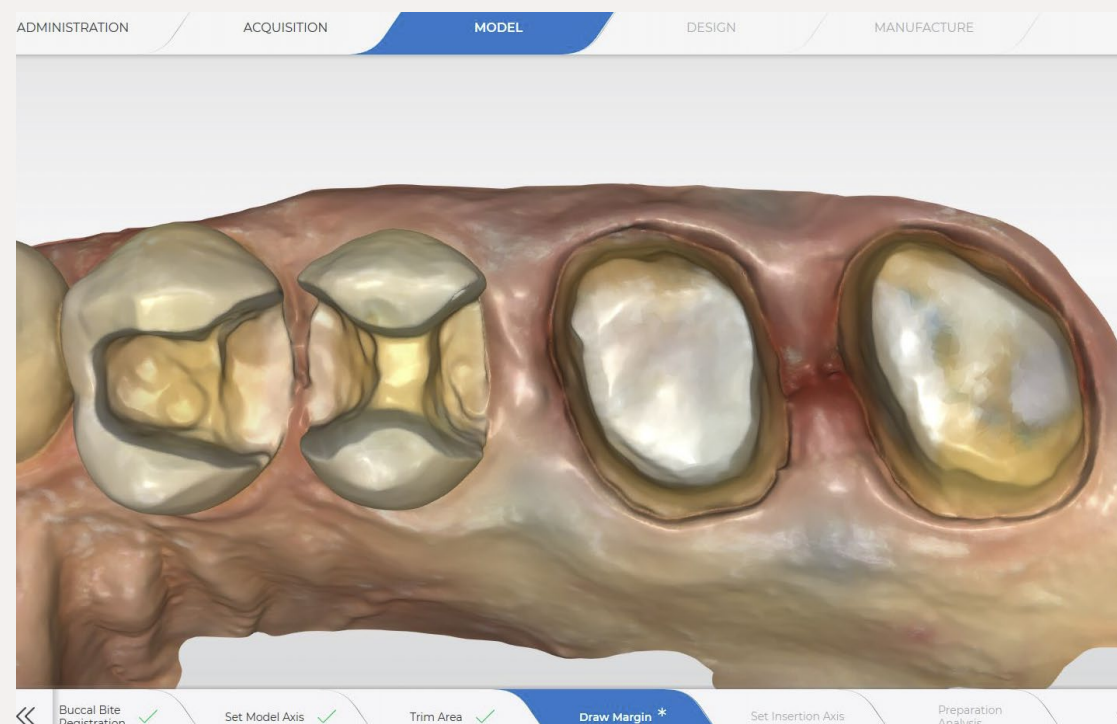


Two CEREC Tessera crowns and two inlays – Quadrant rehabilitation

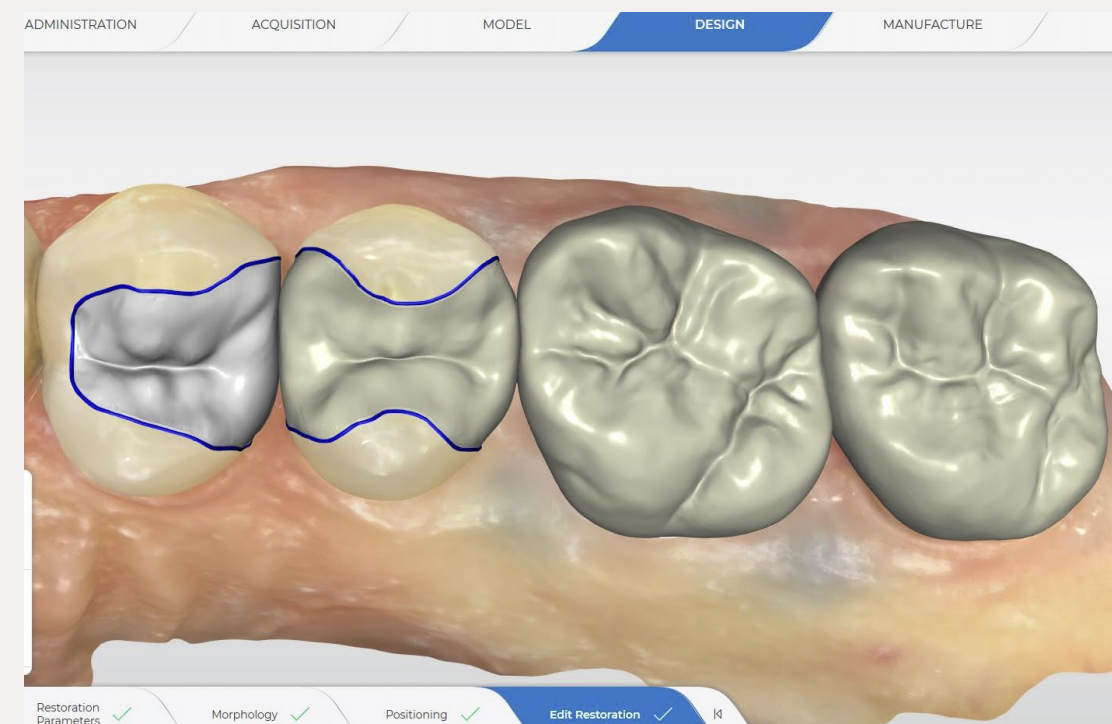


Dr. Andreas Bindl
Zurich, Switzerland

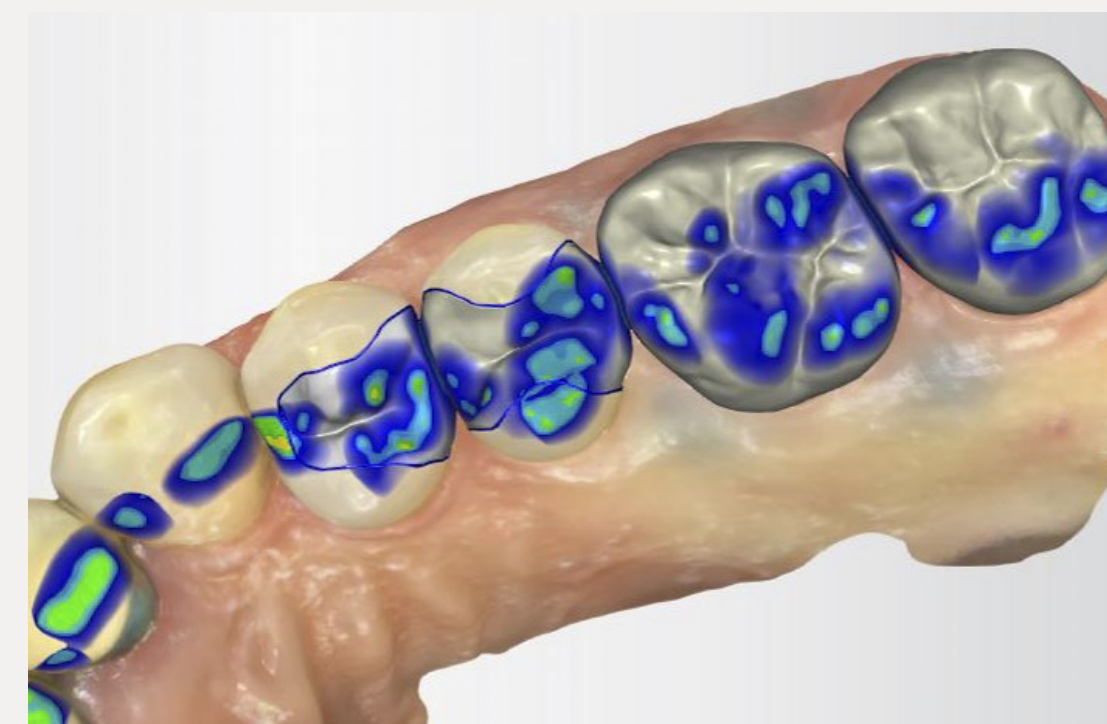
Workflow Images



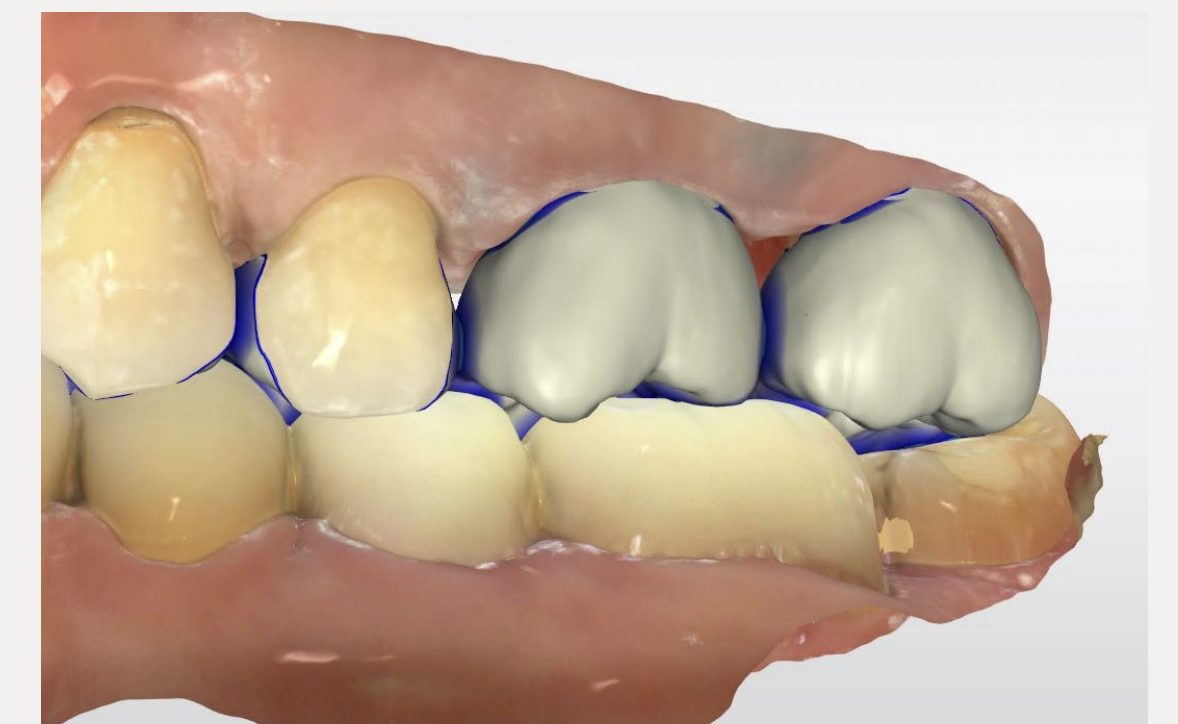
Intraoral scan of the insufficient fillings, using CEREC Primescan.



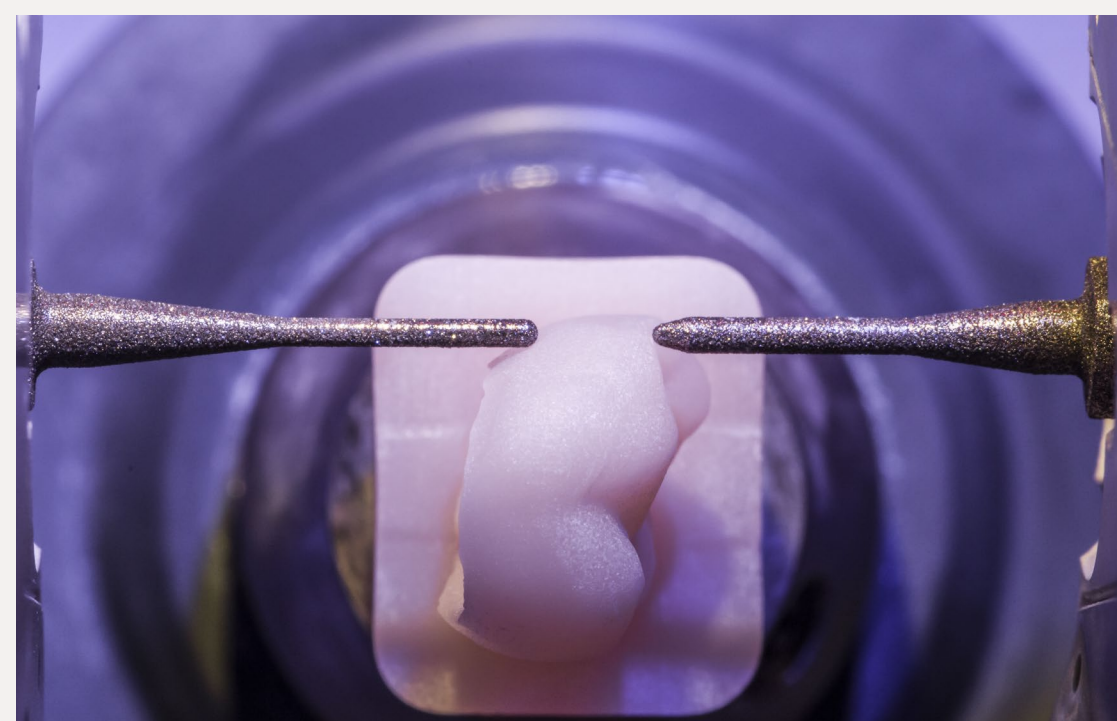
Design proposal generated with the "biogeneric individual" function.



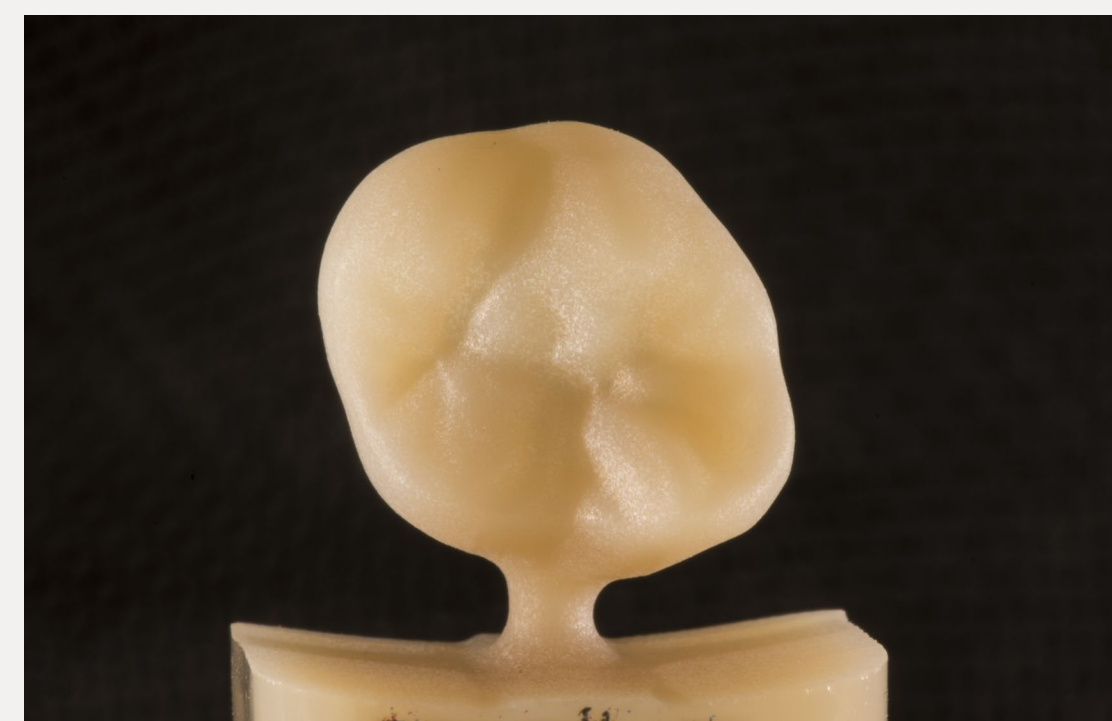
A slight modification of the design proposal was needed to adjust the occlusal contacts.



Buccal preview of crowns in CEREC Software.




Crown being milled in CEREC Primemill.



Final crown without final preparation.



An IPS e.max CAD single crown – Second upper premolar in 60 minutes



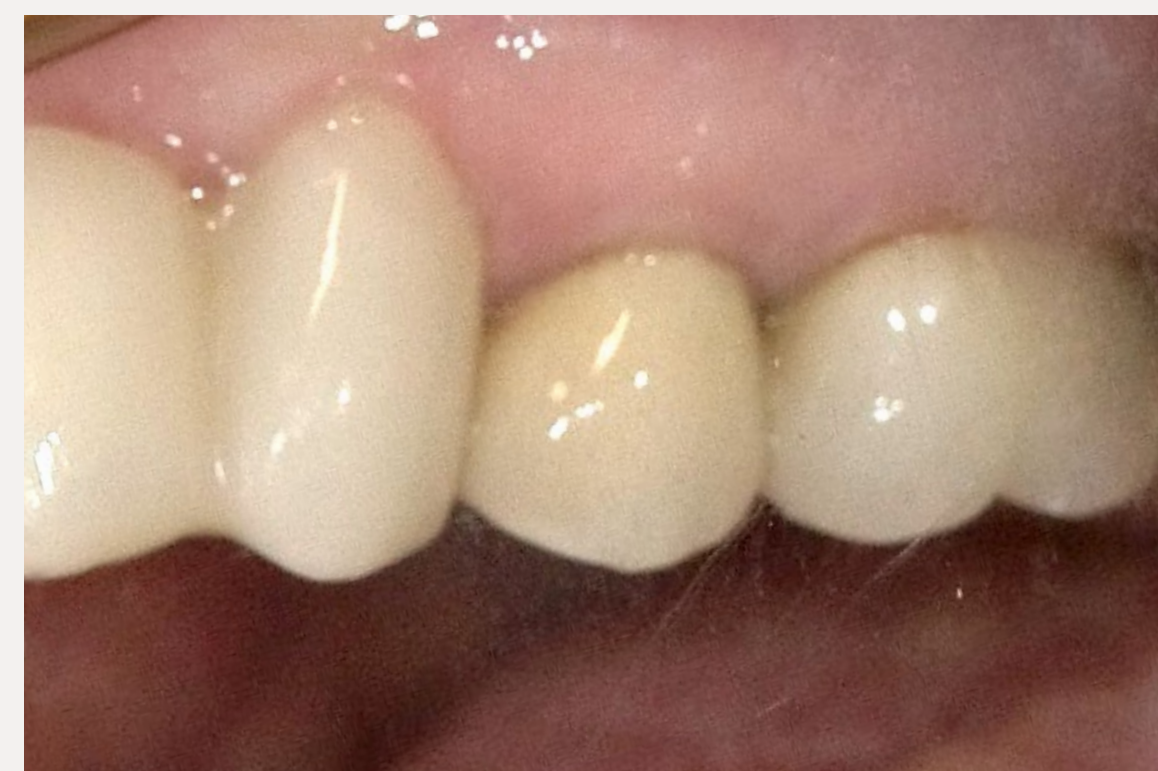Dr. Frank Clark Brown
Melbourne, USA

Case Description

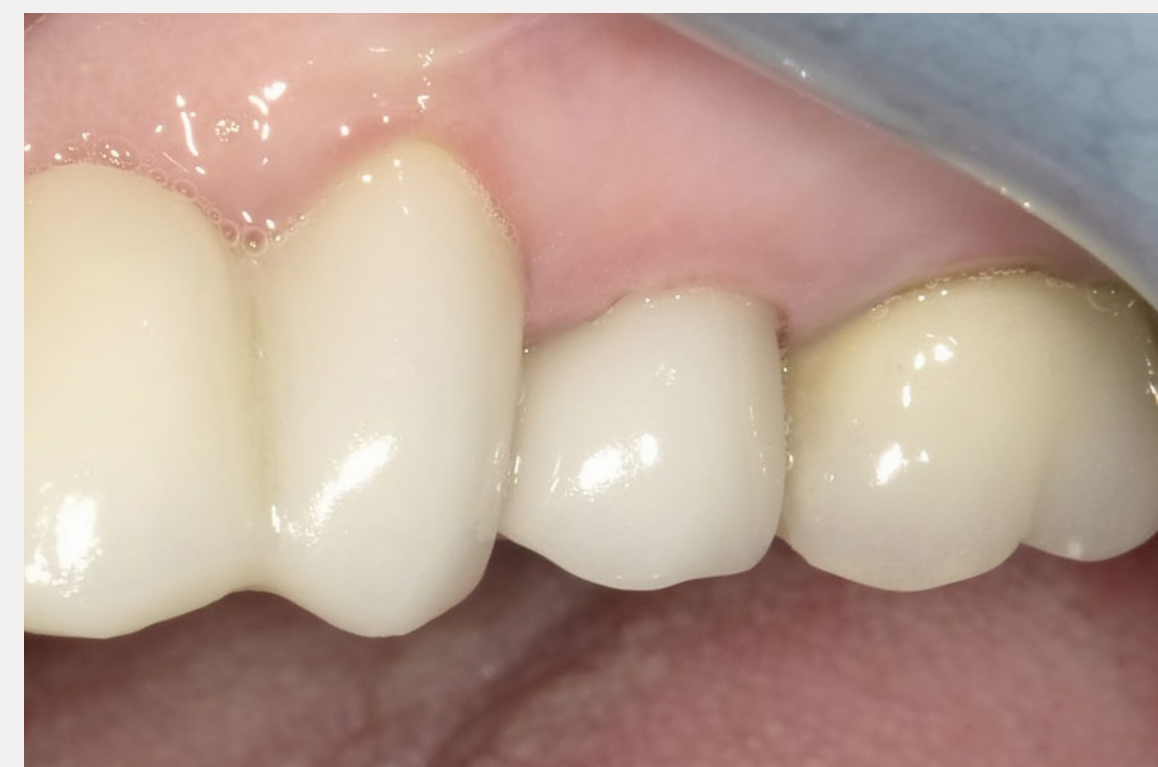The following case refers to a 71-year-old female patient. She was diagnosed with mesial and distal marginal caries on tooth 25. The ceramic veneer of the PFM crown was partially broken. The treatment plan was to restore the tooth with an all-ceramic crown (IPS e.max CAD, Ivoclar Vivadent) after caries removal. The aim was to create a better facial and incisal fit for the crown into the dental arch as well as to match the fixed prosthetic structures at the front in a more visually pleasing way by using the B1 shade. The patient received local infiltration anesthesia. This was followed by a scan with CEREC Primescan of the maxilla and mandible, and bite registration. The existing crown was to serve as a reference for the new restoration. After removal of the defective crown, the tooth was prepared and then scanned again. The crown designed with the Biocopy mode was then fabricated directly in the CEREC Primemill. The fast grinding mode for IPS e.max CAD was used, which enabled the restoration to be completed in just around seven minutes. Immediately after grinding, the crown was tried on the patient. Following incisal staining for greater translucency and glazing, crystallization was done in the sintering furnace. This process took approximately 20 minutes. The restoration was then cemented with a conventional RMGI cement, with axial and occlusal wall thicknesses of 1,000 microns and 1,500 microns respectively. A postoperative intraoral X-ray (Schick 33 sensors, Sidexis 4) was taken as a final control, confirming the successful restoration of the tooth. Including preparation, fabrication and cementation of the restoration, the treatment took only 57 minutes. The patient was very satisfied with the short treatment time and the pleasing esthetic result.

Discussion

The interesting aspect of this case was the workflow speed. Taking the first scan while anesthesia was taking effect already saved a significant amount of time. With CEREC Primescan, the impression could be taken quickly. Hardly any changes were made to the initial design, so the manufacturing process could be started immediately. Since CEREC Primemill's pre-touch process was already started during design, the fabrication itself took only seven minutes. In addition, conventional cementation with an RMGI cement proved to be timesaving.



Before:
Tooth 25 had mesial and distal marginal decay and broken porcelain on the existing PFM.




After:
The crown on tooth 25 was remade to be brought more in line facially and incisally with the arch.



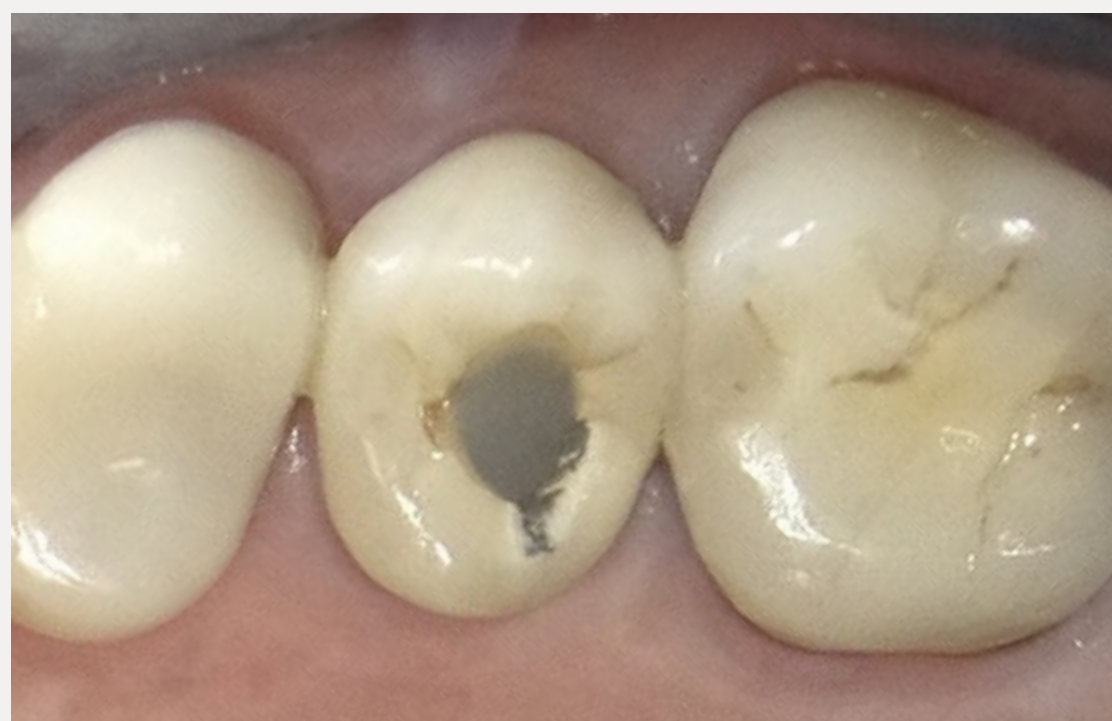

An IPS e.max CAD single crown – Second upper premolar in 60 minutes

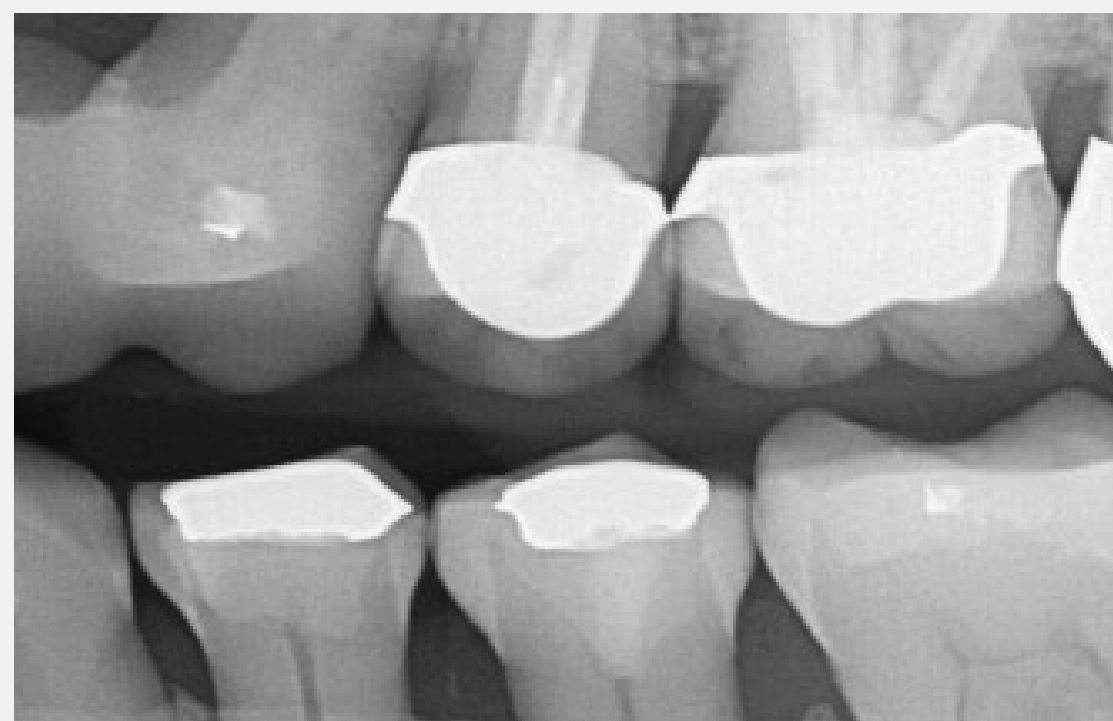

Dr. Frank Clark Brown
Melbourne, USA

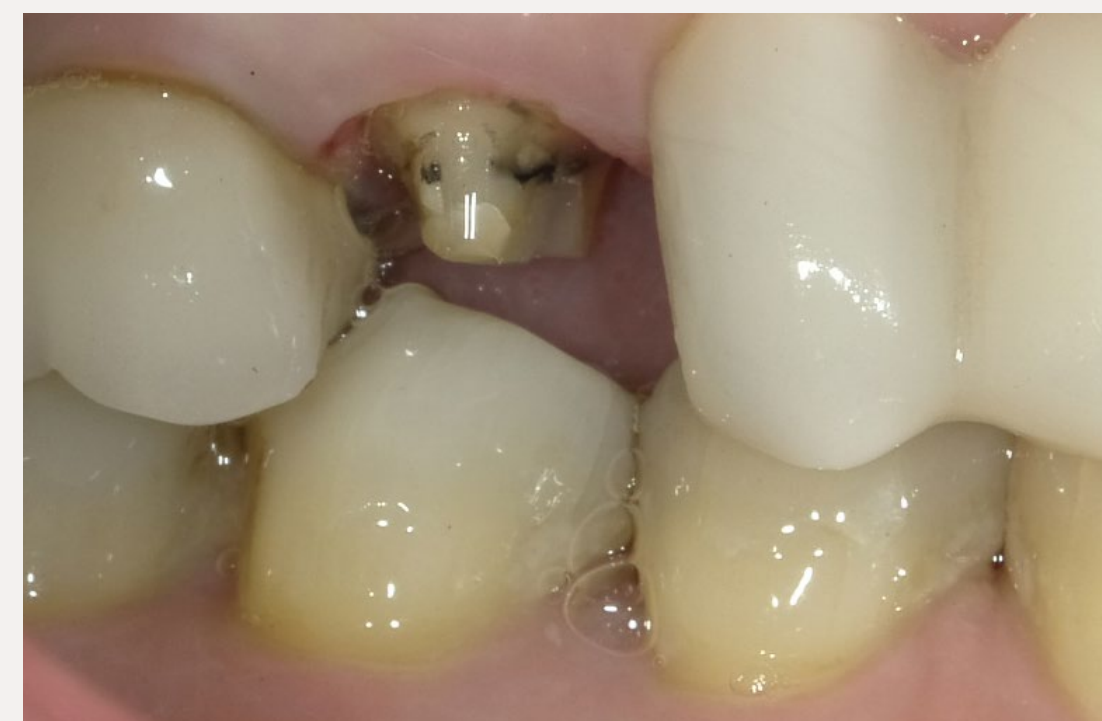Clinical Images



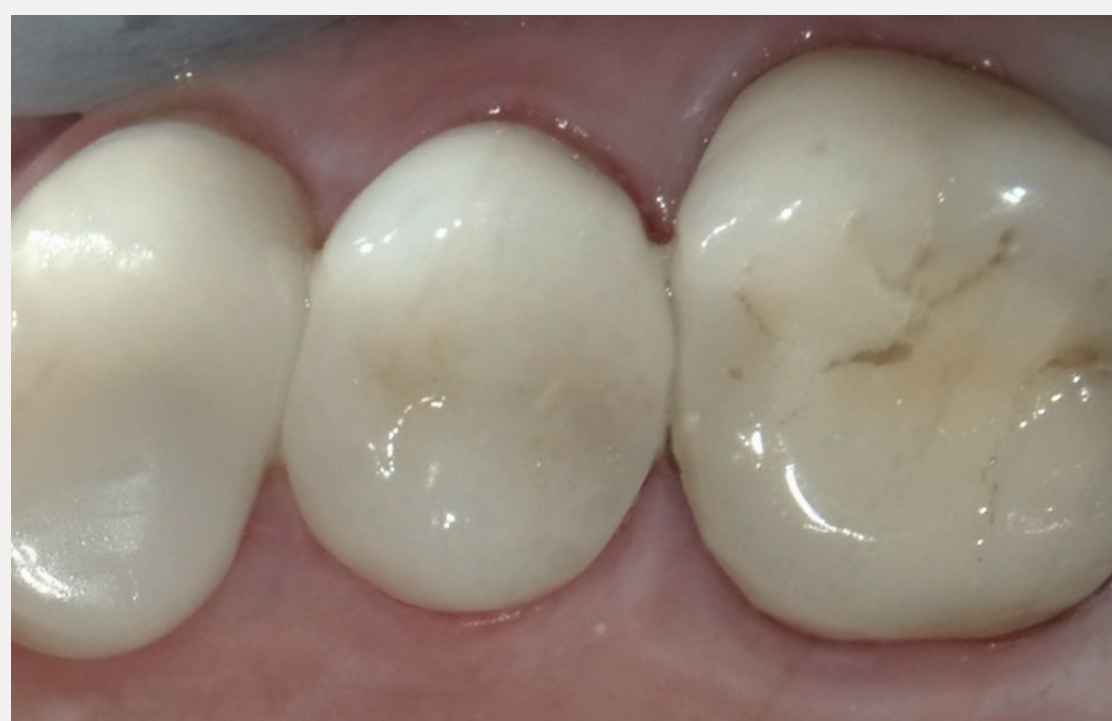Preoperative occlusal view.



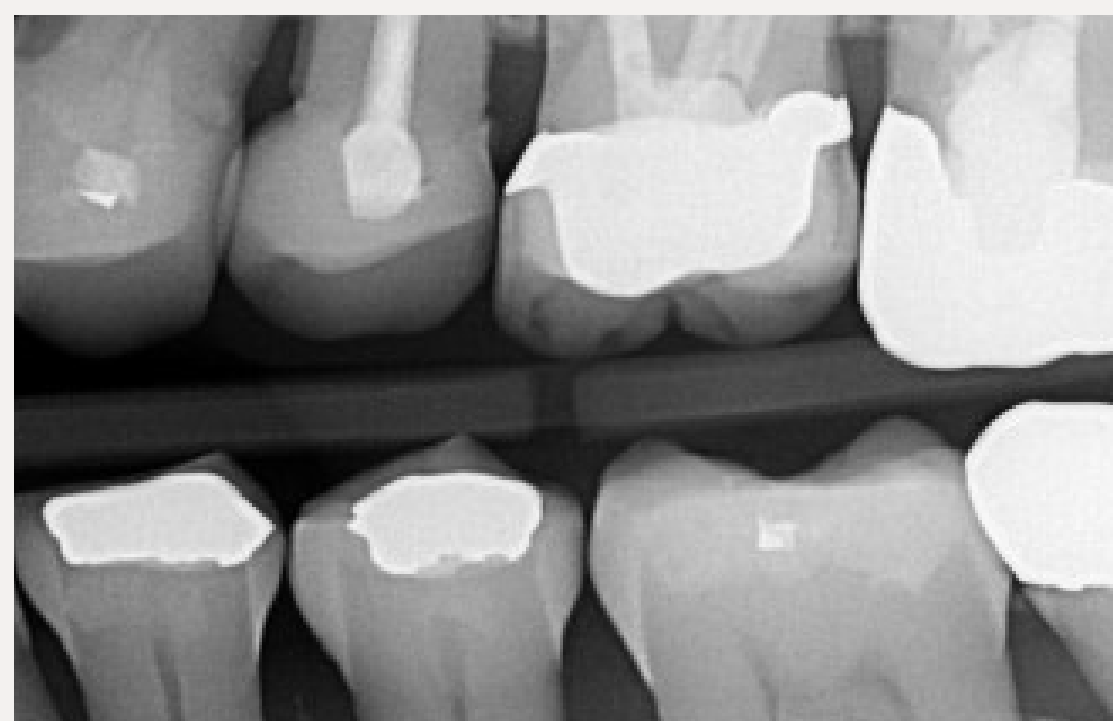Preoperative X-ray.



Lateral view of the preparation.




Postoperative occlusal view of finished crown.



Postoperative X-ray.

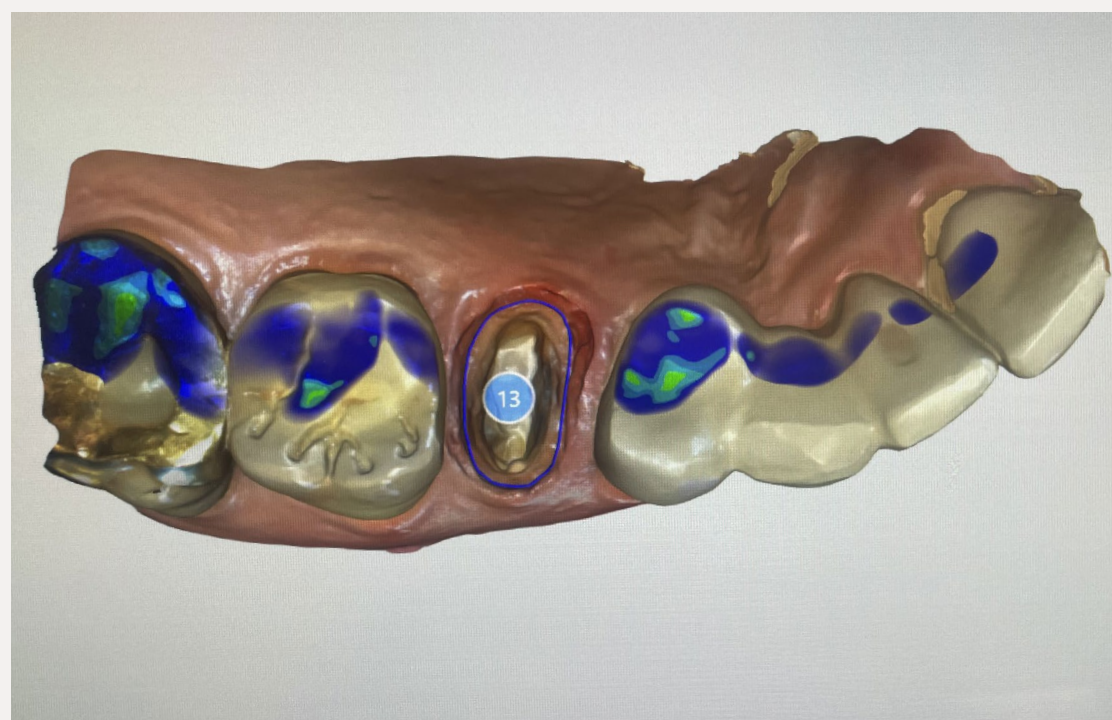


An IPS e.max CAD single crown – Second upper premolar in 60 minutes

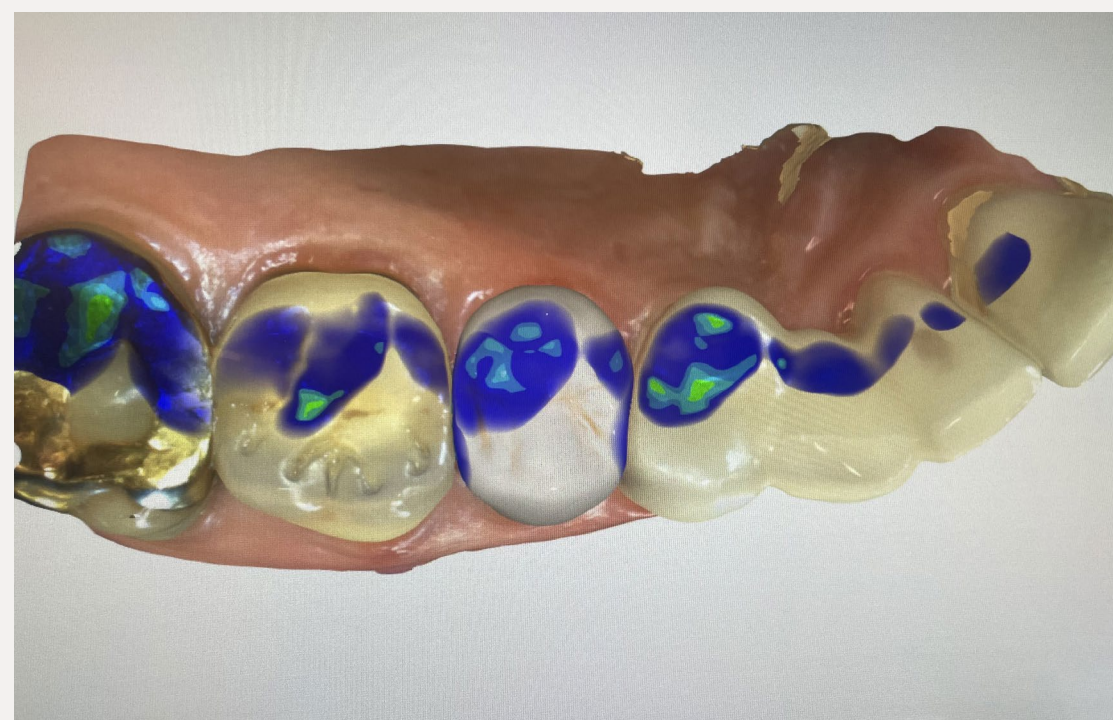


Dr. Frank Clark Brown
Melbourne, USA

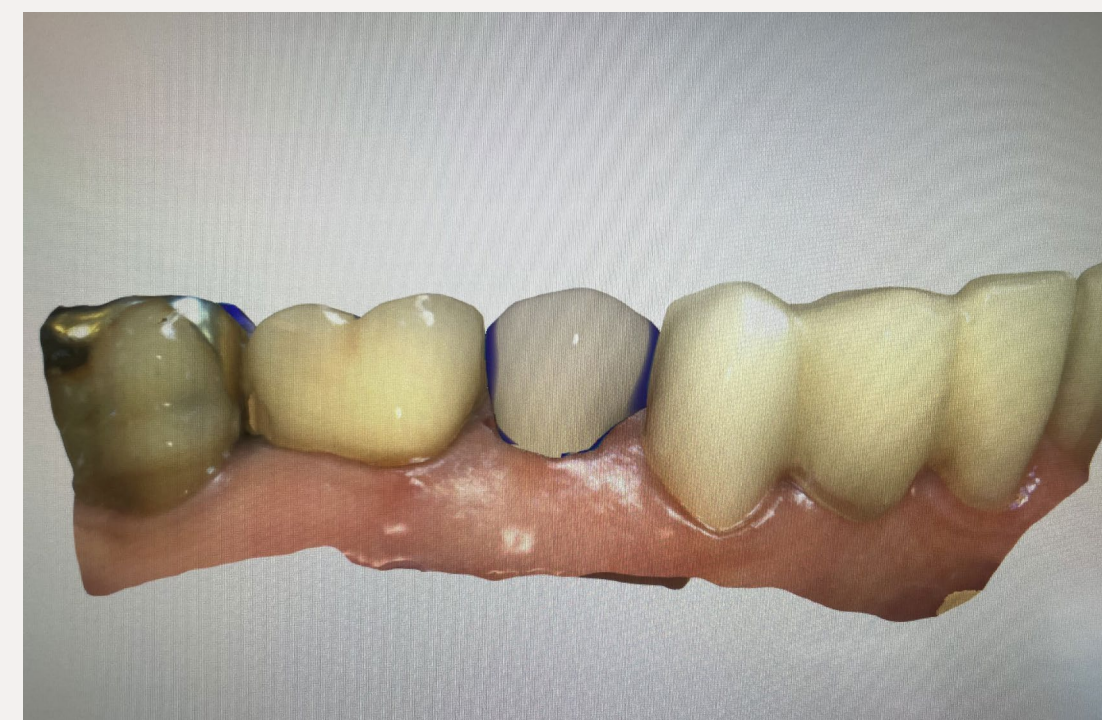Workflow Images



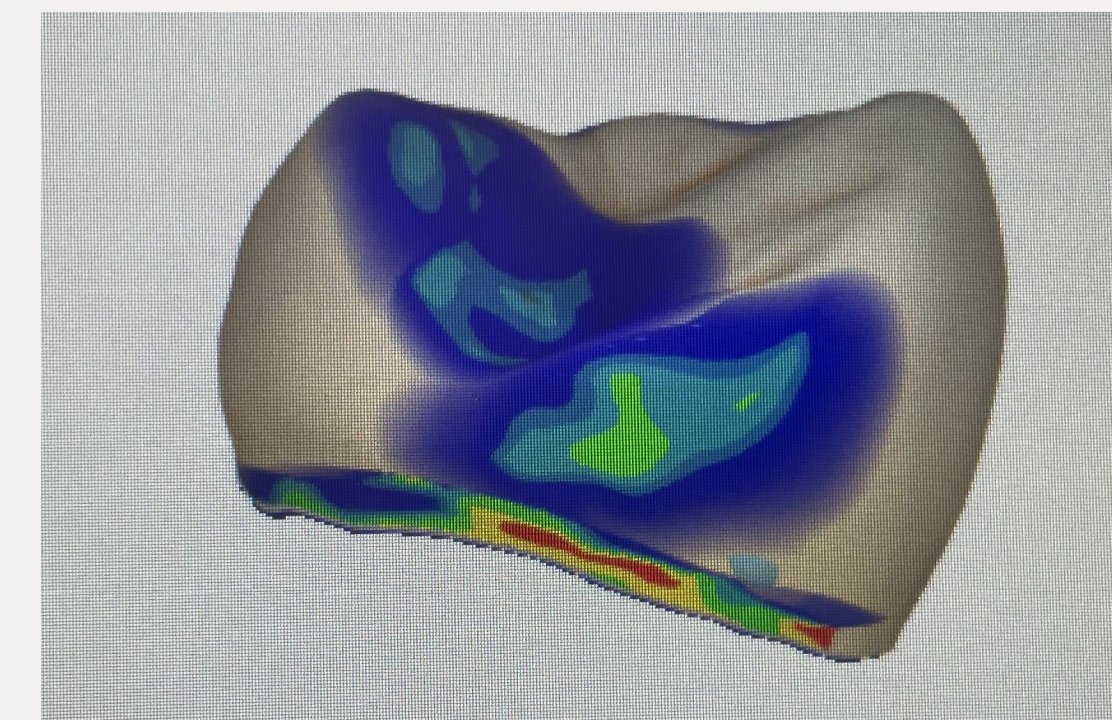
First proposal of the prep margin shows high level of accuracy.



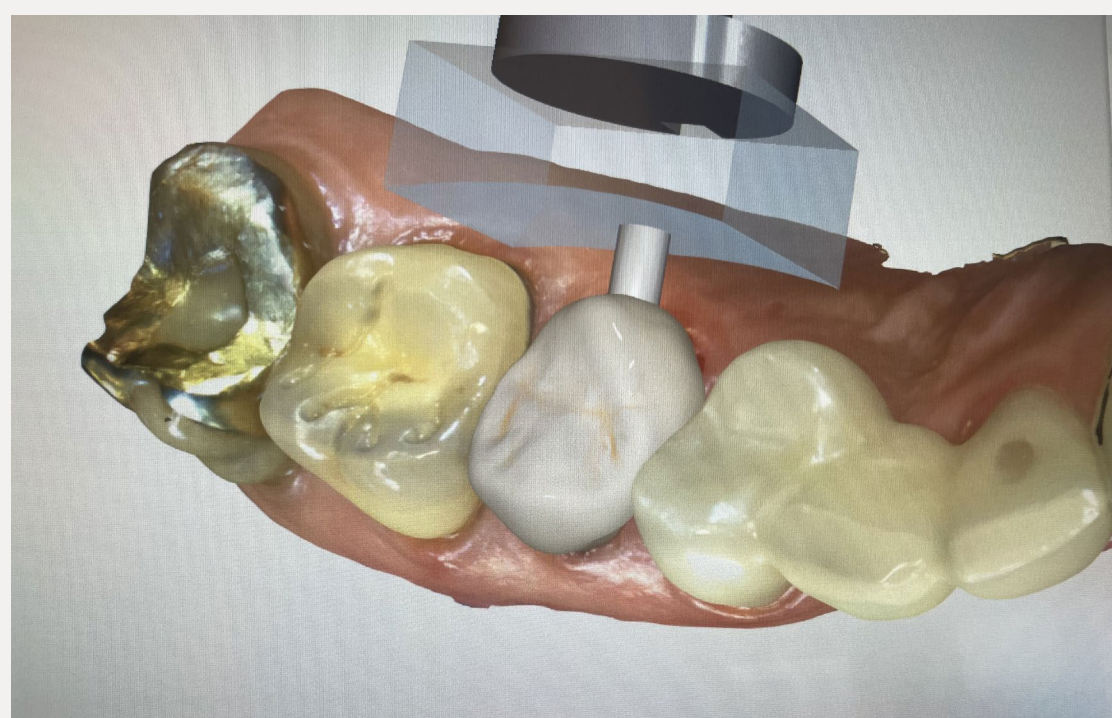Design proposal in the CEREC SW. Minor modifications were made, which involved making a broader contact both mesially and distally.



Examination of the design from different angles ensures that there is proper facial alignment.



Checking contacts to ensure that they meet my desired configuration.



Demonstration of the crown and sprue position in the block (Manufacture phase).



An IPS e.max CAD single crown – First upper molar in 60 minutes



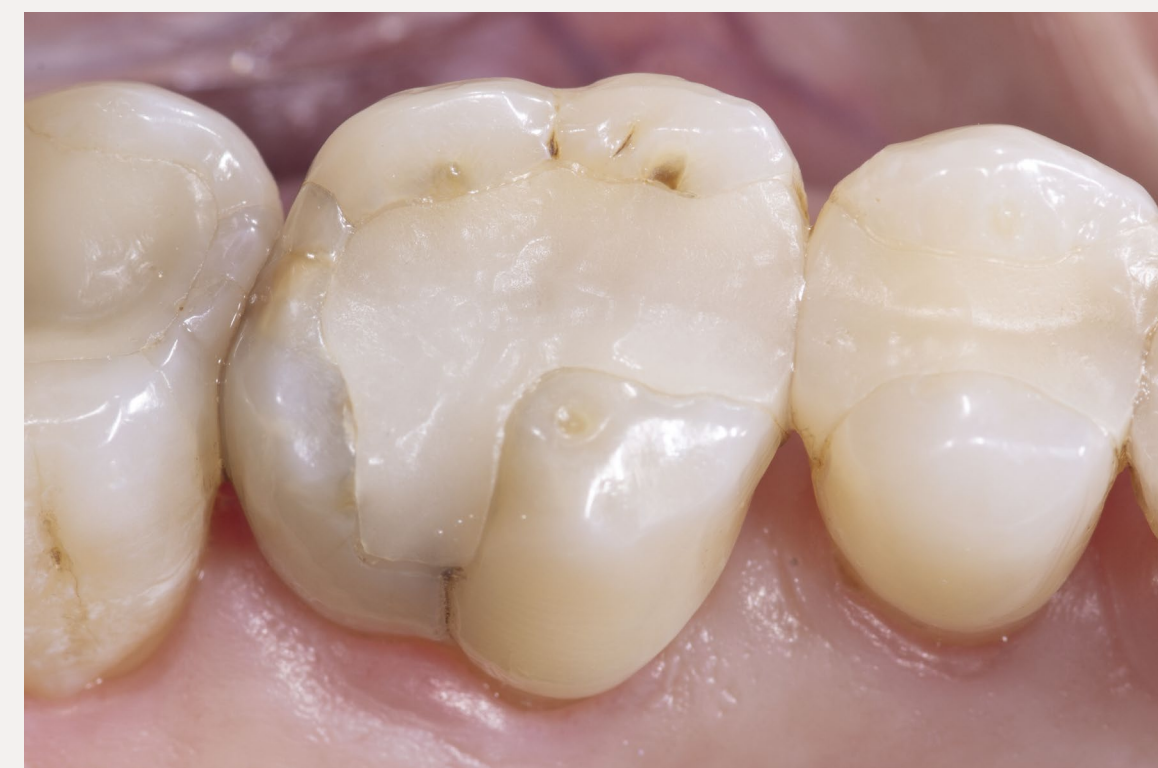Dr. Karyn M. Halpern DMD, MS
New York, USA

Case Description

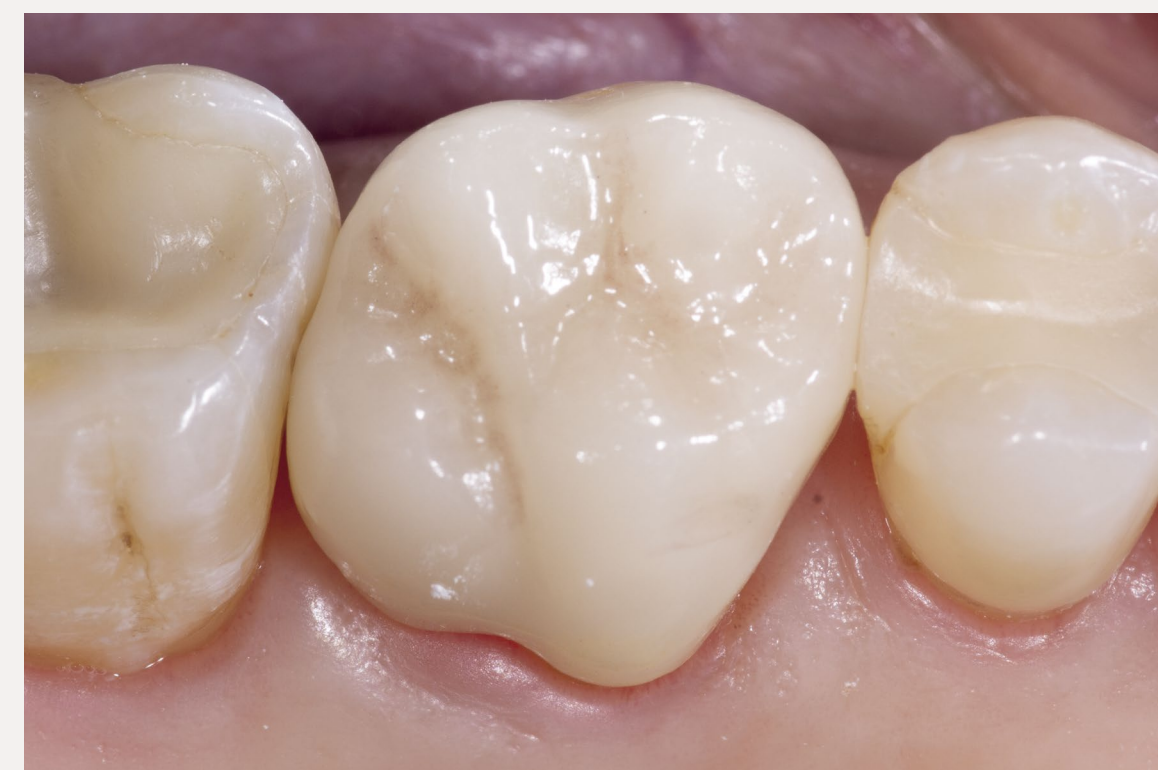A female patient, 47 years old, presented with a slightly intermittent sensitivity to cold at tooth 16. The clinical examination as well as the radiological findings indicated a large insufficiency of the composite filling, with distal marginal ridge cracks, a lingual wall crack, and distal recurrent decay. The tooth was not sensitive either to percussion or palpation, and showed no signs of apical inflammation. A cracked tooth syndrome was diagnosed. Due to the size of the filling and the caries to be treated, a core buildup and a full cuspal coverage ceramic crown restoration was planned. After local anesthesia with 4% Septocaine® (1:100,000 epi), we selected the material and the color for the restoration: IPS e.max CAD MT A3. Prior to the preparation and design of the new restoration, my assistant prepared the CEREC Primemill by inserting the block and starting the pre-touch process. After the initial scan of the upper and lower jaw with CEREC Primescan, I removed the filling. This confirmed the initial diagnosis of a fracture in the lingual wall. Following the excavation, I applied a composite core buildup (3M Vitrebond, Empress Opaque, Ivoclar Vivadent). In this case, I was able to complete the preparation in a way that the enamel was retained in the buccal wall. Subsequently, I took a new digital impression with the CEREC Primescan. I then defined the preparation line in the digital model. The CEREC Software provides excellent support in this respect. I was satisfied with the first restoration proposal, which I accepted without any changes. During the design phase, I paid particular attention to the fissure height and contours, the correct occlusion, and the contact points. After grinding with CEREC Primemill, I crystallized and glazed the crown. I performed a quick final check and could place the crown using adhesive. The patient was very happy with her experience and grateful for being able to have her tooth restored with a permanent, strong, and highly esthetic crown in a single visit that took just over an hour. Since then, she has been completely free of symptoms.

Discussion

The clinical case demonstrates how quickly and efficiently the new CEREC Primemill allows a full-surface glass-ceramic crown to be fabricated chairside in a single session, while meeting a high level of esthetic demands. I can no longer imagine practicing without CEREC Primemill.



Before:
Large insufficiency of the composite filling on tooth 16 with distal marginal ridge cracks, a lingual wall crack, and distal recurrent decay.



After:
Highly esthetic full-surface glass-ceramic crown.



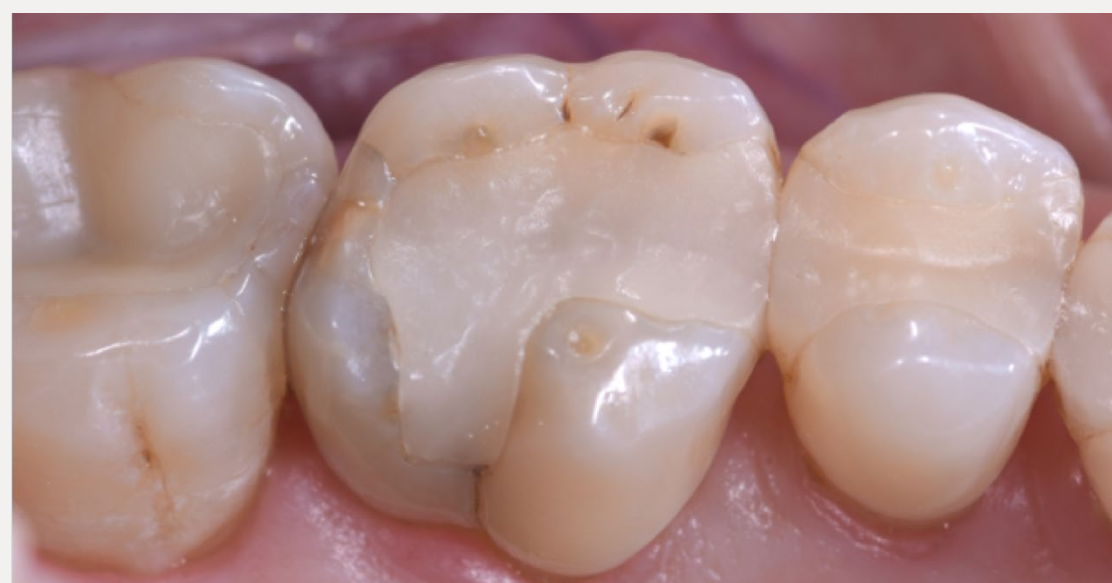

An IPS e.max CAD single crown – First upper molar in 60 minutes

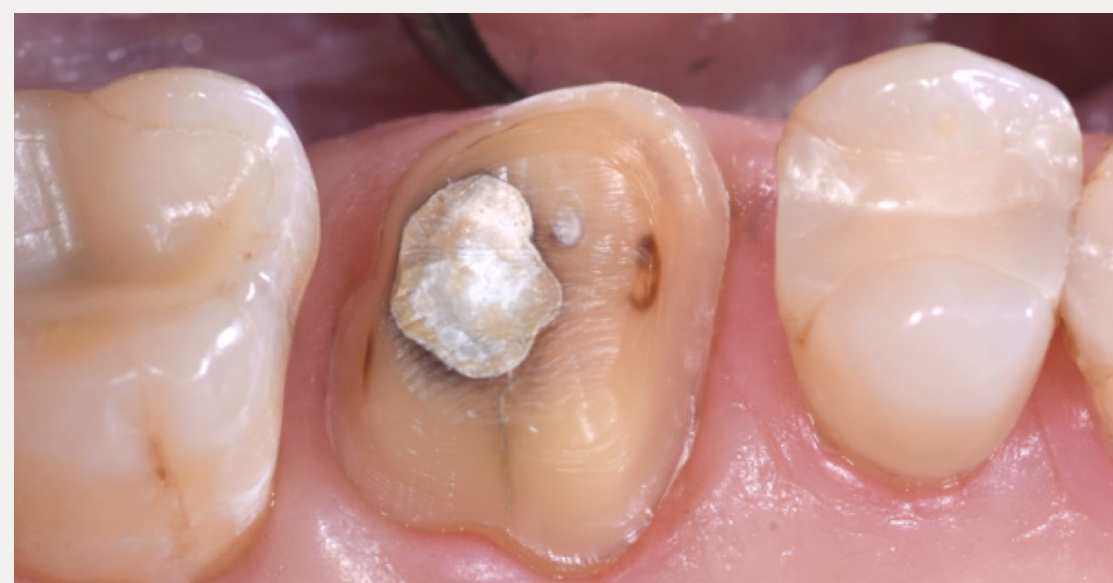

Dr. Karyn M. Halpern DMD, MS
New York, USA

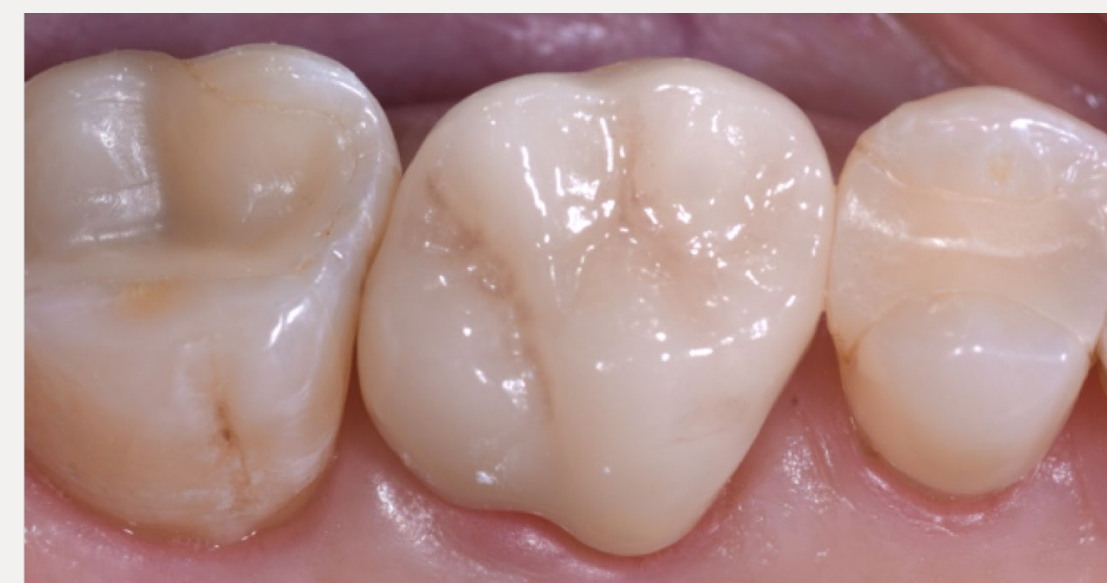Clinical Images



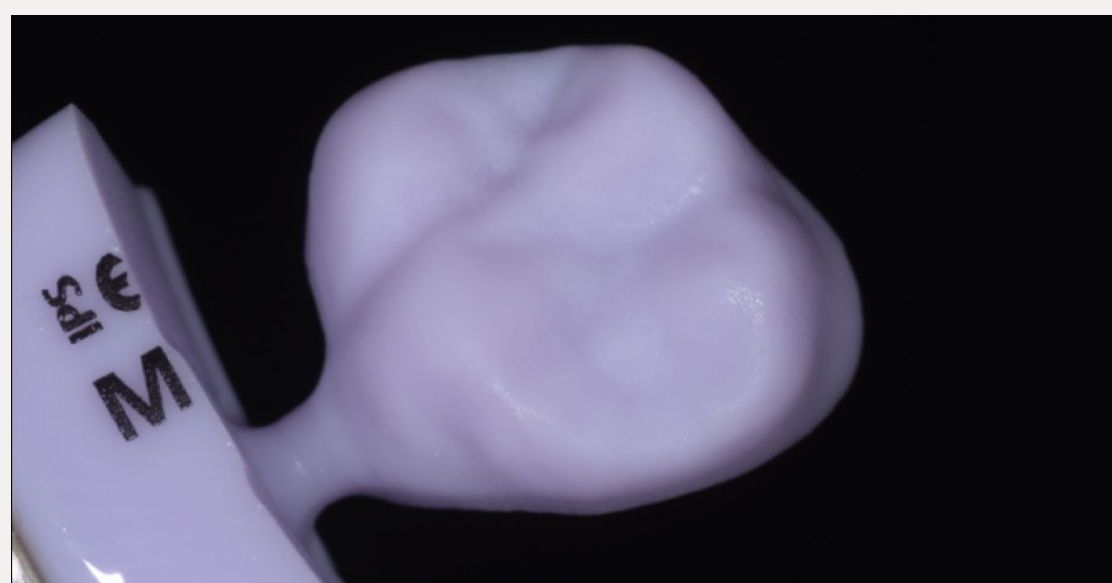The patient presented with a chief complaint of mild intermittent sensitivity to cold beverages and pointed to tooth 16.



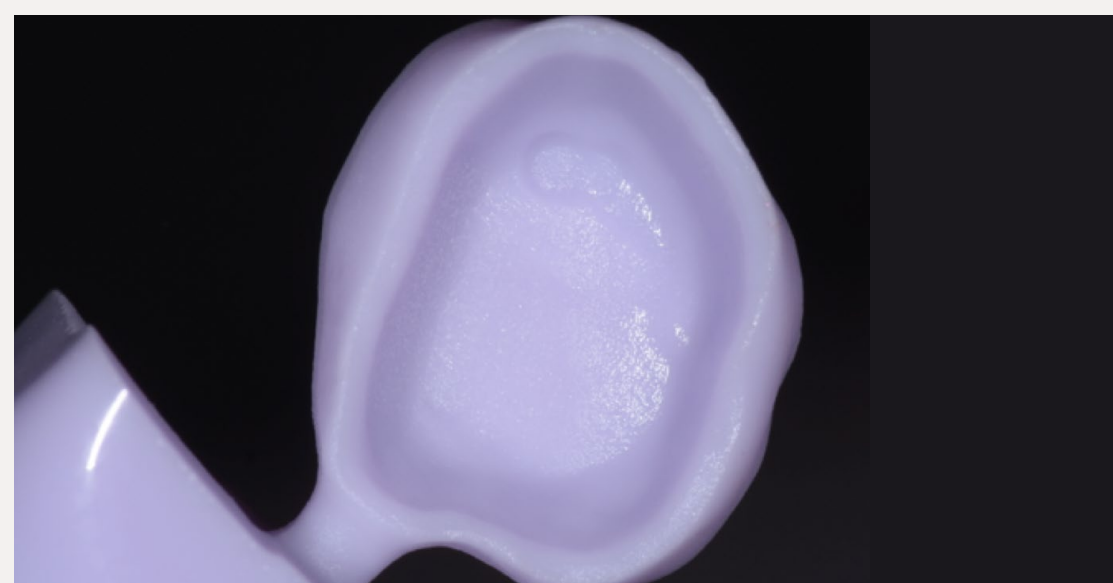The previous failing restoration was removed, and both mesial and distal recurrent decay was found and excavated. No pulp was exposed upon completed excavation. A composite core buildup was completed using a glass ionomer liner (3M Vitrebond) and composite resin (Empress Opaque, Ivoclar Vivadent).



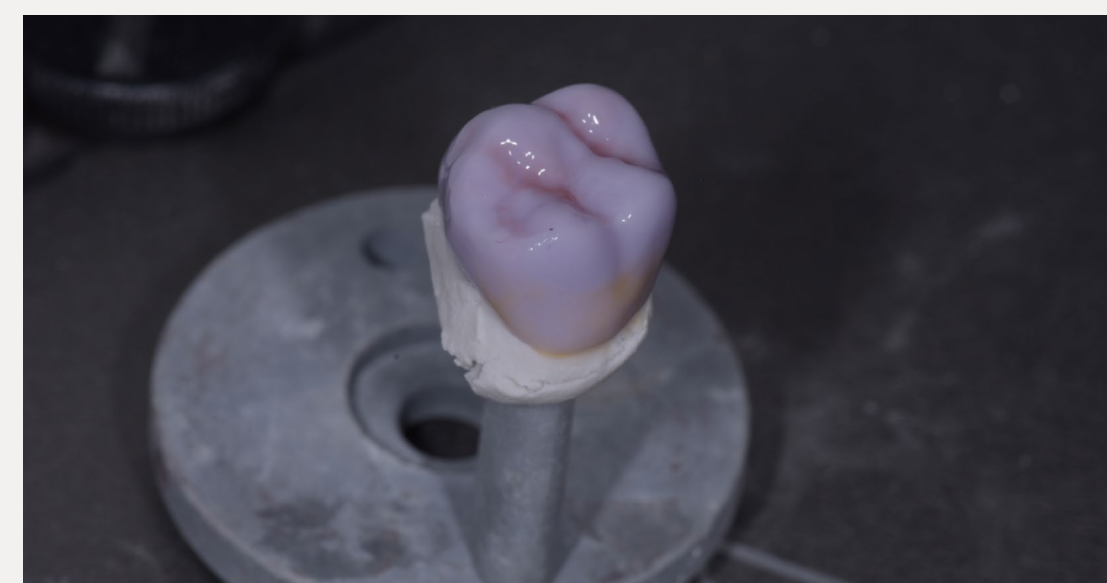After crystallizing and stream cleaning the restoration, the e.max CAD was prepared for bonding and bonded with resin cement.



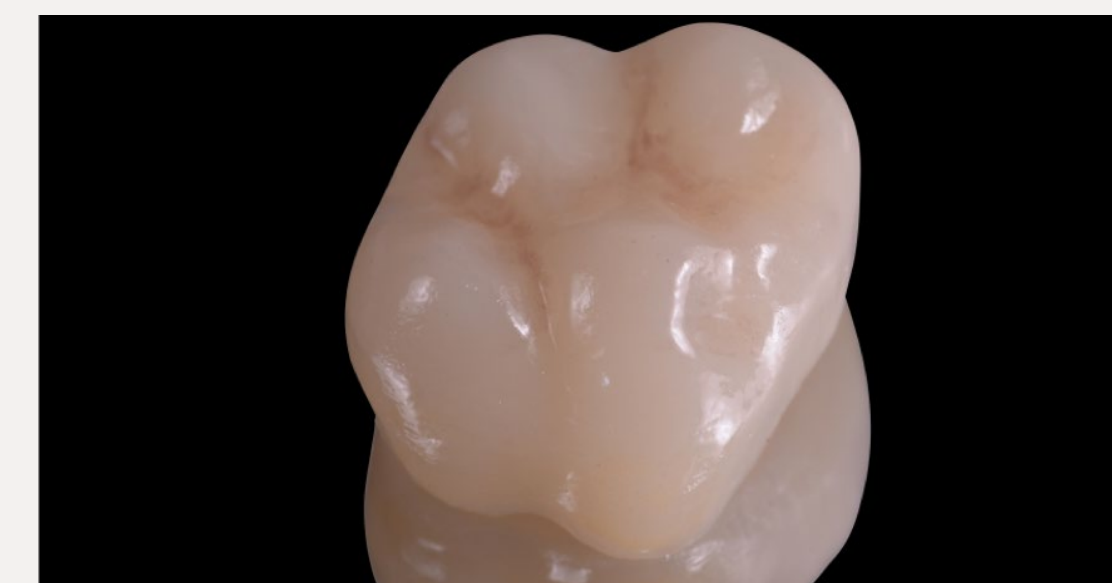The local parameter marginal thickness was adjusted to 100 µm. The design phase was then completed with very little modification to the fissure height and contours. The design was evaluated for proper occlusion, contacts and contours.



Since the touch process had been completed in advance, the grinding began right away after the restoration was sent to the CEREC Primemill. The e.max restoration was grinded in 3:54 without any marginal chipping. The fit was checked, and no further adjustments were needed.



The restoration was then glazed and stained using Ivoclar Vivadent IPS e.max CAD Crystall Shades, Stains and Glaze Paste.



It was then crystallized in a furnace.

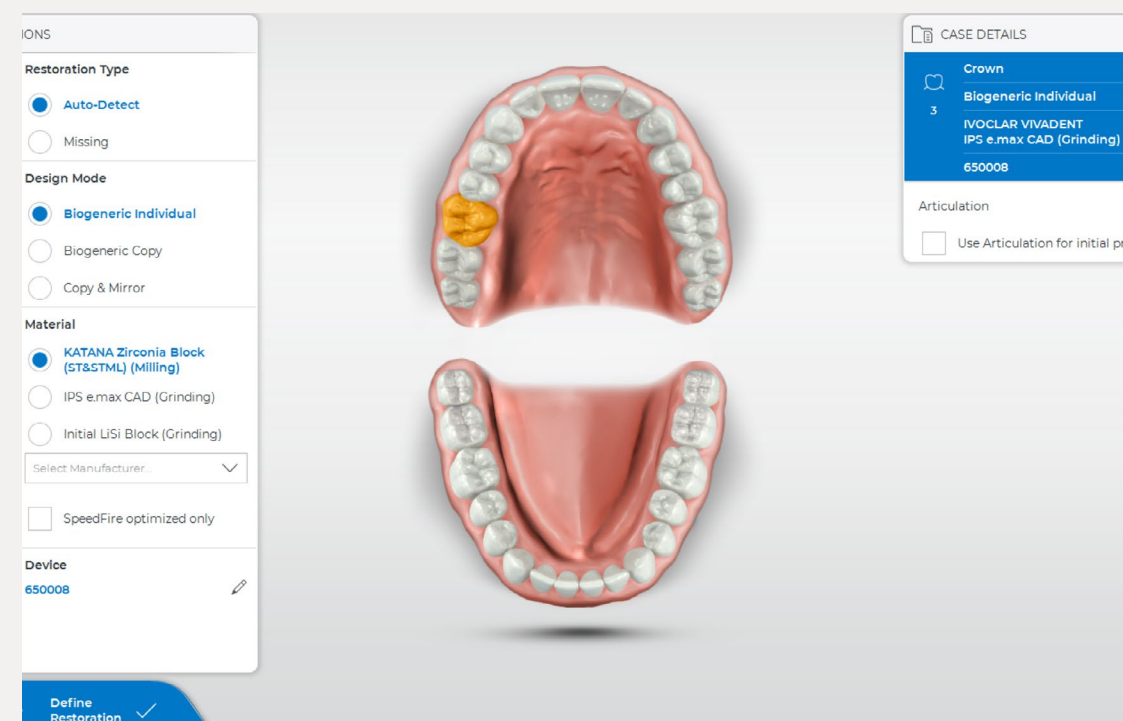


An IPS e.max CAD single crown – First upper molar in 60 minutes

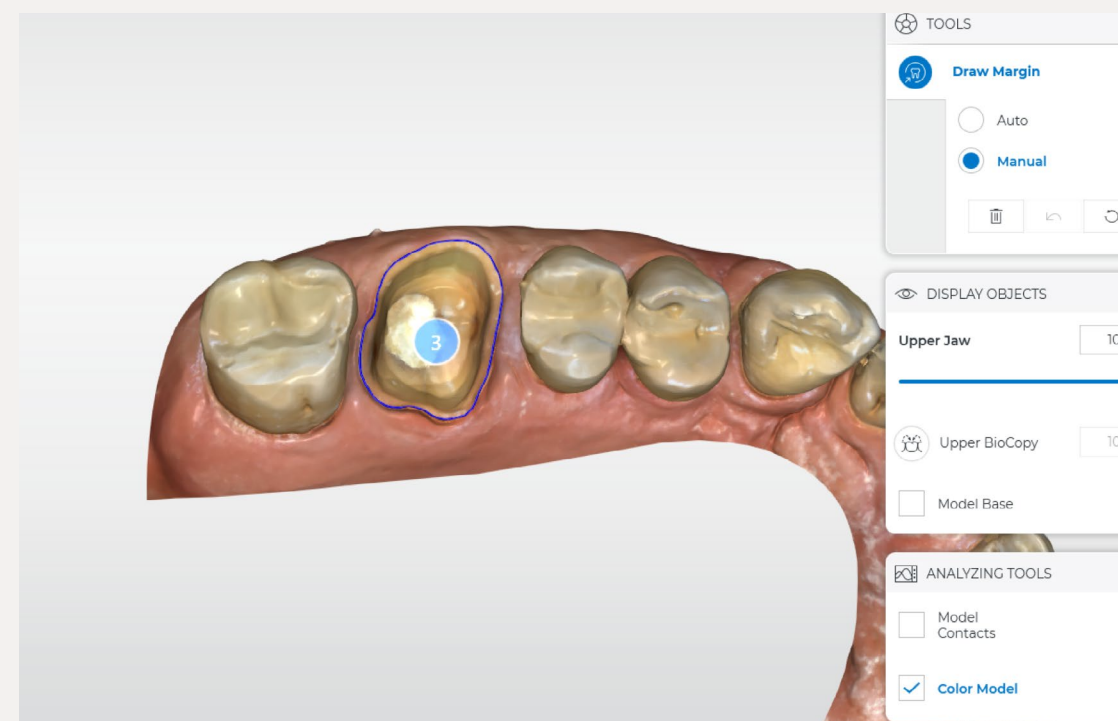


Dr. Karyn M. Halpern DMD, MS
New York, USA

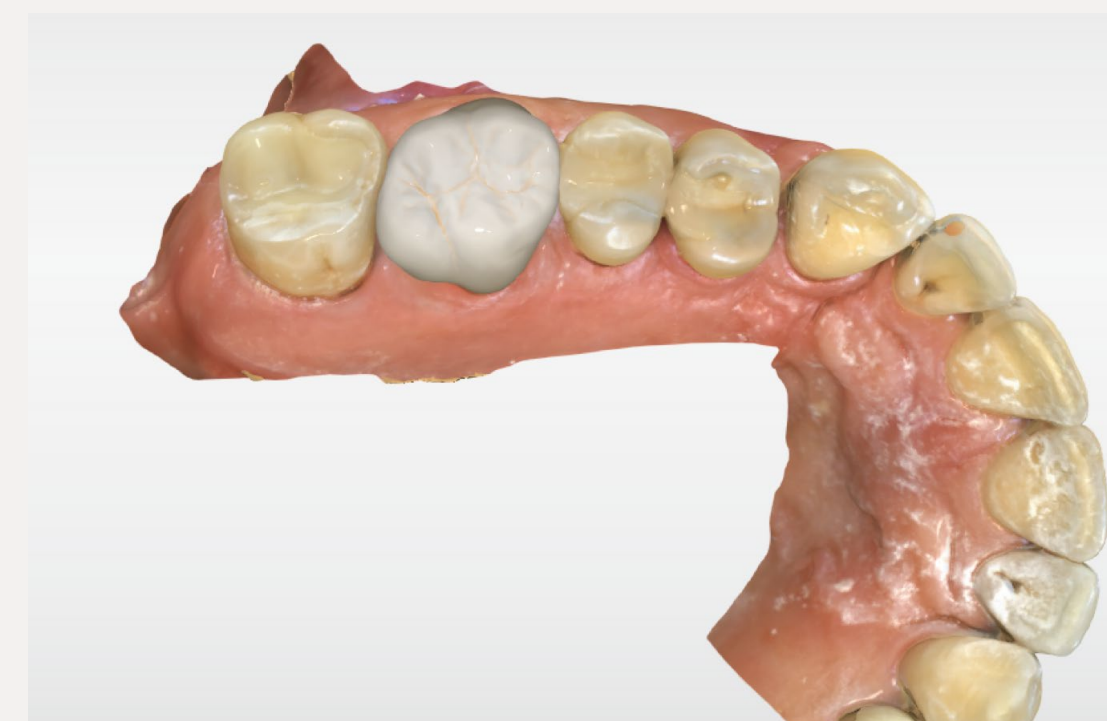Workflow Images



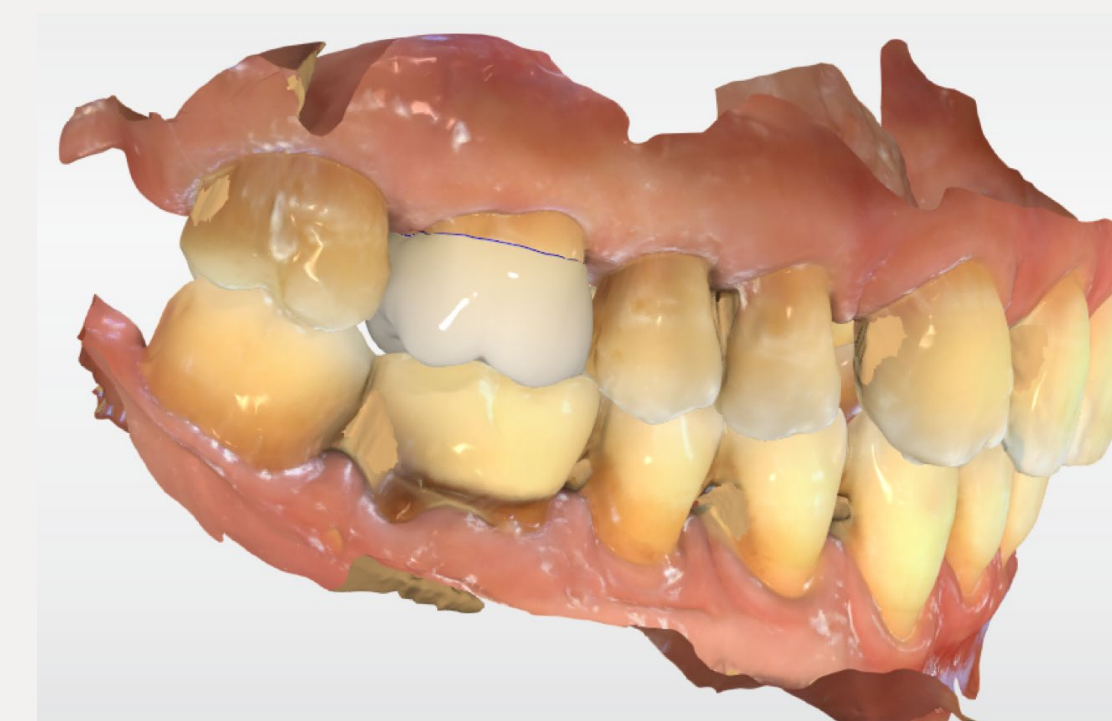The patient information and the Administration Phase was completed, designating IPS e.max CAD for the restoration.



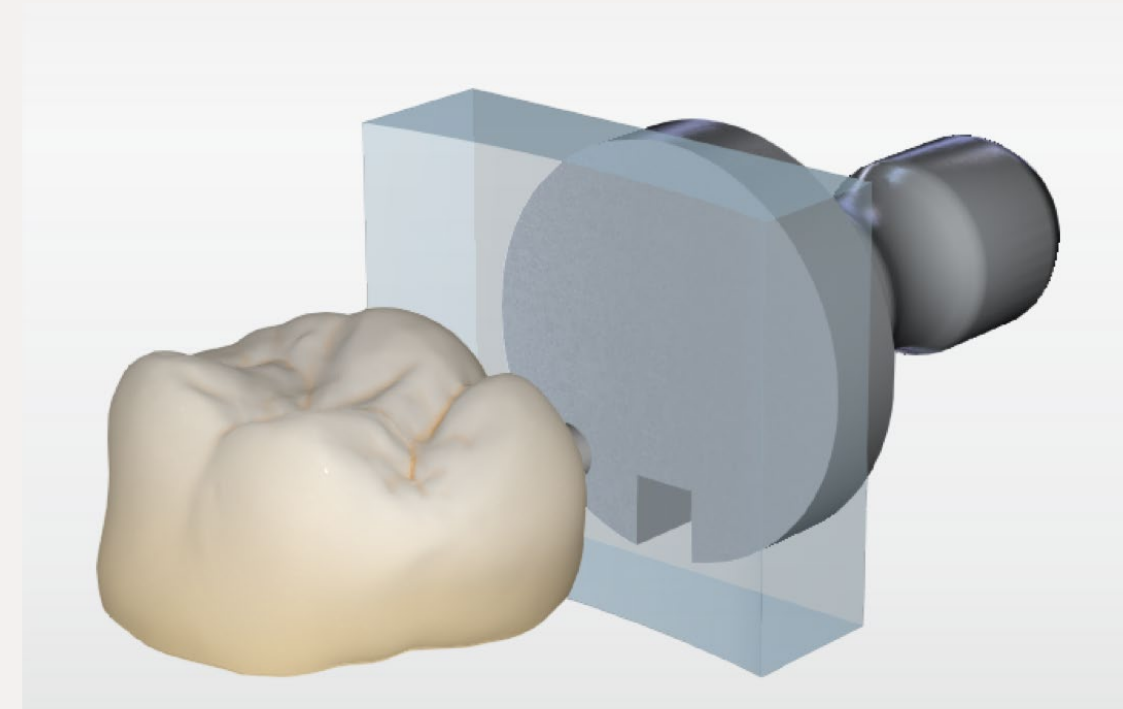
Automargination was completed by the software and no modifications were needed.



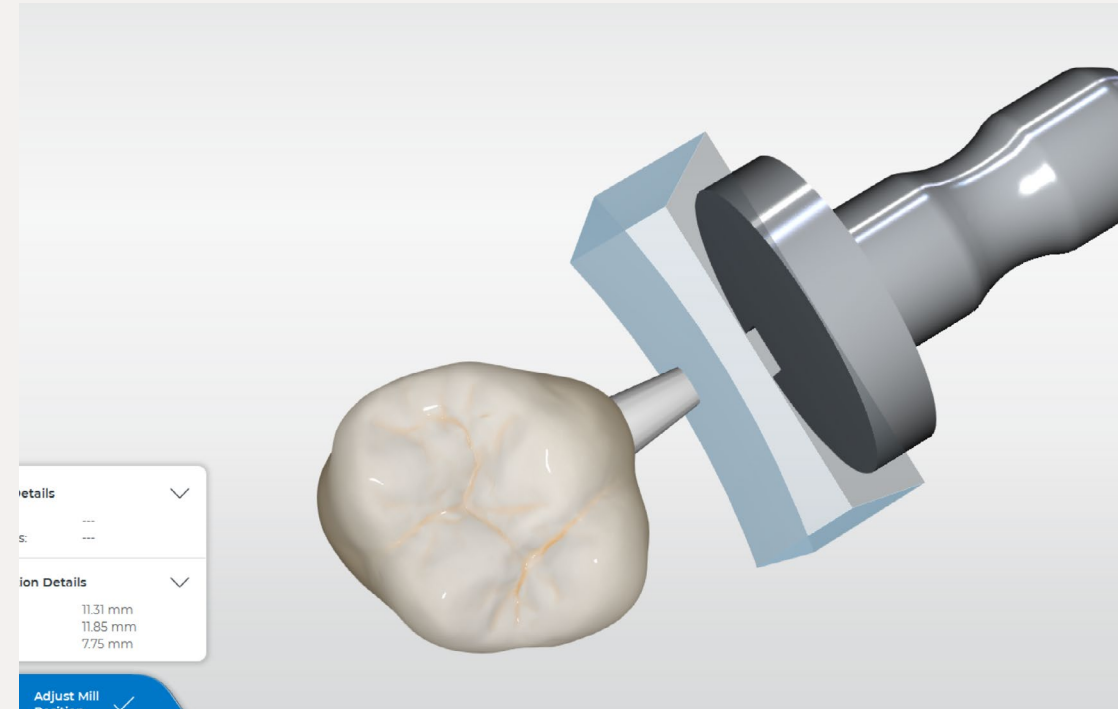
Design proposal.



The design was evaluated for proper positioning, contours, occlusion, and contacts.



In the Manufacture Phase the sprue was automatically proposed on the lingual surface.



The restoration was then sent to the CEREC Primemill.



An IPS e.max CAD single crown – First upper molar in 75 minutes



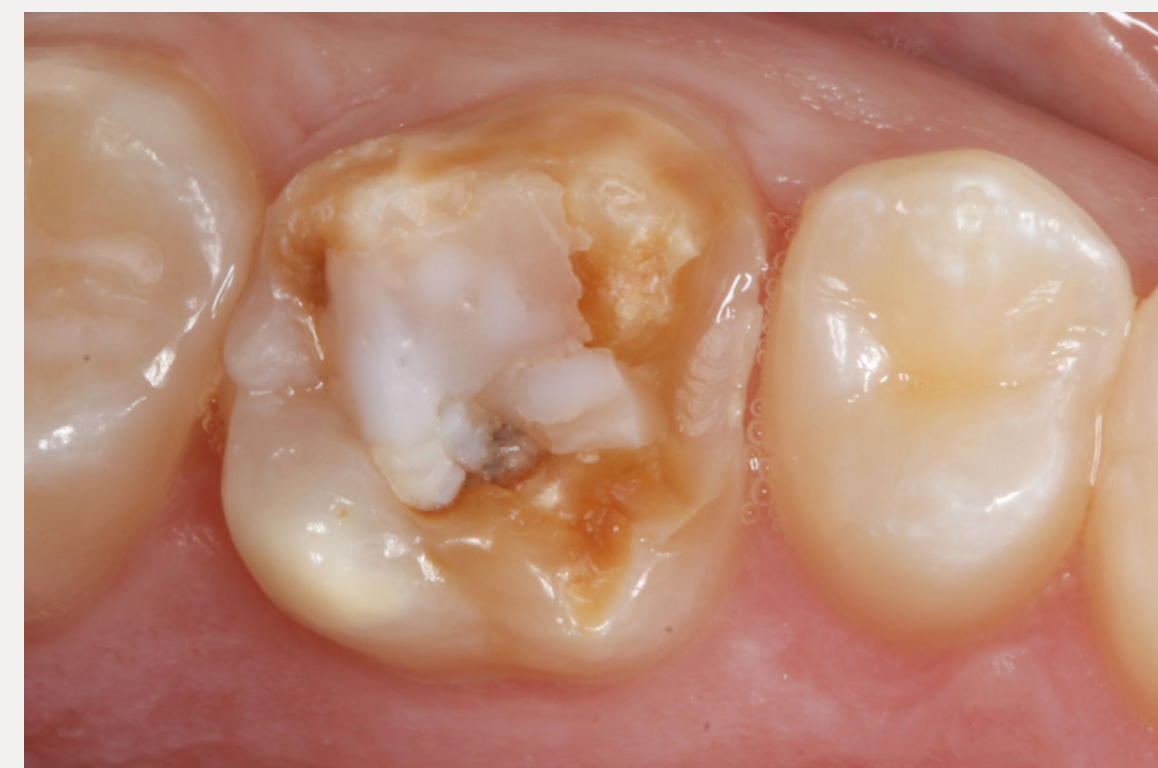Dr. Dan Butterman
Centennial, USA

Case Description

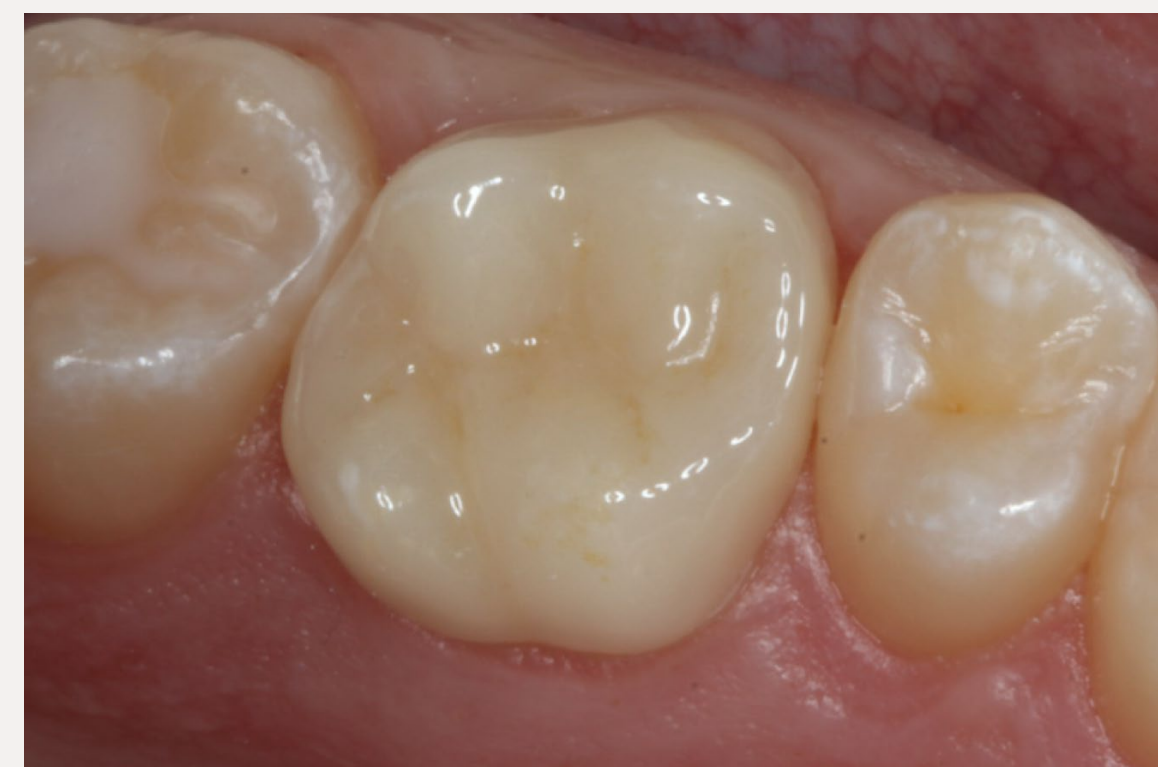A 32-year-old male patient consulted my practice due to decay and a failing direct composite restoration on tooth 26. The treatment plan was to fabricate a full-coverage crown for this tooth in a single visit. After infiltrative administration of anesthesia with Septocaine®, tooth 26 was prepared for a crown. The digital impression was then taken with CEREC Primescan and the crown was designed in CEREC Software. The initial software proposal was very good and the design did not need to be modified. For the crown, we chose an IPS e.max CAD block MT shade A2 size 26. After placing the block in the CEREC Primemill, we initiated the pre-touch process, even though the crown had not yet been designed. The advantage of the pre-touch process is that my assistant can prepare the milling unit while I work in the patient's mouth and the fabrication process can begin as soon as the start button is pressed. With CEREC Primemill, the restoration was completed in a very short time. Due to the pre-touch step and the grinding protocol itself, the entire grinding process has become faster overall. After sintering and glazing in the CEREC SpeedFire, the crown was ready to be fixed with Calibra Ceram. In total, the treatment time was only about 75 minutes.

Discussion

Producing restorations in just one session is now faster than ever before. A quick and very accurate scan, manageable and intuitive design software, combined with a milling and grinding unit that completes a restoration in just a few minutes, makes for a significant increase in efficiency and great patient satisfaction with my practice.



Before:
Tooth 26 presenting decay and a failing direct composite restoration.



After:
Highly esthetic and functional lithium disilicate ceramic crown.

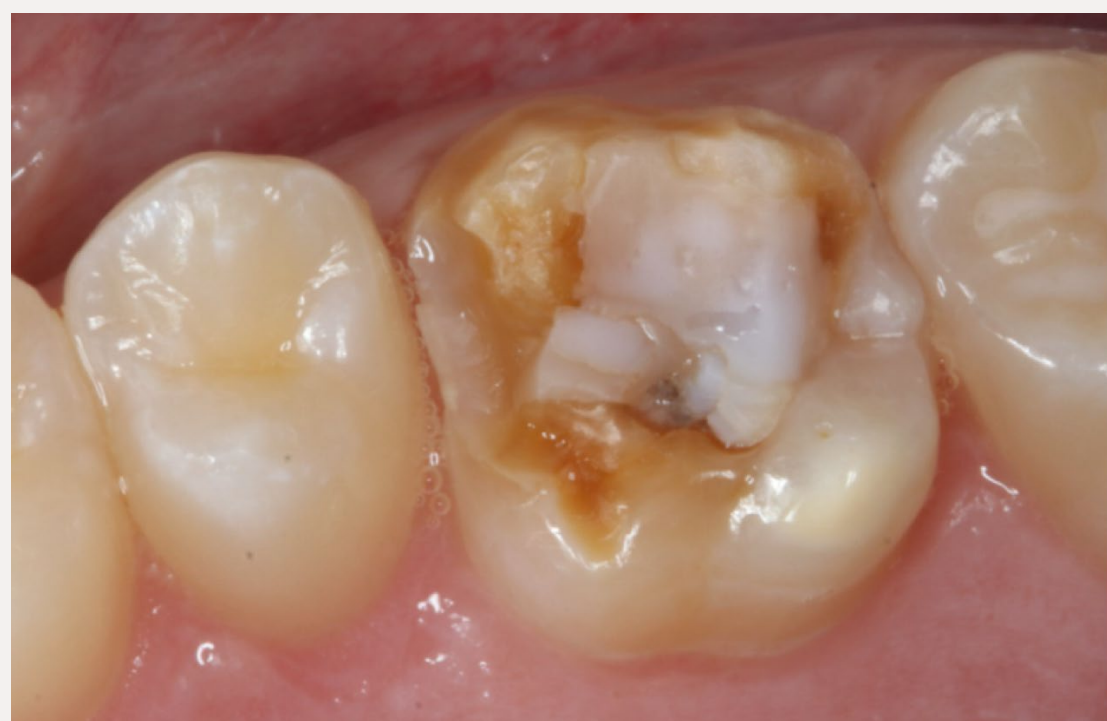

An IPS e.max CAD single crown – First upper molar in 75 minutes

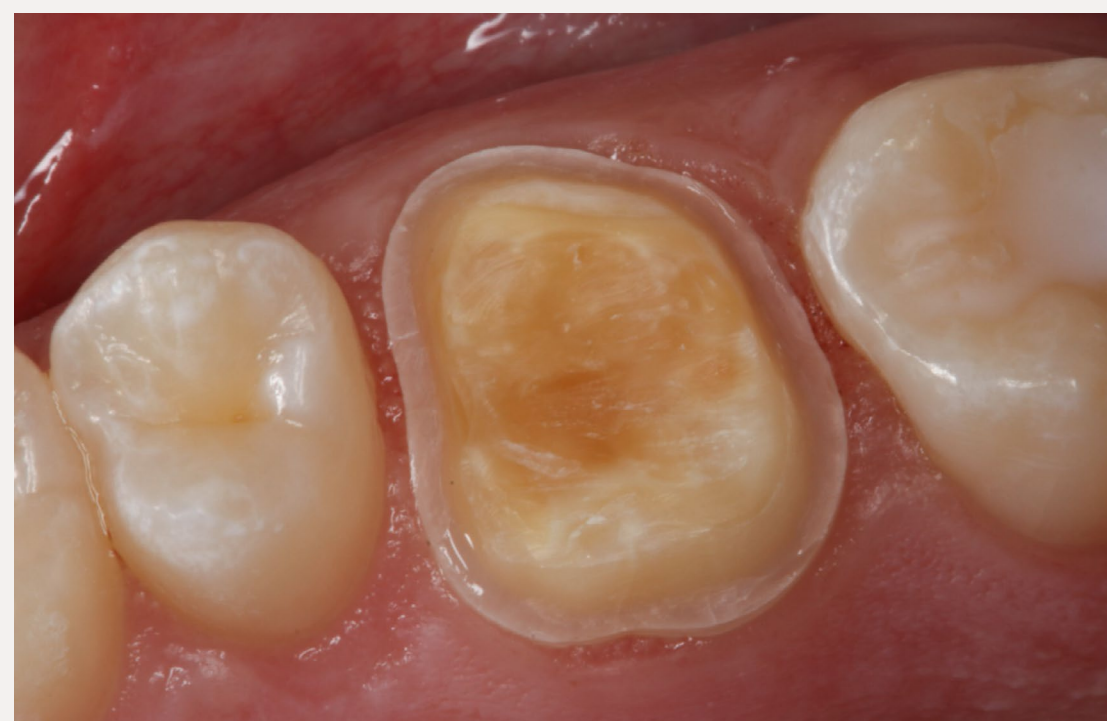

Dr. Dan Butterman
Centennial, USA

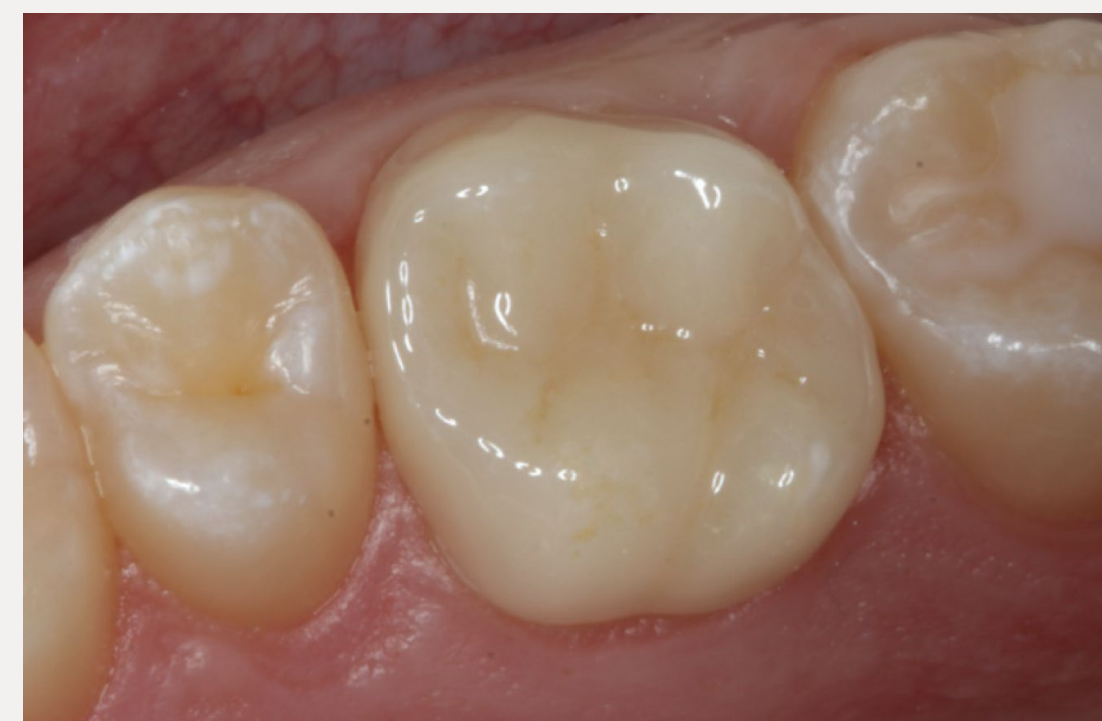Clinical Images



Pre-op tooth 26 with a failing composite restoration and recurrent decay.



The old restorative material and the decay were removed, and the tooth has been prepared for a full-coverage crown.



The final e.max crown bonded in place.

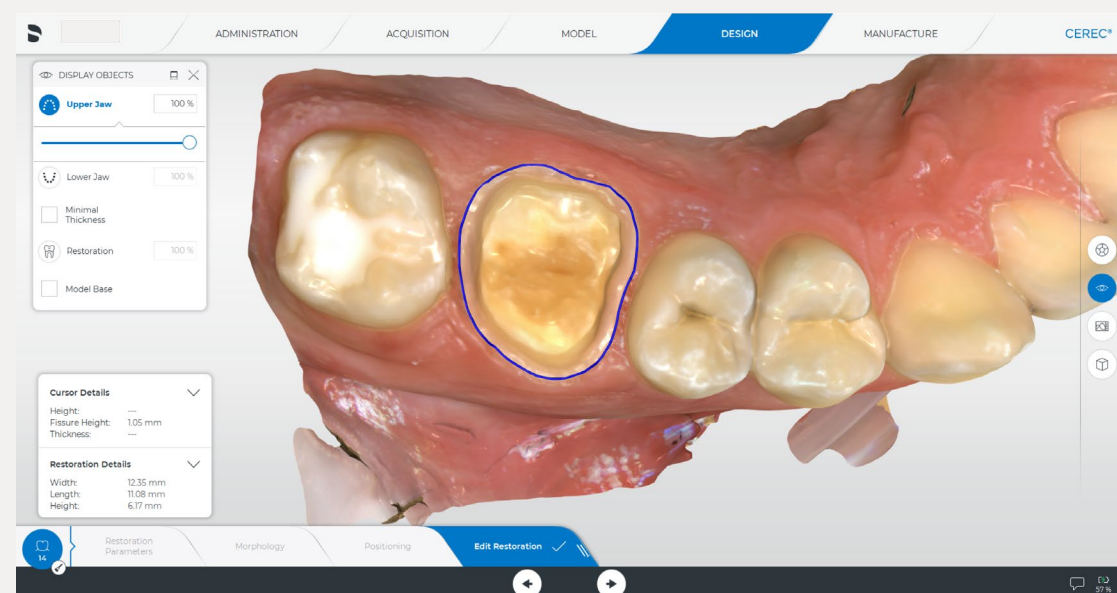


An IPS e.max CAD single crown – First upper molar in 75 minutes

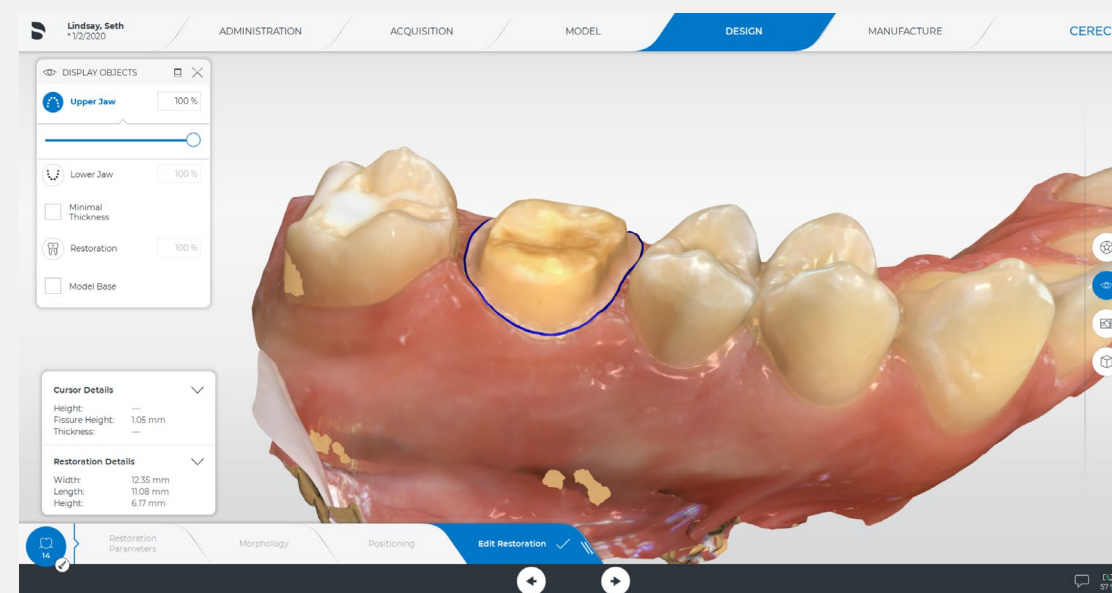


Dr. Dan Butterman
Centennial, USA

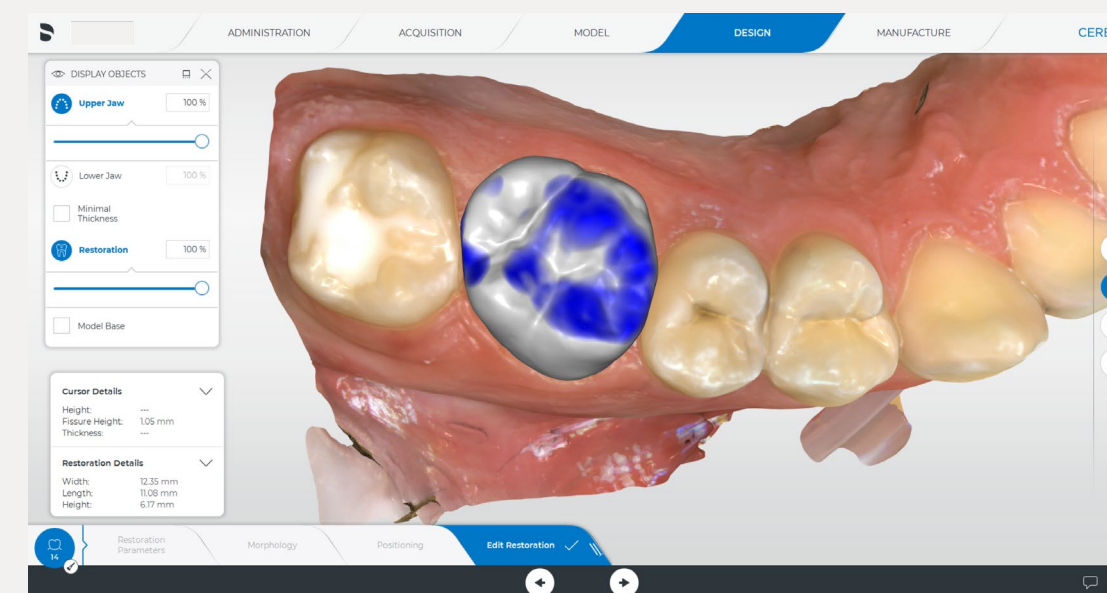
Workflow Images



Top view of the initial model with successful automargination.



Side view of the initial model. The margin did not need to be edited.



The initial crown proposal: no tools needed to be opened to edit this restoration because the initial proposal was perfect.



A Katana Zirconia STML single crown – Second lower premolar in 90 minutes



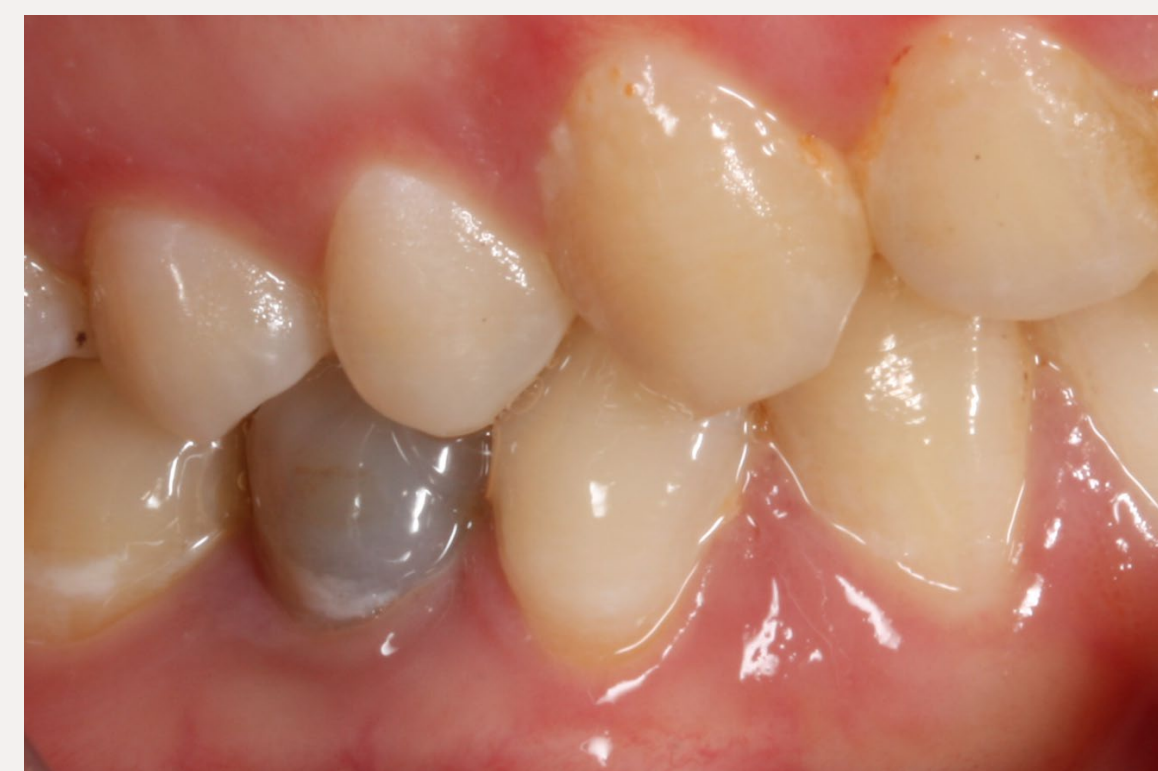Dr. Gertrud Fabel
Munich, Germany

Case Description

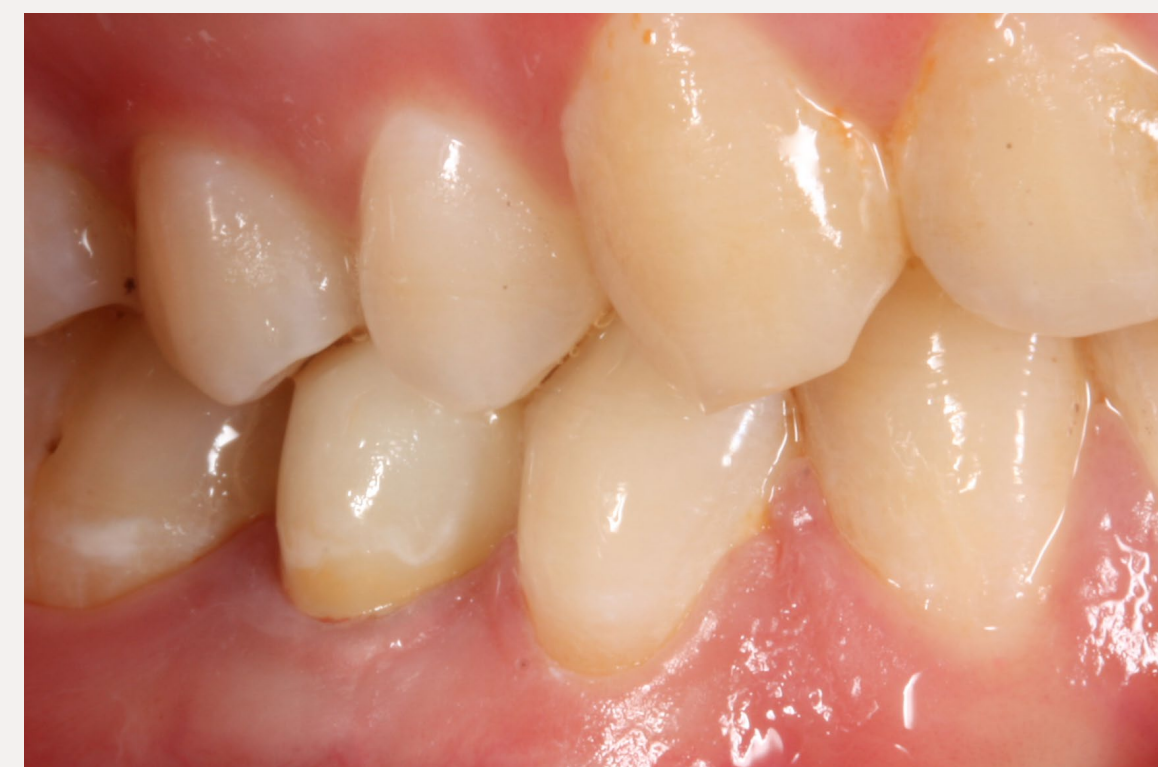A 21-year-old student came to my practice and wanted an esthetic solution for her tooth 45. She reported dissatisfaction with a root canal treatment done elsewhere and was very unhappy about the discoloration of the tooth now, which led to an inconsistent overall impression. For the patient, a temporary restoration was not an option, also for cost reasons. The X-rays, which had to be done because of the risk of a fracture or a trauma, were unremarkable. In order to optimally cover the discoloration, it was necessary to use a slightly translucent material. We decided to use Katana Zirconia STML in shade A3 to perfectly meet the esthetic requirements. The crown was created with the classic CEREC workflow using CEREC Primescan for the digital impression, CEREC Software for the design, and CEREC Primemill for milling the restoration. With the Fast mode the production time was only 8:35 minutes. The try-in of the sintered crown showed a very good fit. Before we permanently seated it with Calibra Cement, we individualized the restoration with stains and a glaze. Our goal was to fit the crown precisely into the overall tooth structure.

Discussion

Thanks to the newly achieved CEREC workflow time, the restoration of this premolar was very well suited for the chairside treatment with zirconia, which took only about 90 minutes in total. We were able to use full-contour zirconia, a material that has good properties for this area of the tooth and, thanks to the wide range of shades available, also offers sufficient results for esthetic requirements. We deliberately decided against a multilayer material in order to achieve the desired low translucency. The patient was very happy with the result.



Before:
Discolored tooth 45 due to a previous root canal treatment.



After:
Translucent zirconia crown with individualized finishing.



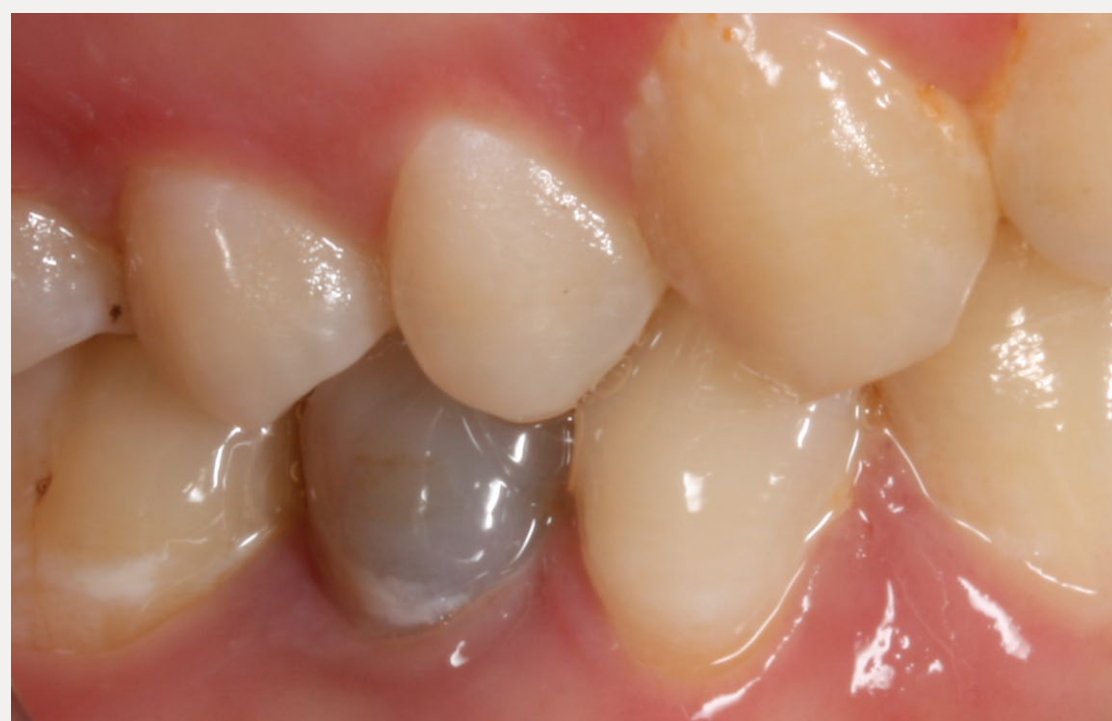

A Katana Zirconia STML single crown – Second lower premolar in 90 minutes

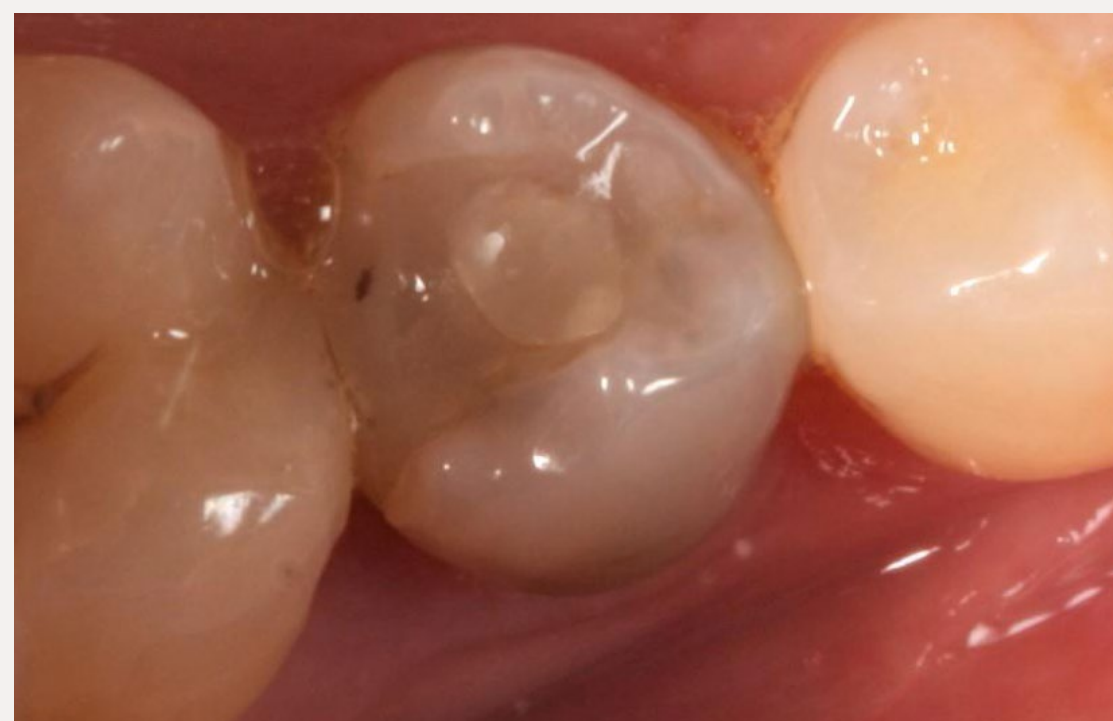

Dr. Gertrud Fabel
Munich, Germany

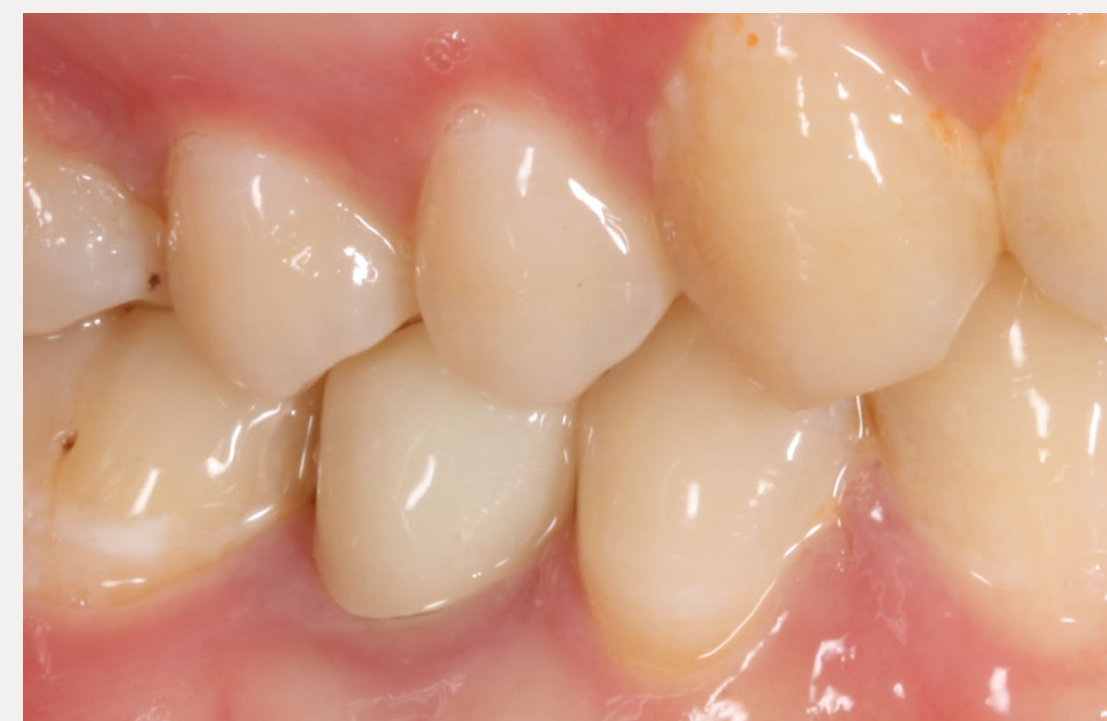Clinical Images



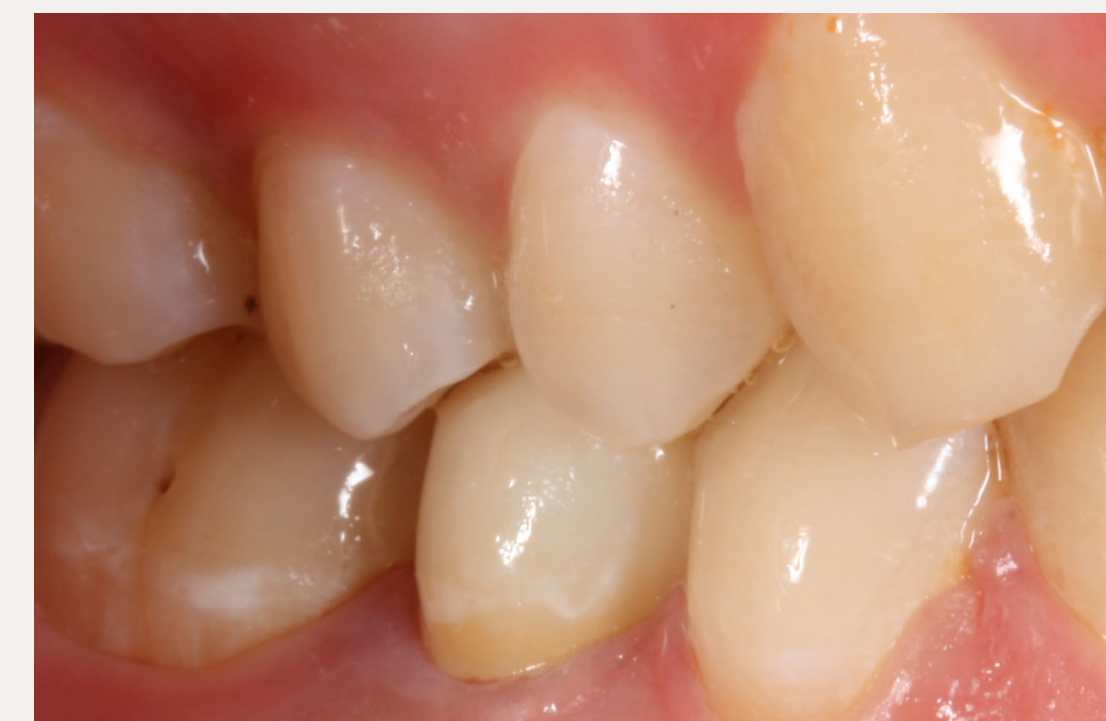Discolored root-treated tooth.



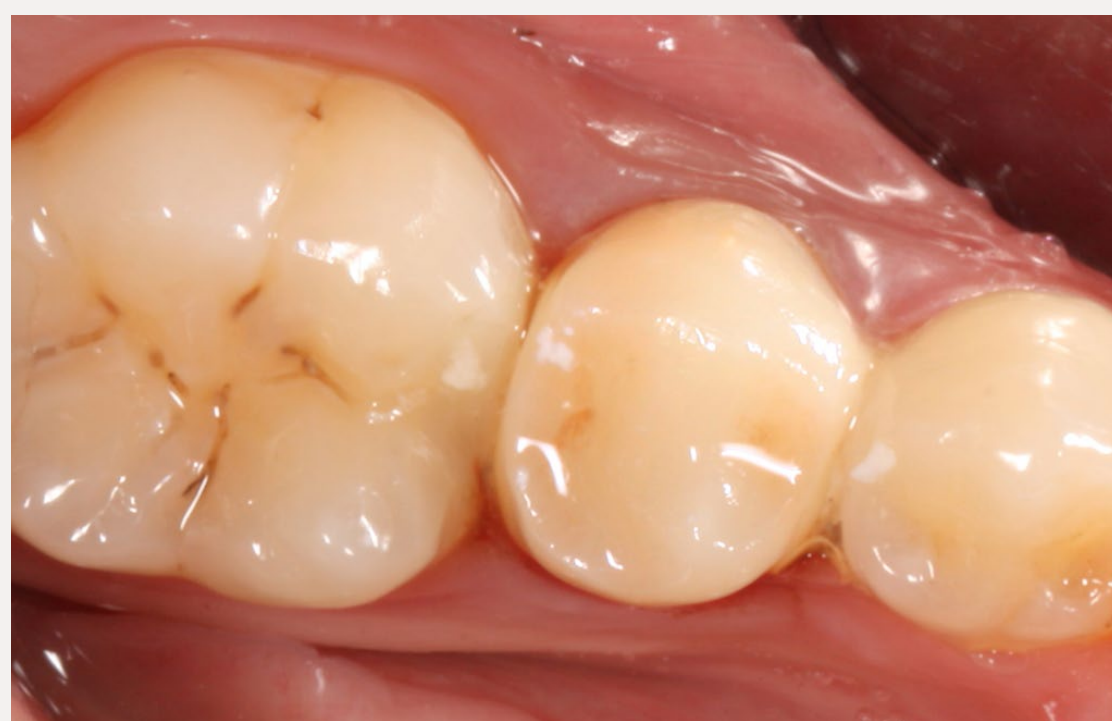Discolored root-treated tooth.



First try-in after sintering in CEREC SpeedFire.



Final restoration with individualized finishing.



Postprocessing: stain and glaze by my dental assistant.

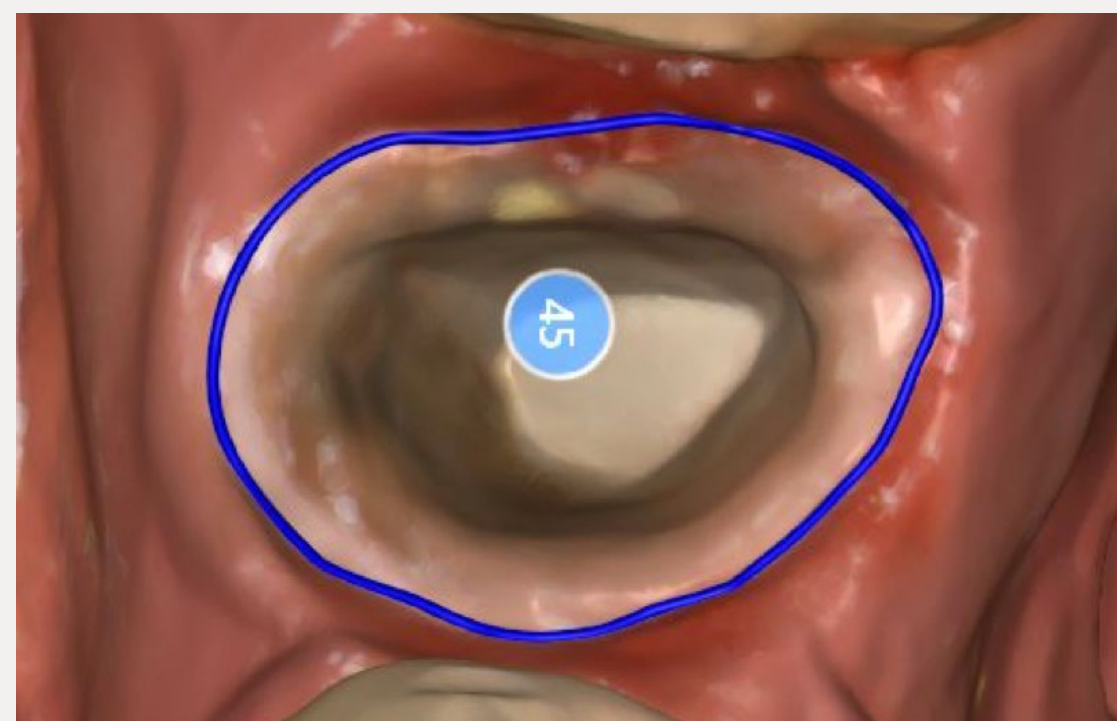


A Katana Zirconia STML single crown – Second lower premolar in 90 minutes

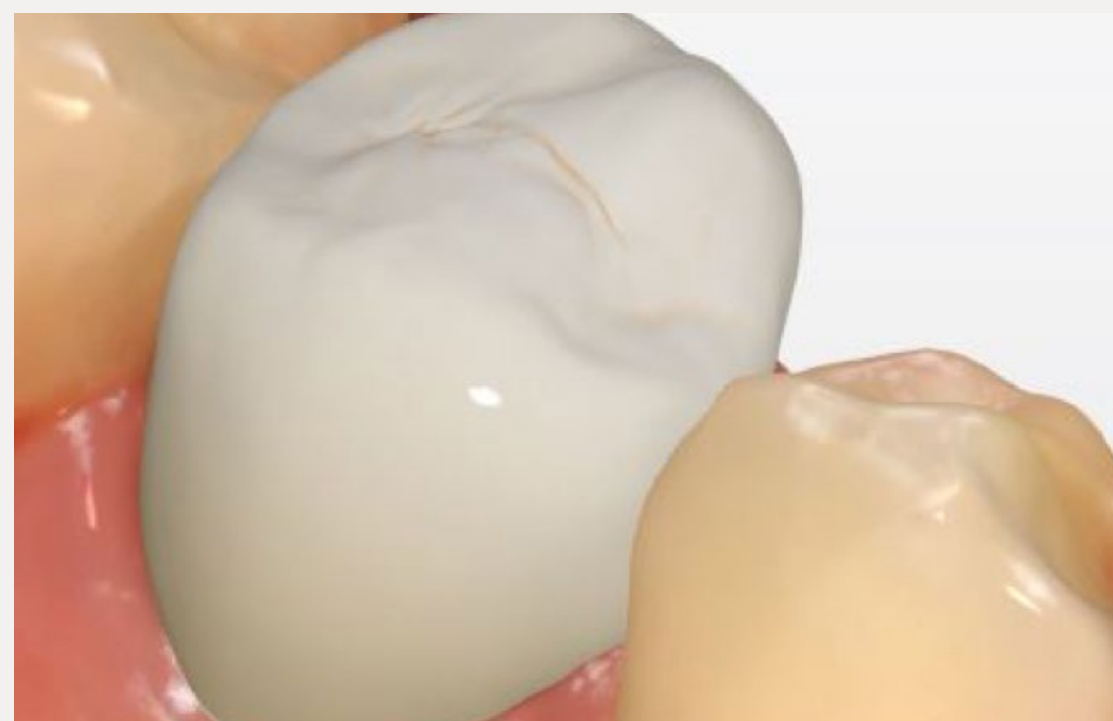

Dr. Gertrud Fabel
Munich, Germany

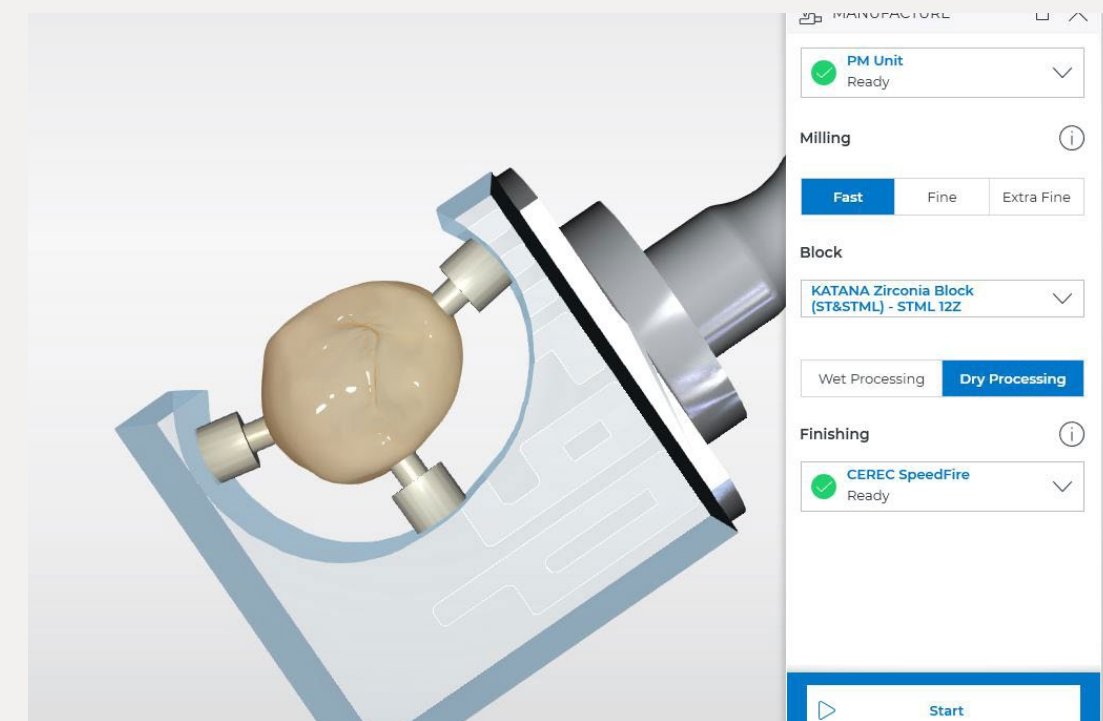
Workflow Images




Preparation with enough space for material.



Construction.



Milling mode: fast – to have more time for postprocessing.
Material: Katana Zirconia STML A3.



Milling time 8:35 min.



A Katana Zirconia STML single crown – First upper molar in 90 minutes



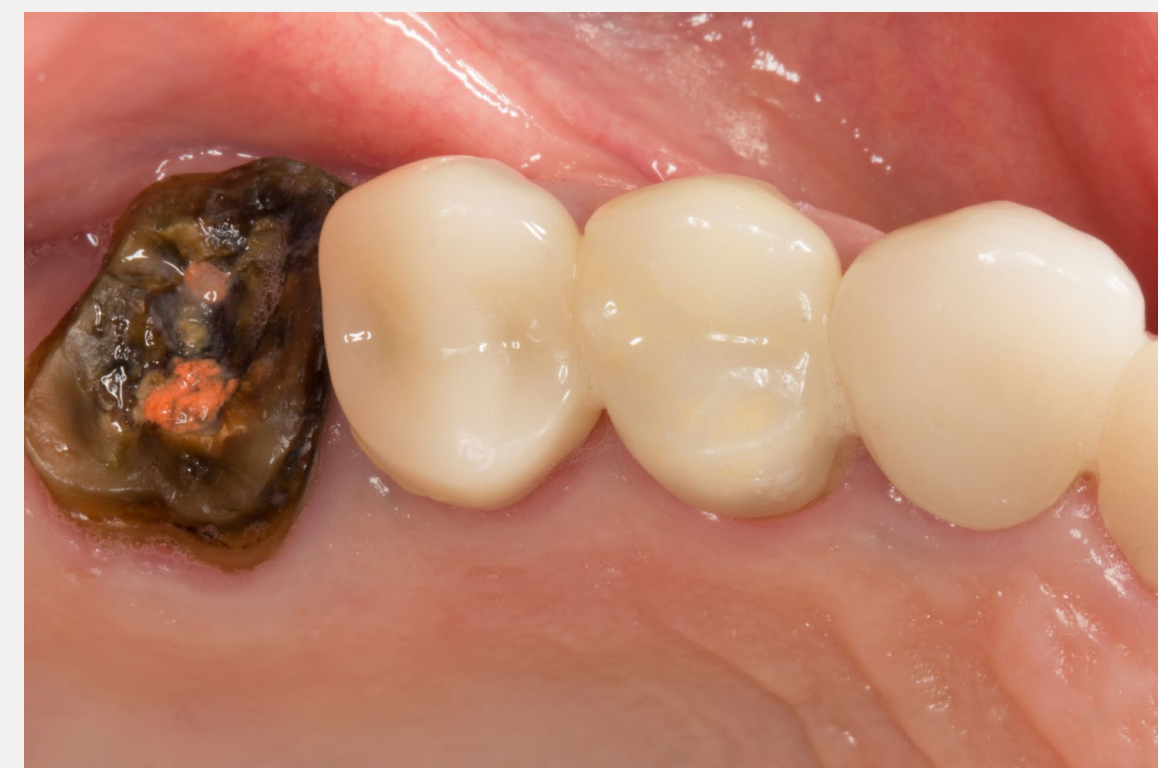Dr. Mike Skramstad, DDS
Orono, USA

Case Description

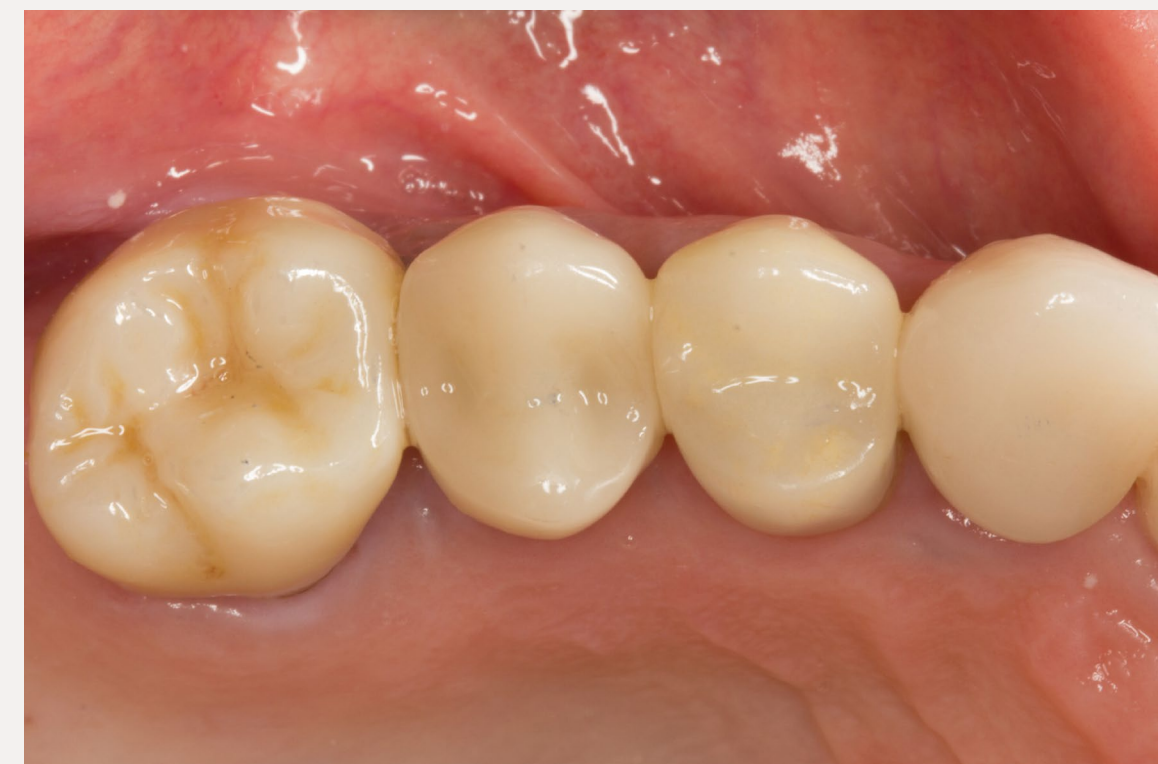A 72-year-old patient came to my practice with a fractured metal-ceramic crown on tooth 26, which had previously been treated endodontically. The tooth was free of caries and oral hygiene was very good. Our plan was to maximize the resistance and retention shape, and to fit the tooth with a new full-zirconia crown. Since the remaining upper jaw had already been restored with IPS e.max CAD restorations, the translucency had to be adapted as well as possible. For this reason, we chose Katana STML as the material. The shade selection was carried out right after anesthesia. The result (A2) was then entered into CEREC Primemill. After completing a bonded buildup, we started the preparation for the zirconia crown. We prepped to the gumline with a 1.0 mm modified shoulder (Winter Shoulder) and reduced occlusally by 2.0 mm to guarantee the final restoration had accurate anatomy and at least 1.0 mm thickness. We refrained from using a retraction thread. After preparation, the lower jaw, upper jaw, and buccal bite were recorded with CEREC Primescan in Acquisition Phase. The CEREC Software gave an excellent initial proposal and only a few adjustments were necessary. The Extra Fine milling mode was utilized to achieve a high level of detail and esthetics. This is a feature of CEREC Primemill that allows the dentist to use a 0.5 mm finishing bur to create extra detail and trueness when required for a particular clinical scenario. We needed approximately 24 minutes for the milling process and achieved a truly excellent result. We started the sintering process immediately afterwards without any further adjustments, and it was finished after 18 minutes. After sintering, the functional surfaces were polished and then stained and glazed in the CEREC SpeedFire. We cemented the restoration conventionally using resin-modified glass ionomer. The total treatment time was about one and a half hours.

Discussion

The final restoration fit excellently and needed no post-cementation adjustments. The great thing about the Extra Fine milling mode is that it provides us with the option to create additional detail. The CEREC Primemill not only brings speed to the appointment, but also versatility in milling strategies. In this case, we chose the Extra Fine milling mode to achieve maximum esthetics and attention to detail.



Before:
Fractured metal-ceramic crown on tooth 26, which had previously been treated endodontically.



After:
Translucent full-zirconia crown for an esthetic result with maximum resistance and retention shape.



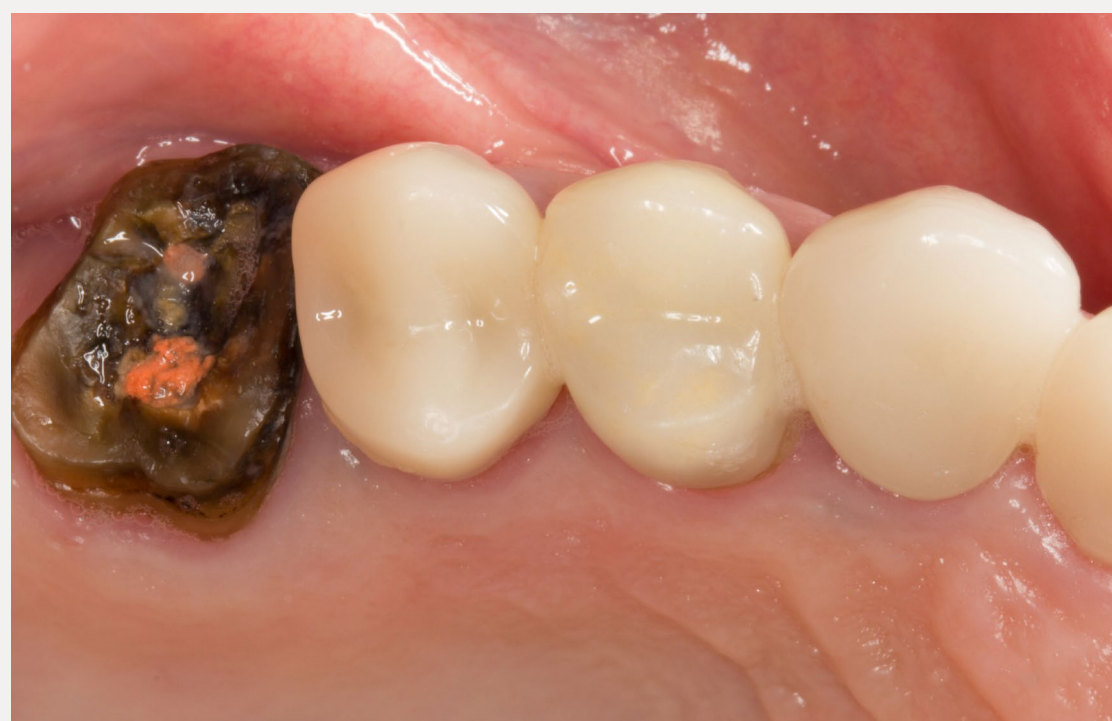

A Katana Zirconia STML single crown – First upper molar in 90 minutes

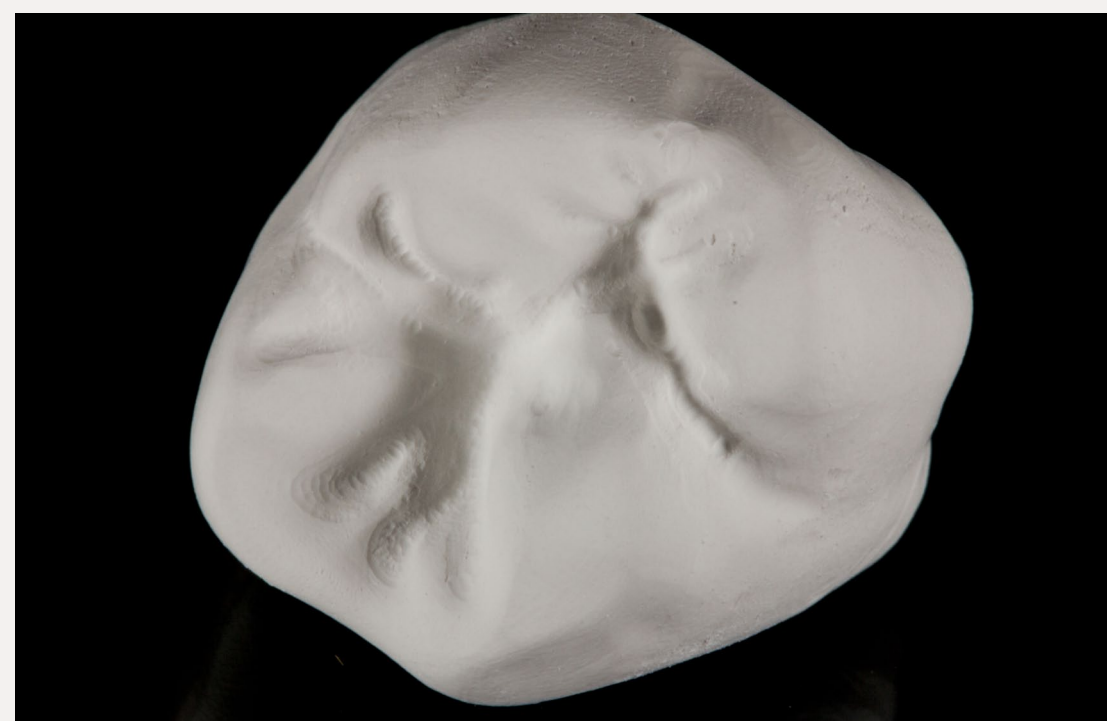


Dr. Mike Skramstad, DDS
Orono, USA

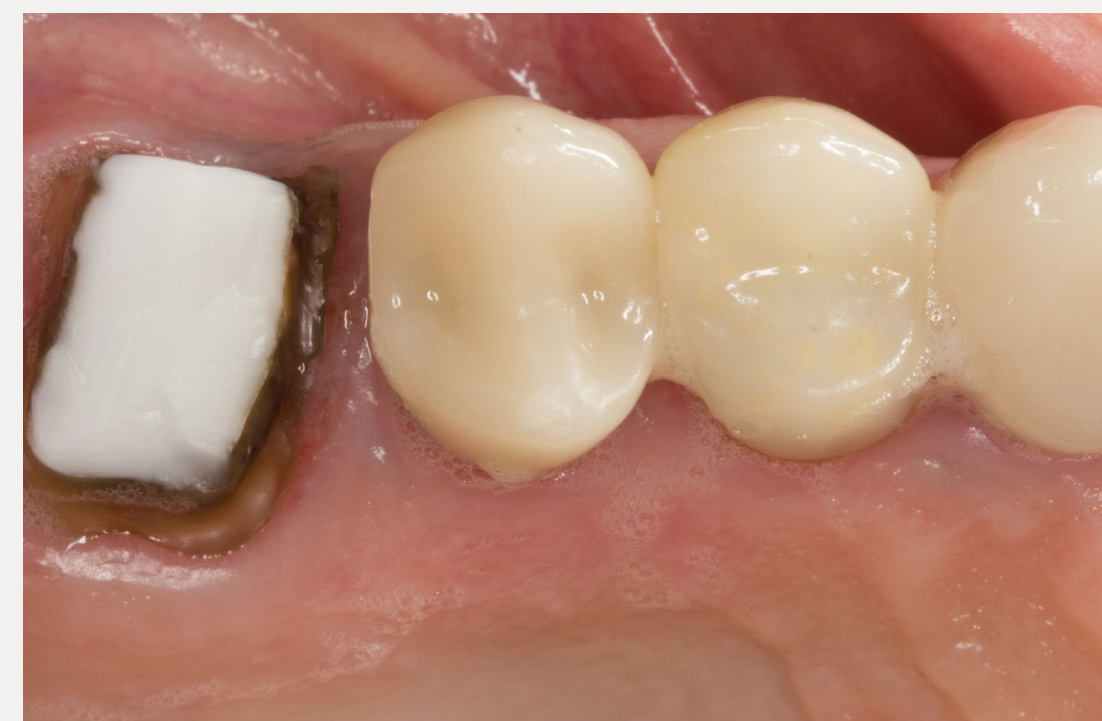Clinical Images



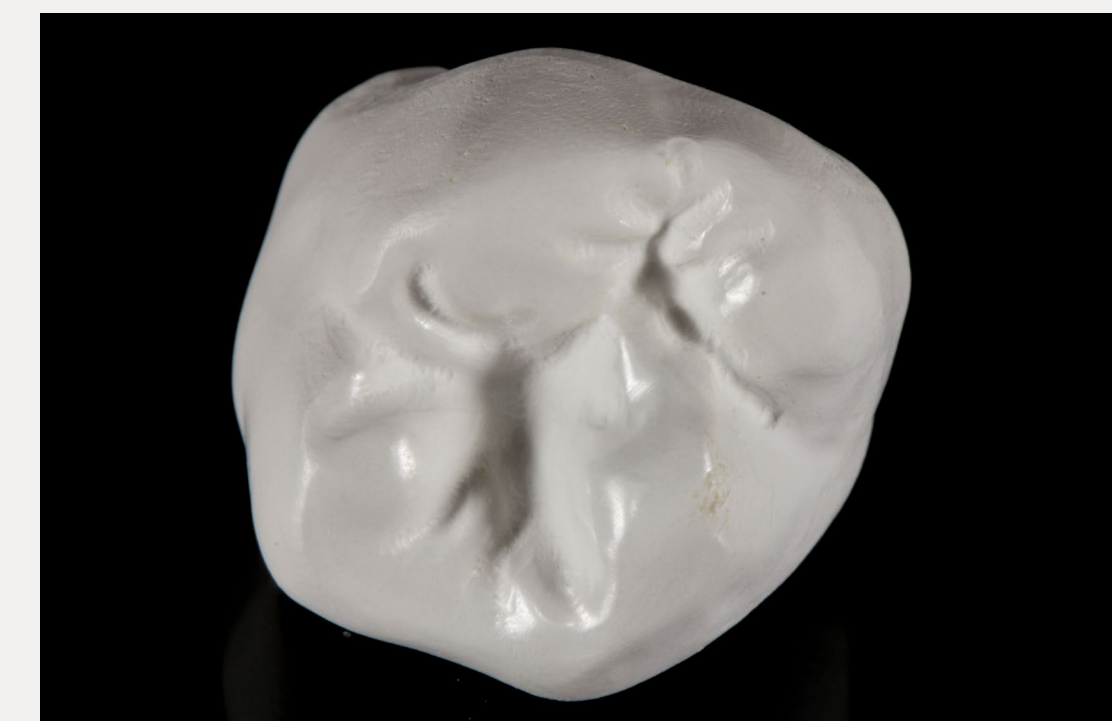Pre-op tooth 26.



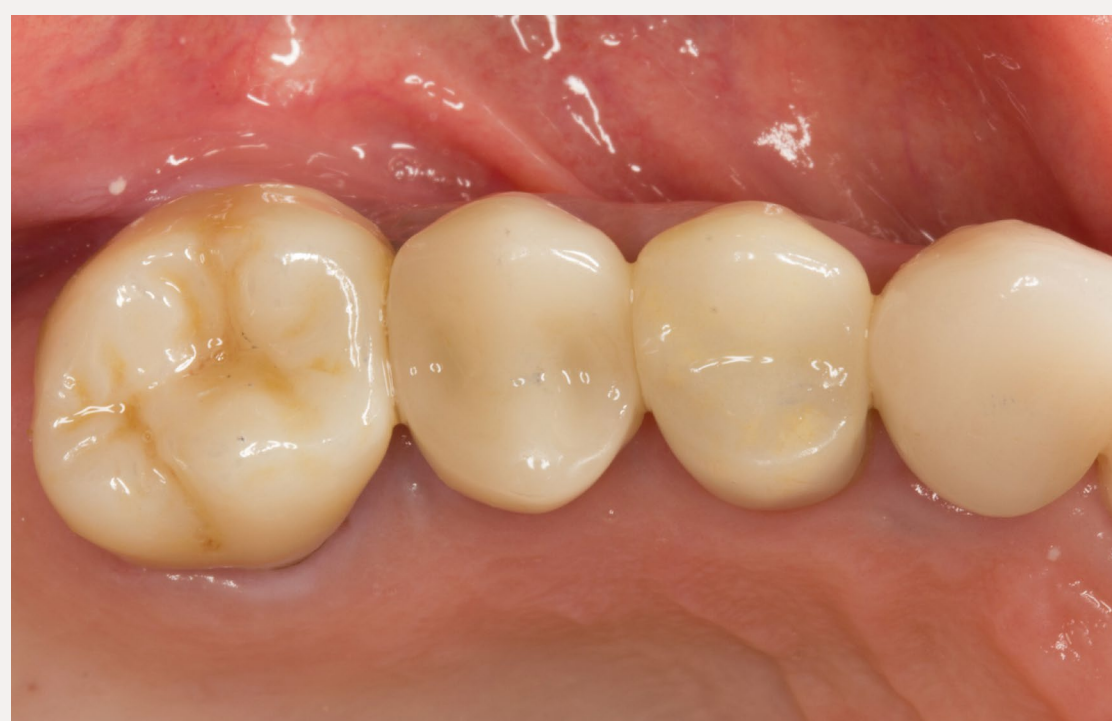Extra Fine milled crown out of milling unit.



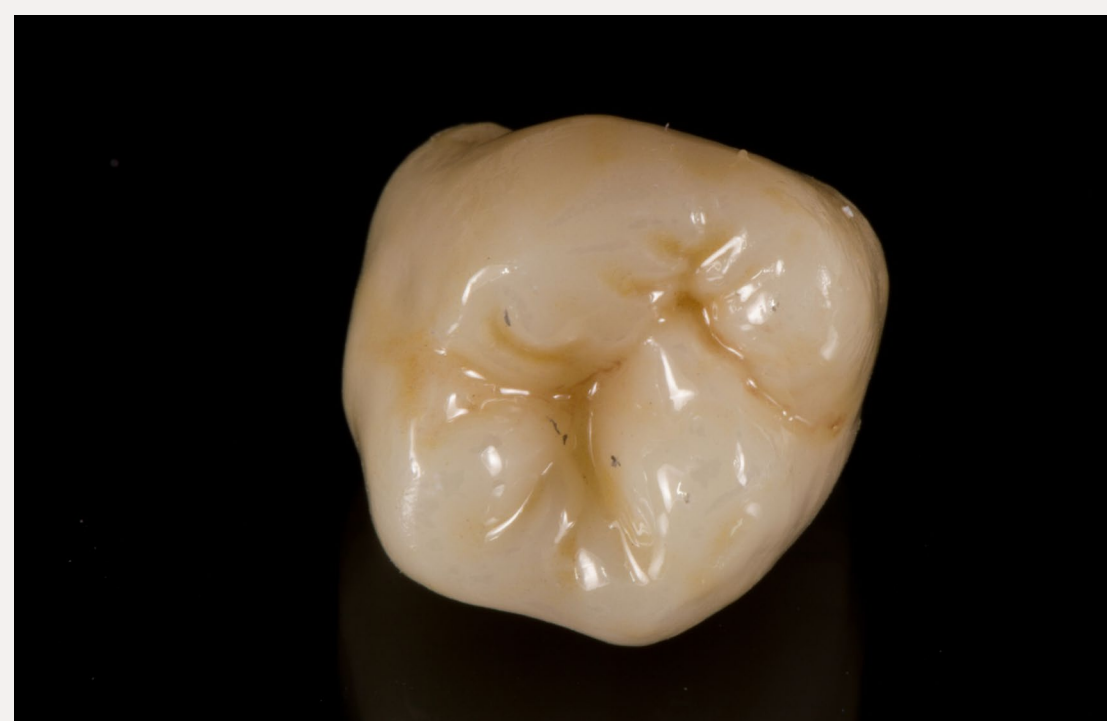Preparation tooth 26.



Pre-polished crown before sintering.



Final restoration using Extra Fine milling and Katana STML tooth 26.



Final stain and glaze.

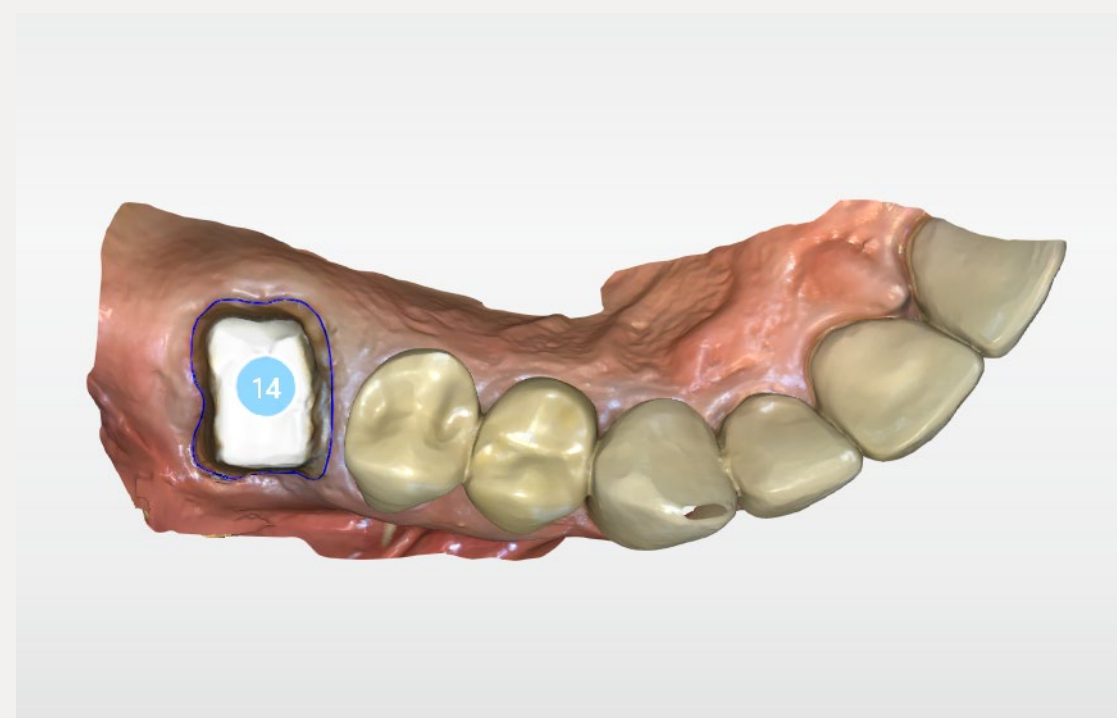


A Katana Zirconia STML single crown – First upper molar in 90 minutes

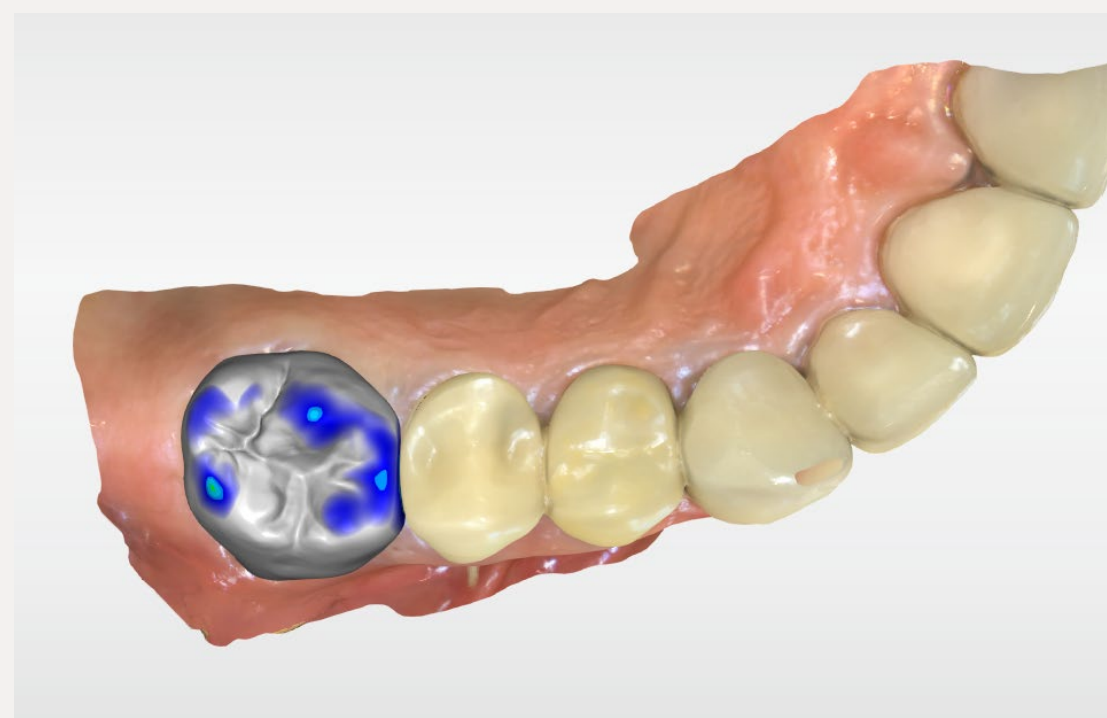


Dr. Mike Skramstad, DDS
Orono, USA

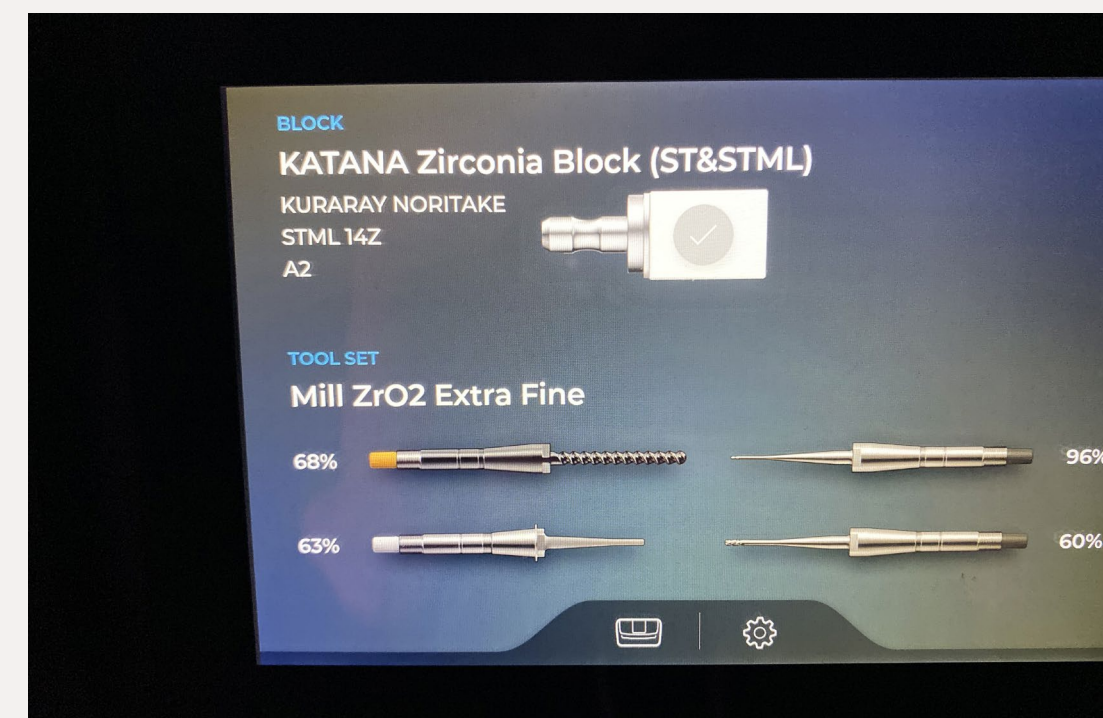Workflow Images



Automargination.



Proposal design phase.



Extra Fine milling setup.



Four IPS e.max CAD single crowns – Upper central incisors in 4 hours



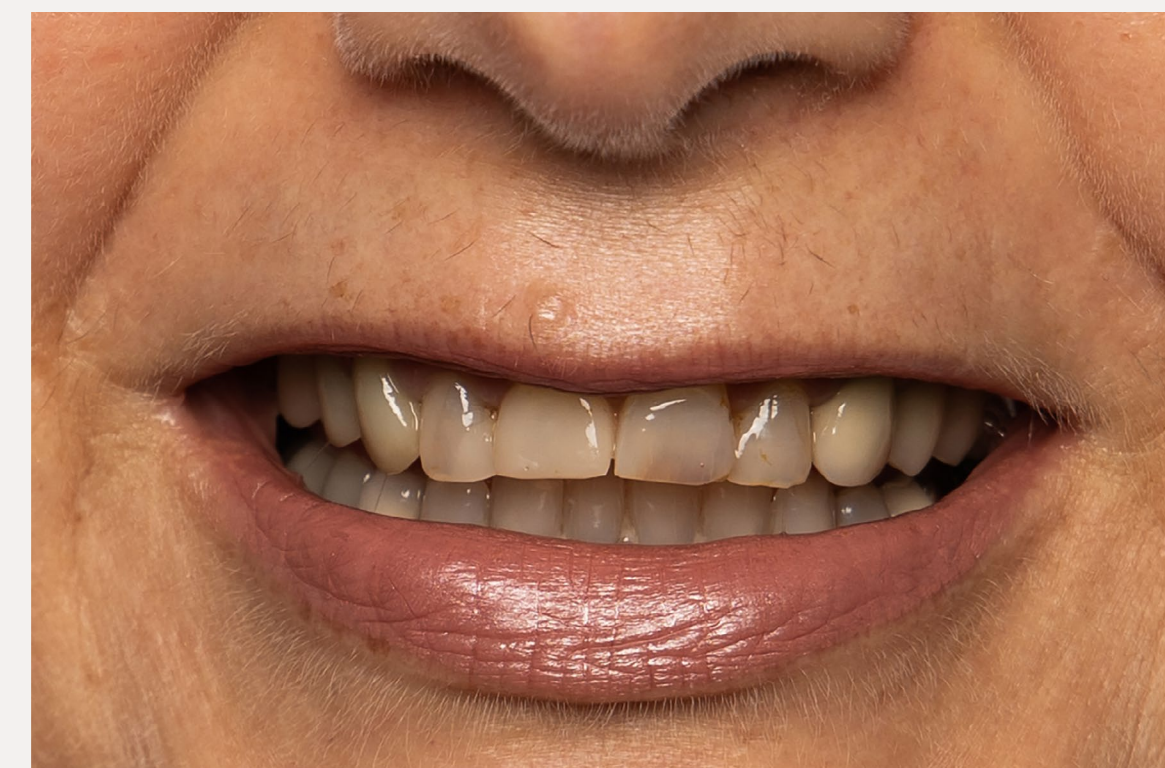Claudia Scholz
Kiel, Germany

Case Description

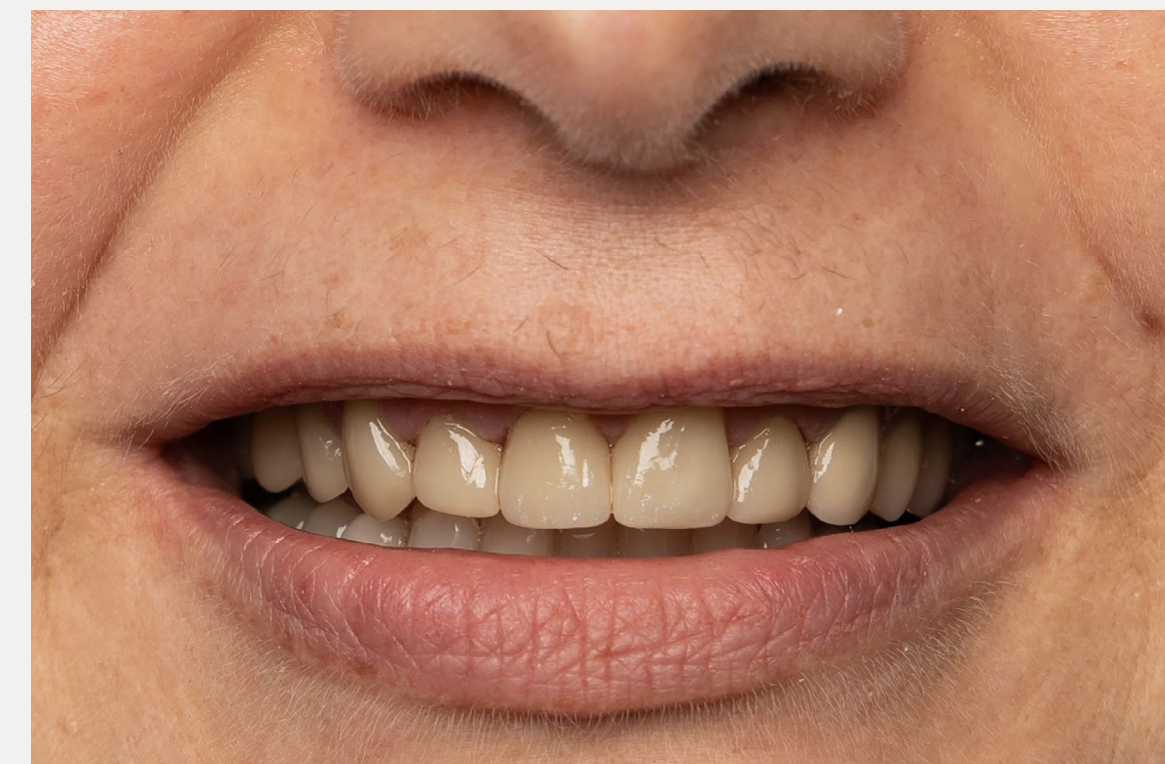A 53-year-old patient came to my practice with problems in her front teeth. The examination revealed inadequate fillings on teeth 12-22 and an uneven gingival line on 12 and 11. The patient turned down the option of a surgical adjustment. In addition to the aforementioned problems, the contour of the incisal edges was severely eroded and inconsistent. The patient suffered from these esthetic issues and she hardly dared to smile. We planned to restore the four teeth in one session with single crowns. Due to the C3 tooth shade, I decided to make her restorations with IPS e.max CAD, a lithium disilicate ceramic. The restoration of 23-26 would be adjusted later to achieve consistent esthetics. The patient explicitly asked for this. For the restoration, I followed the classic CEREC protocol. In the virtual model, I slightly corrected the automatically marked preparation margins and made an intraoral comparison. I then designed the crowns chairside. We fabricated all four crowns in succession with the CEREC Primemill. It took approximately ten minutes in the Fine mode for each one. The crowns were smooth and esthetically pleasingly structured as planned. After glazing and individualization, the crowns could be sintered in the CEREC SpeedFire. To create great optical transparency, enamel was simulated with blue ceramic stain. After sintering, the restorations were fitted once again, prepared with phosphoric and hydrofluoric acid, as well as silane and adhesively bonded under the rubber dam, and Teflon tape for contact point isolation in two sections with Prime&Bond active and Calibra Ceram adhesive and then trimmed. After an occlusion check, the new crowns received a final polish. In the end, the total treatment time took under 4 hours and resulted in a patient very satisfied with the esthetic results and with her beautiful new smile.

Discussion

For anterior teeth, particularly high esthetic requirements apply, which can also be met very well with ceramic-veneered metal or ceramic crowns. However, the disadvantage is that a conventional impression and a temporary restoration would have been necessary until the final restoration was completed in a lab. Not all patients can cope with this, especially in the anterior region. In addition, the restoration with all-ceramic crowns did not require subgingival preparation to cover the margin and no dark metal shadows disturbed the esthetics. With CEREC Primescan and CEREC Primemill patients quickly receive a high-quality all-ceramic restoration.



Before:
Inadequate fillings on teeth 12-22, an uneven gingival line on 12-11, and incisal edges severely eroded.



After:
Four highly esthetic and individualized lithium disilicate ceramic crowns.



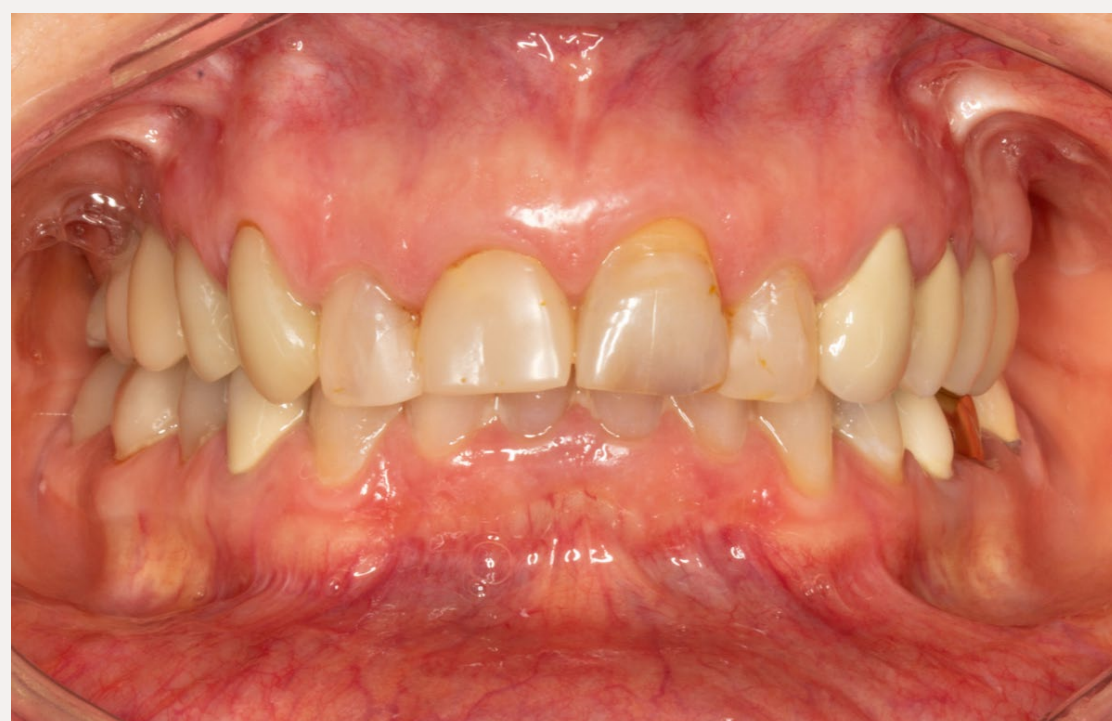

Four IPS e.max CAD single crowns – Upper central incisors in 4 hours

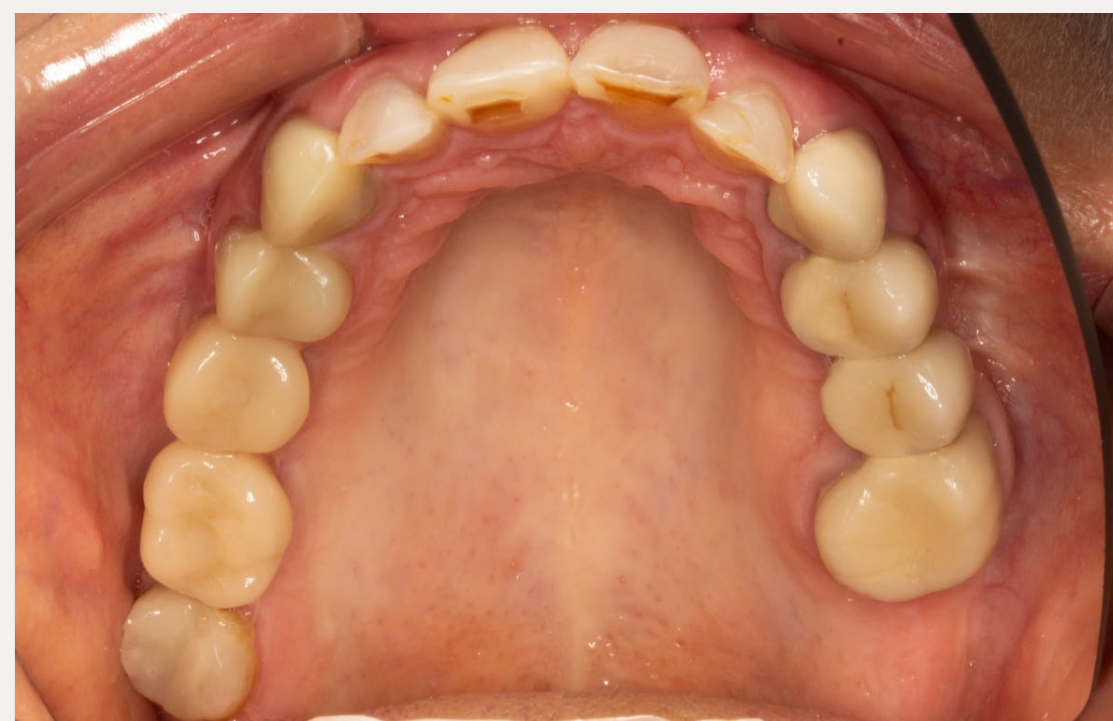

Claudia Scholz
Kiel, Germany

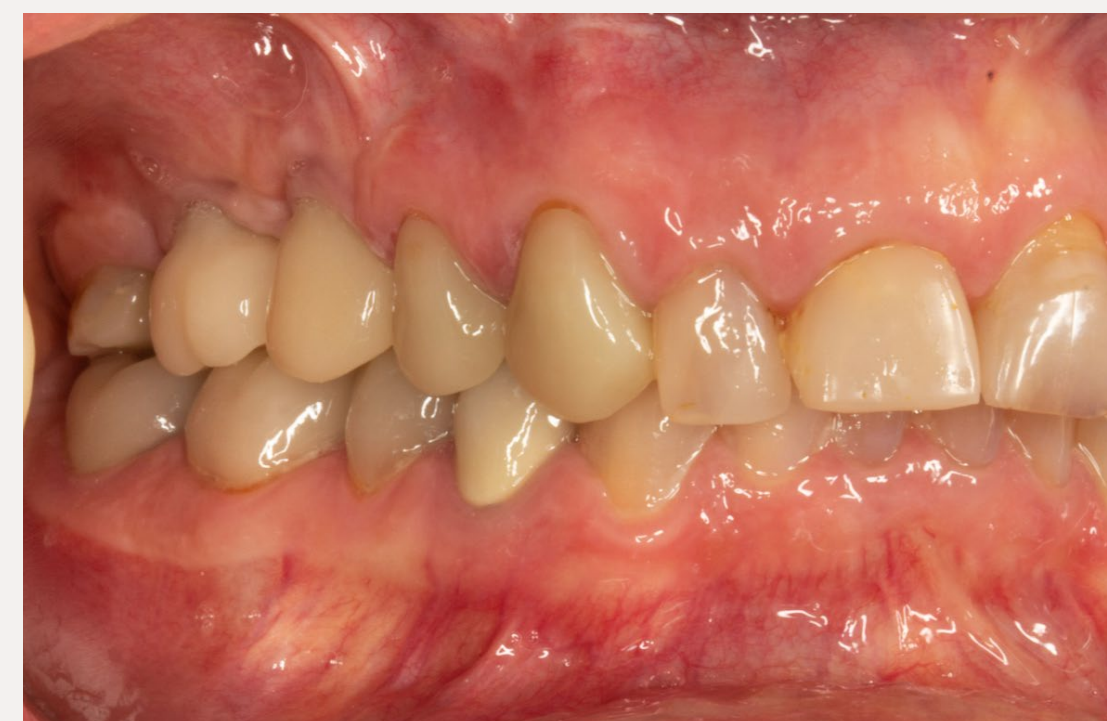Clinical Images



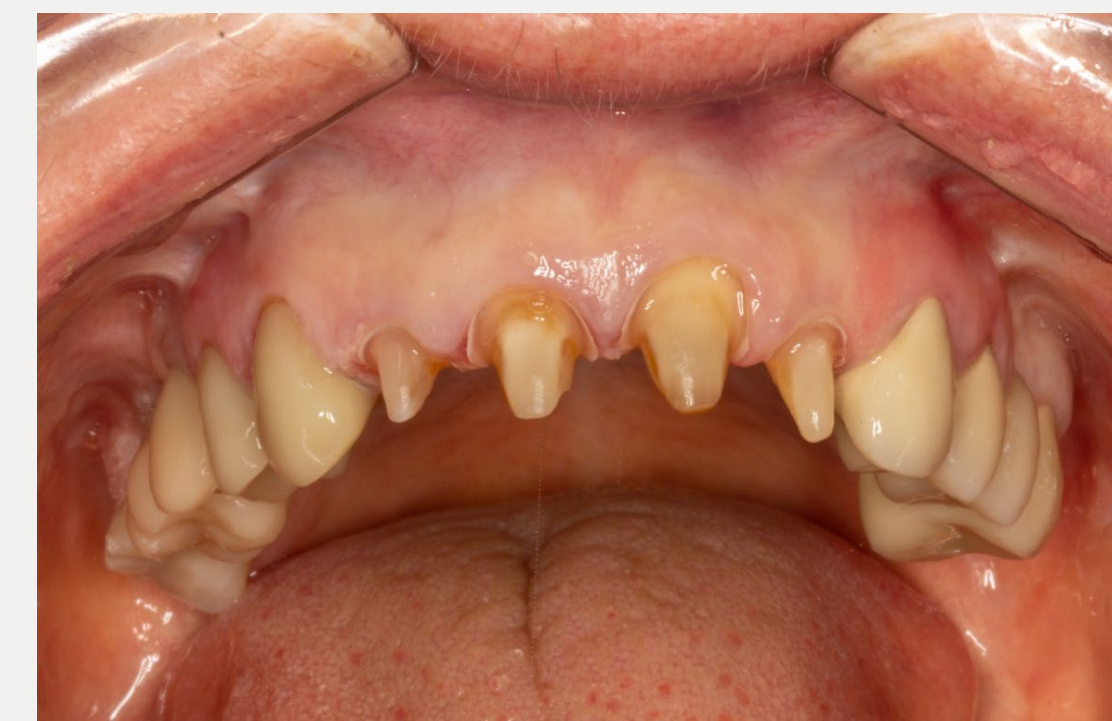Insufficient fillings in the upper front and abraded incisal edges. Crowns 23-26 were made elsewhere several years ago and should be replaced with the next procedure.



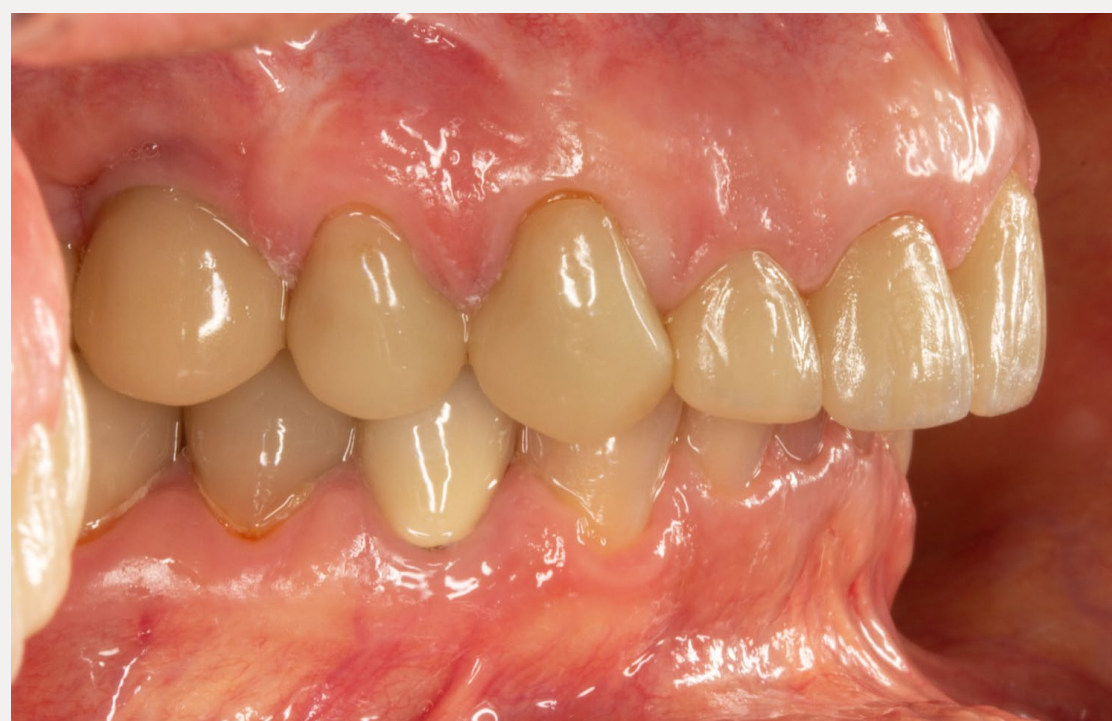Also from palatal the teeth 12-22 had a severe destruction.



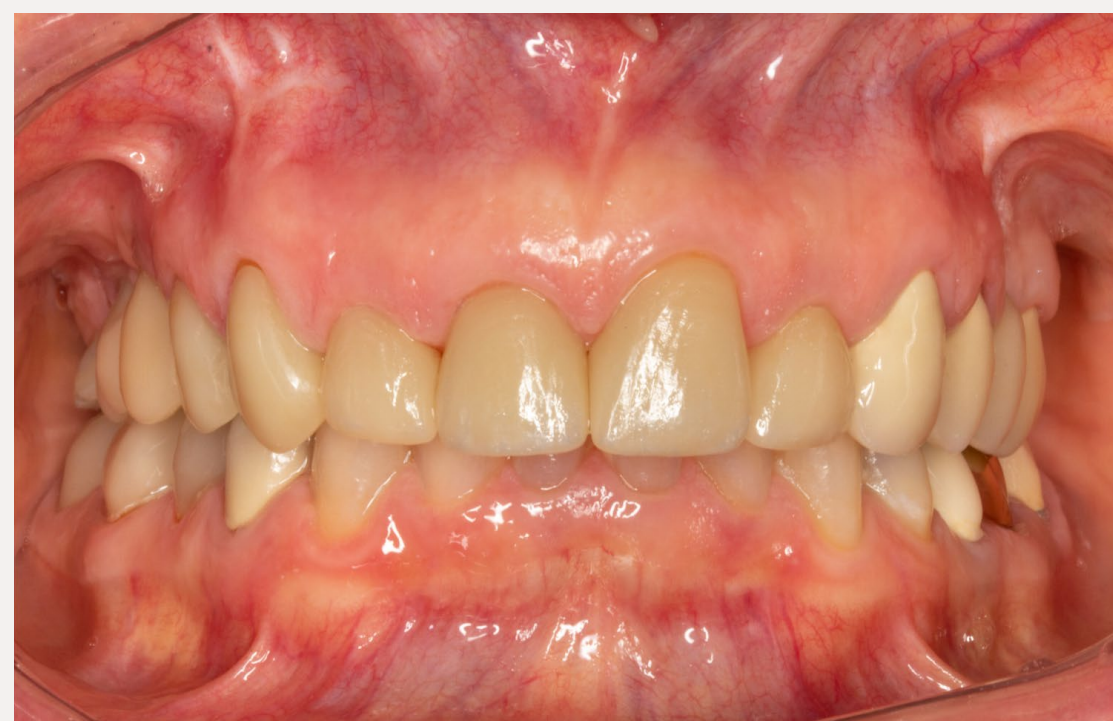The irregular line of the gingival margin.



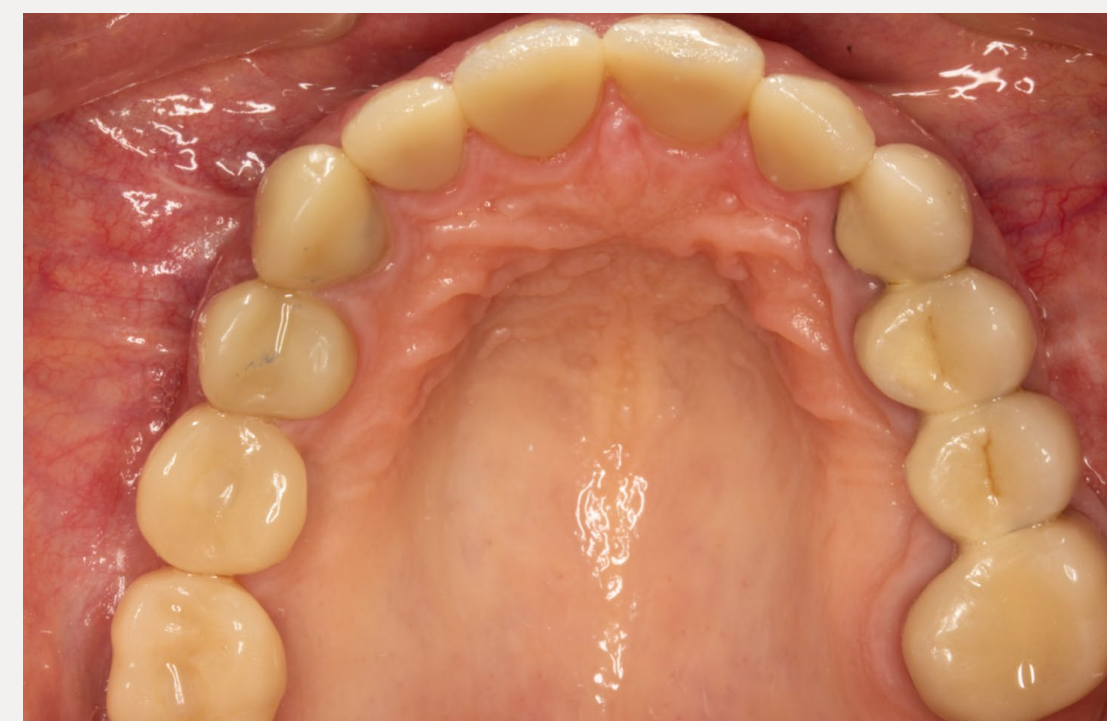
After anesthesia, the teeth were prepared.



After cementation with Prime&Bond active and Calibra Ceram, lateral view.



After adhesive cementation with Prime&Bond active and Calibra Ceram, front view.



After cementation with Prime&Bond active and Calibra Ceram, palatal view.

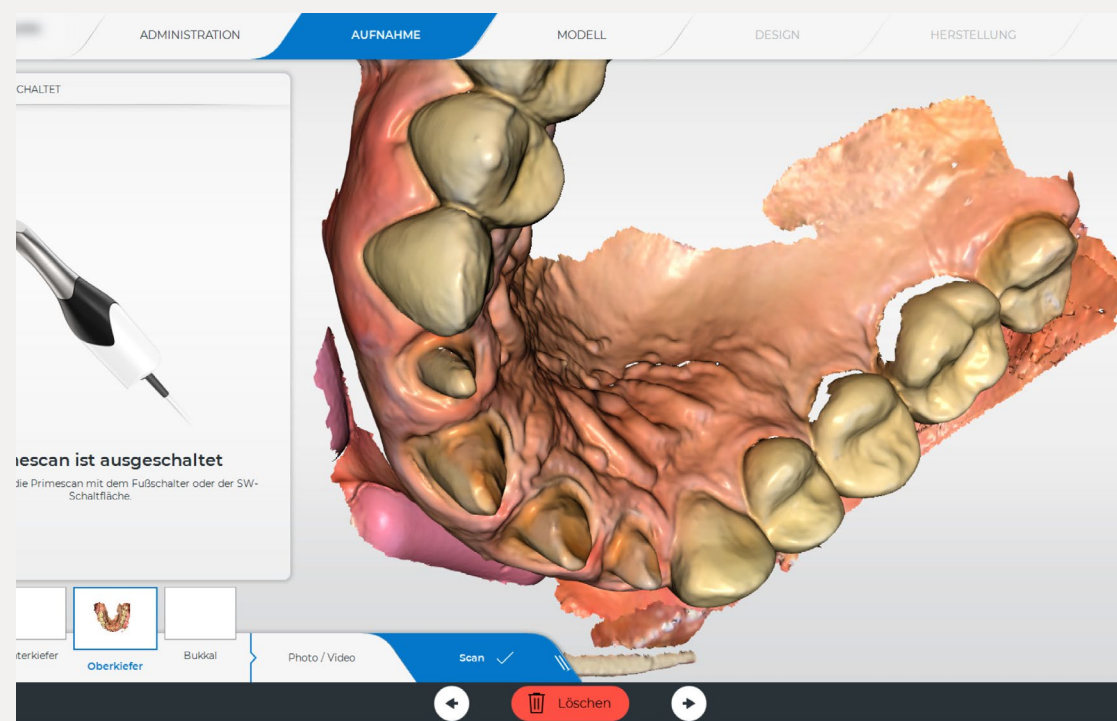


Four IPS e.max CAD single crowns – Upper central incisors in 4 hours

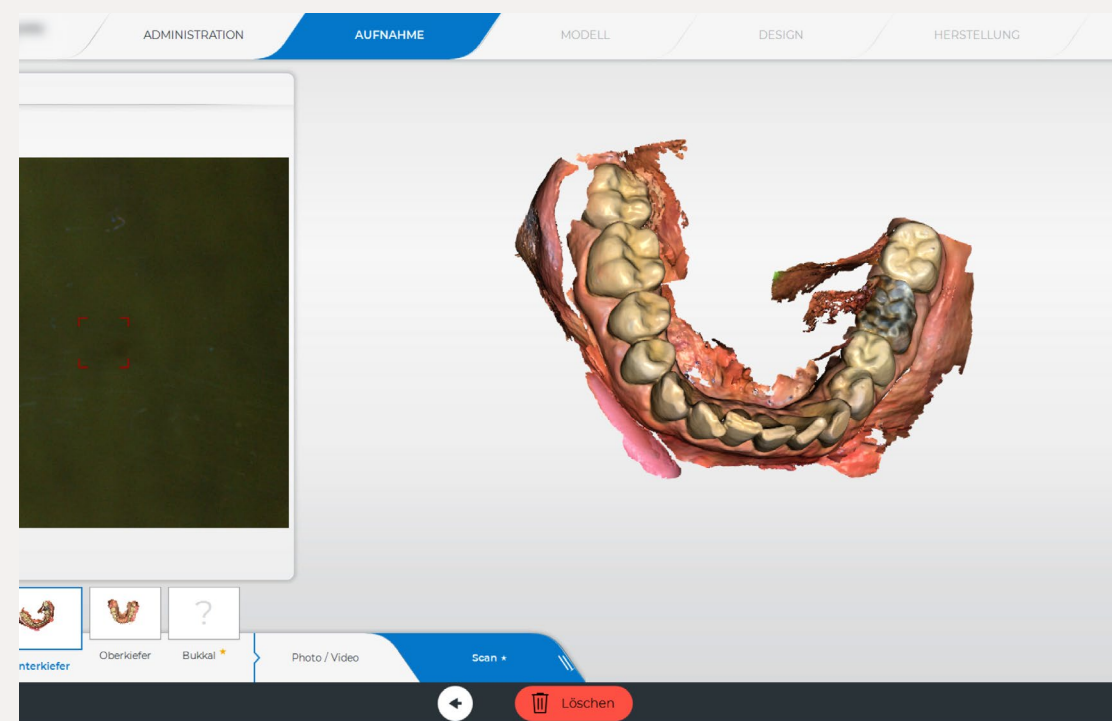


Claudia Scholz
Kiel, Germany

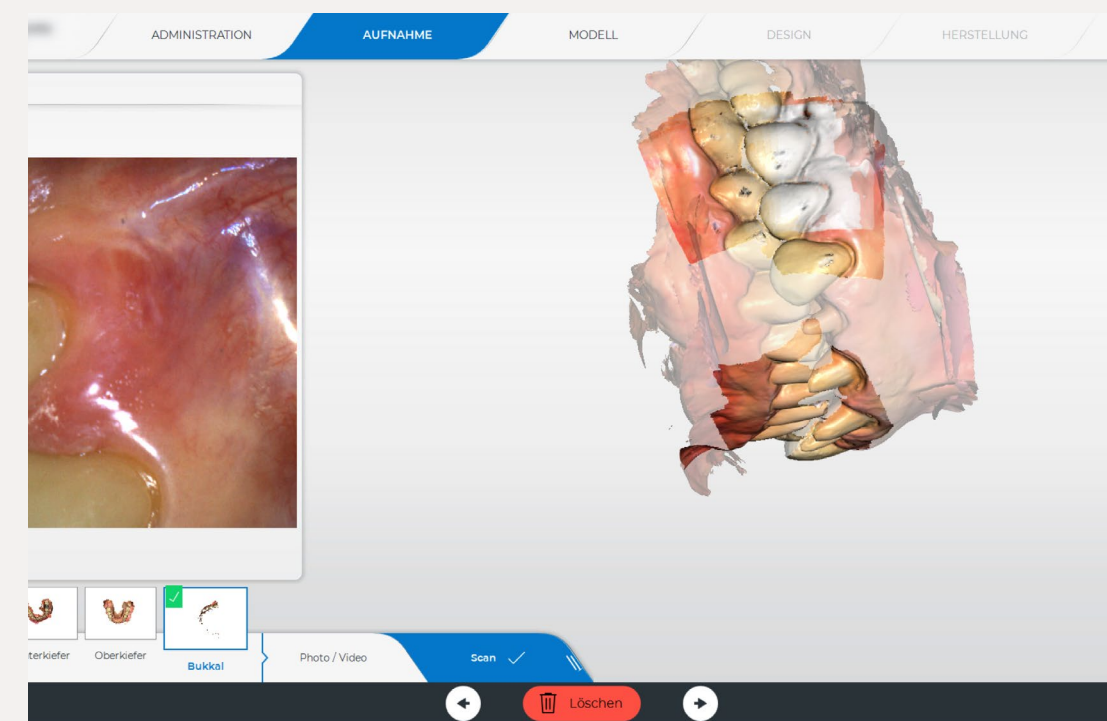
Workflow Images



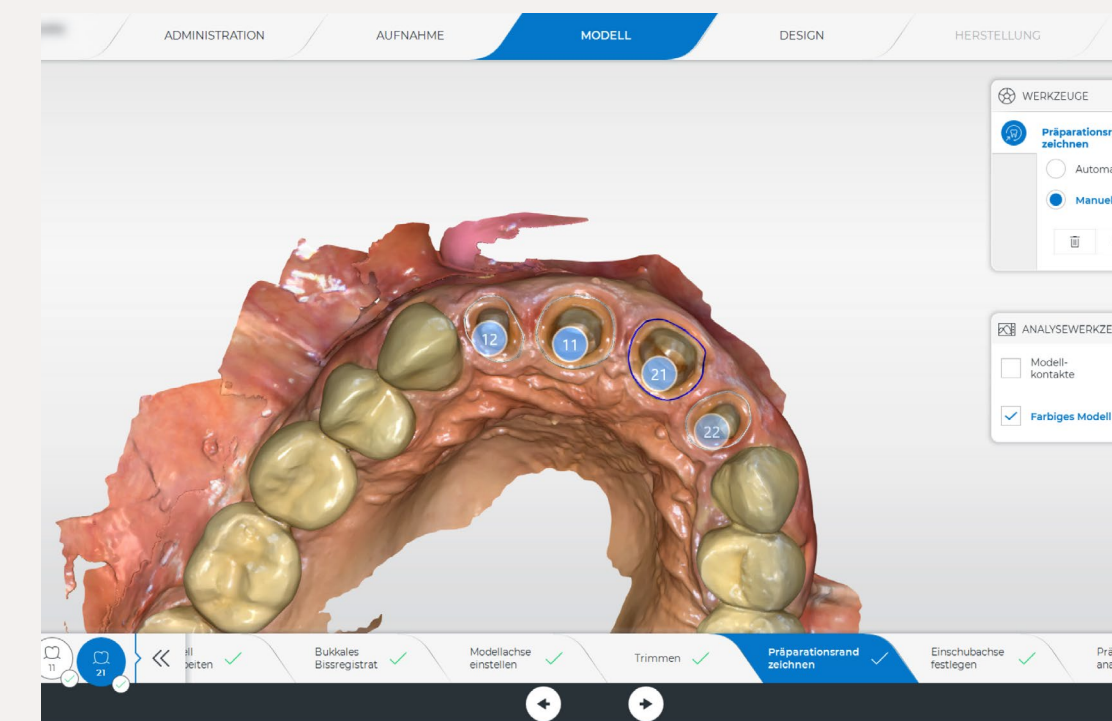
Scan of the upper prepared jaw.



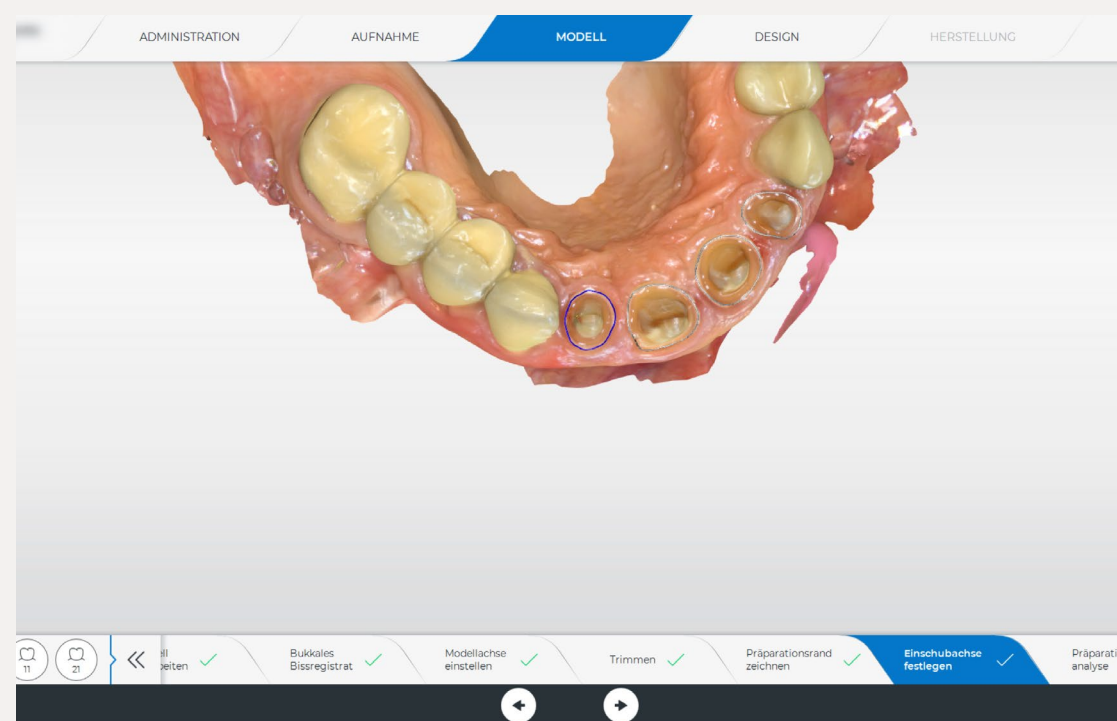
Scan of the lower jaw.



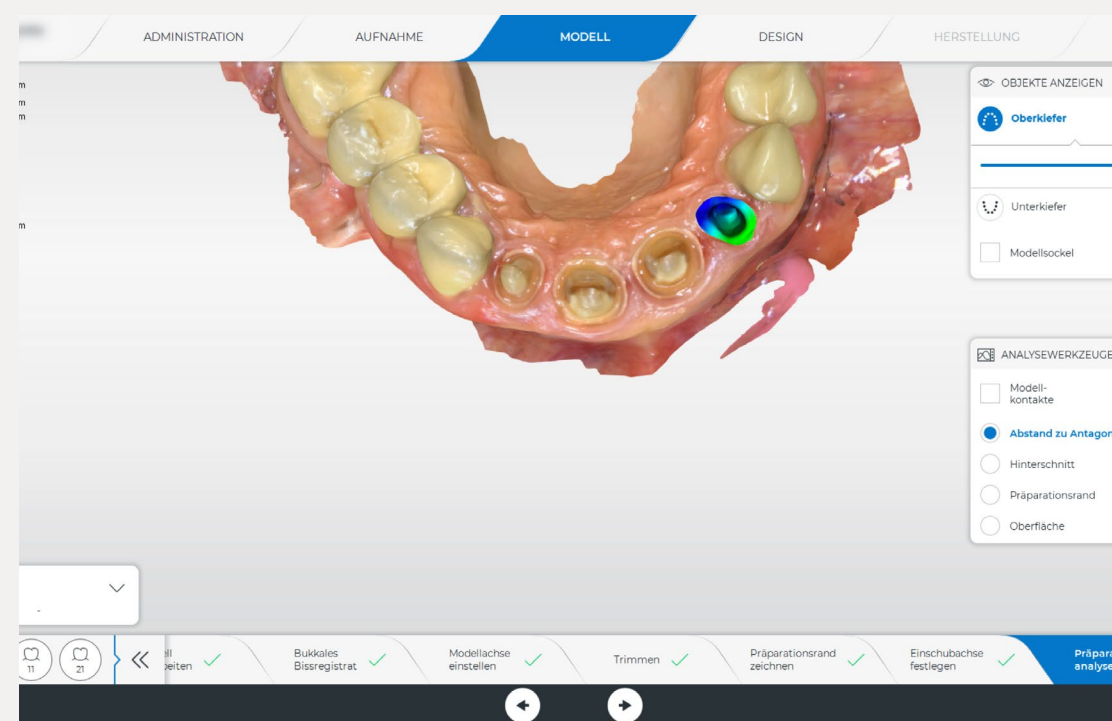
Buccal occlusion.



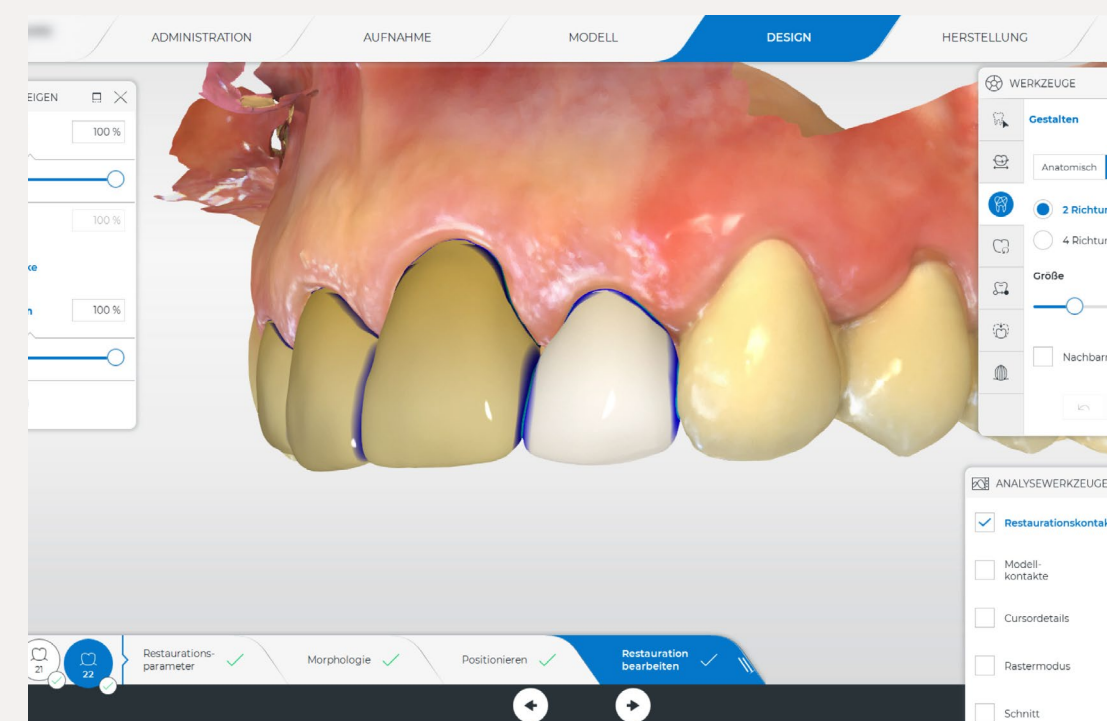
The system showed a perfect preparation line.



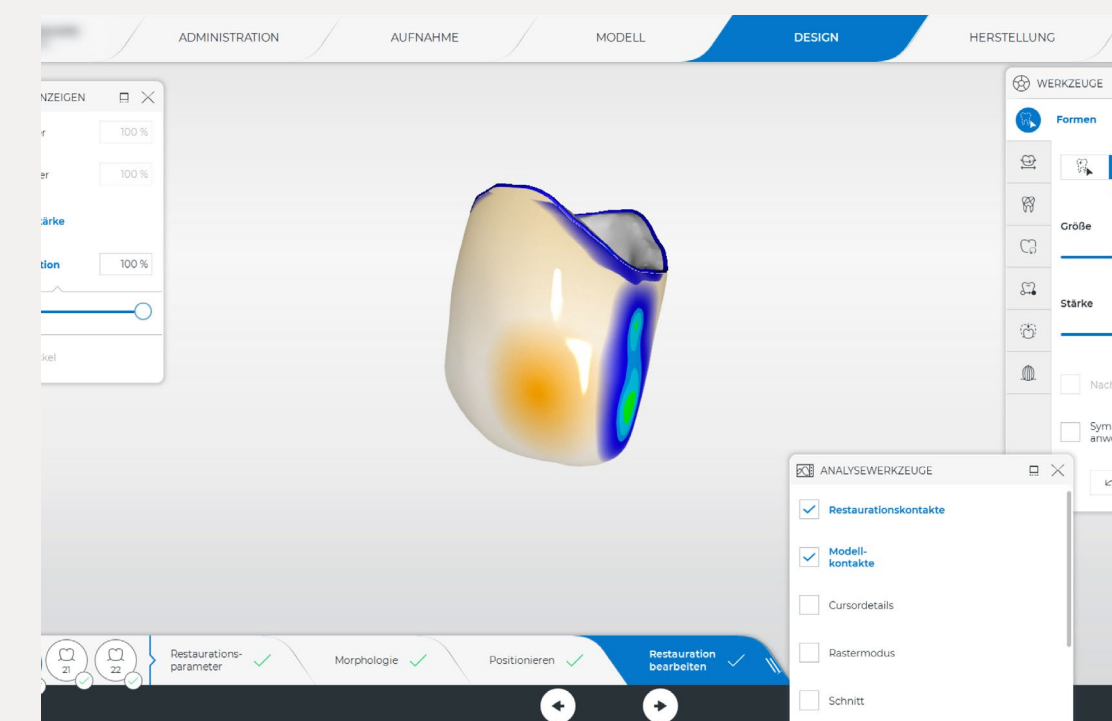
Only minimal corrections of the preparation line were made.




Preparation analysis to identify potentially problematic areas. In this case there were none.



The construction from the labial side.



The design of the proximal contact point.



Ten VITA Suprinity PC single crowns – Quadrant rehabilitation in 2 sessions



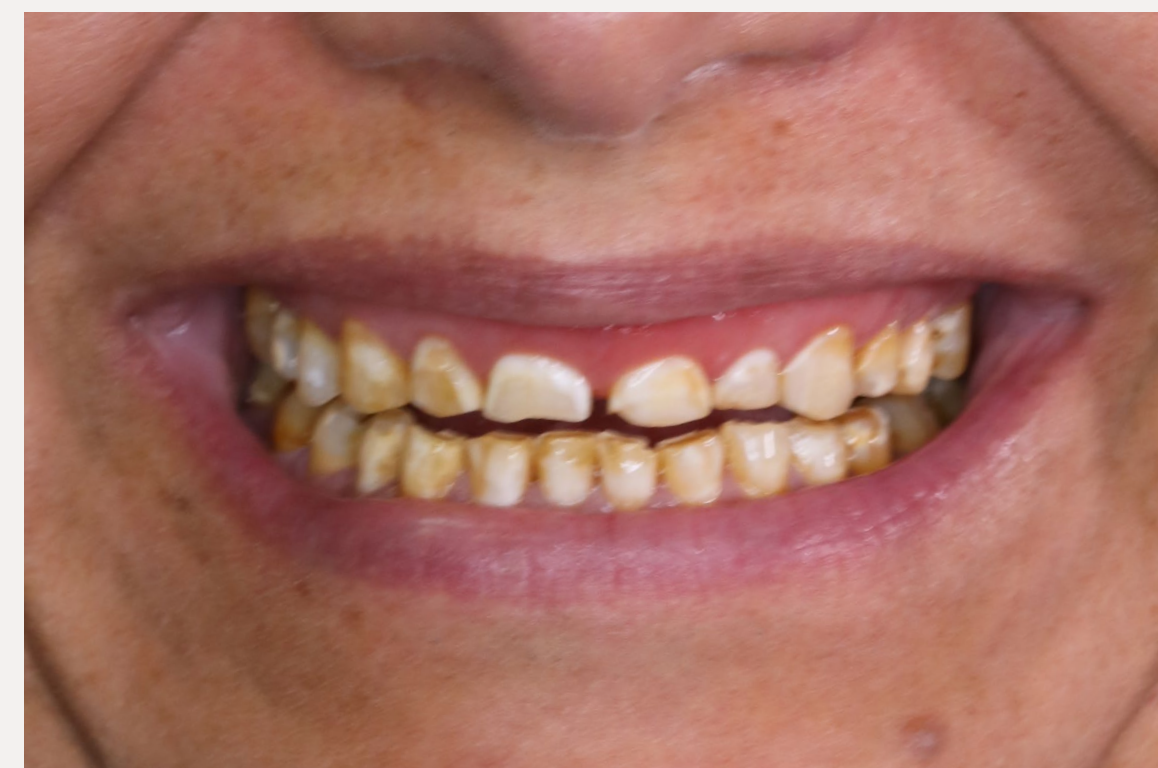Dr. Daniel Vasquez
San Diego, USA

Case Description

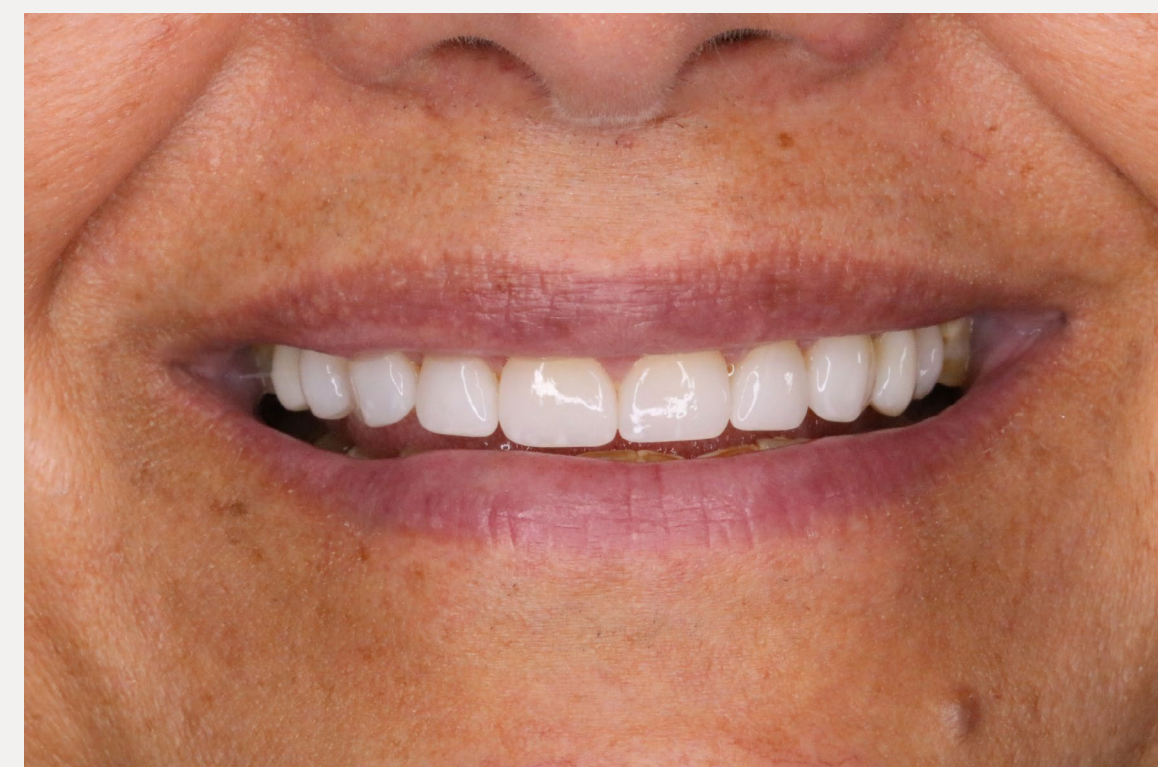A 62-year-old female patient came into my dental office for a check-up and dental cleaning. She has been a patient in the practice for seven years and now complains that she hardly dares to smile. She was dissatisfied due to discoloration and wanted to improve her smile. In the first session, all the information and data for the CEREC Smile Design process was recorded: thorough anamnesis, conversation on the treatment goal, clinical examination. In addition to communication, documentation is an important success factor. An intraoral scan with the CEREC Primescan was taken to create a 3D model – the basis for a mock-up. This was then used to make the final decision for the planned treatment with the patient. A full arch scan was taken for preparations and from mock-up, adding to a Biocopy folder. A very important step was to set the model axis and insert axis for best grinding results. After the initial proposal, the CEREC Smile Design application was activated to finalize the design of the restoration using the patient’s face and smile. We used a grid in the software to align the teeth to a suitable length. Suprinity is a zirconia-reinforced, high-strength glass-ceramic with high esthetics because of the integrated translucency, opalescence and fluorescence. In the Fast mode of the CEREC Primemill, it took an average of six minutes to grind a single restoration. After removing the block, the interproximal line angles as well as the form of the tooth were contoured, creating the ideal emergence, shape, texture, and form. Restorations were finished and polished, and showed passive fit in the printed model. Afterwards, all ten crowns were crystallized. In order to achieve a highly esthetic result, the crowns were individualized with stains. Restorations were fixed using adhesive (Clearfil Universal Bond Quick, Panavia SA Cement Universal, Kuraray Noritake).

Discussion

The patient wanted a beautiful smile. As teeth 15 to 25 are all visible, the decision was made to use a highly esthetic ceramic for all 10 of them. Due to the extensive consultation and the implementation with a mock-up, the restoration was carried out in two sessions with CEREC. The patient was very satisfied with the result.



Before:
Patient dissatisfied with her smile due to tooth discoloration.



After:
Ten highly esthetic single crowns individualized with stains.



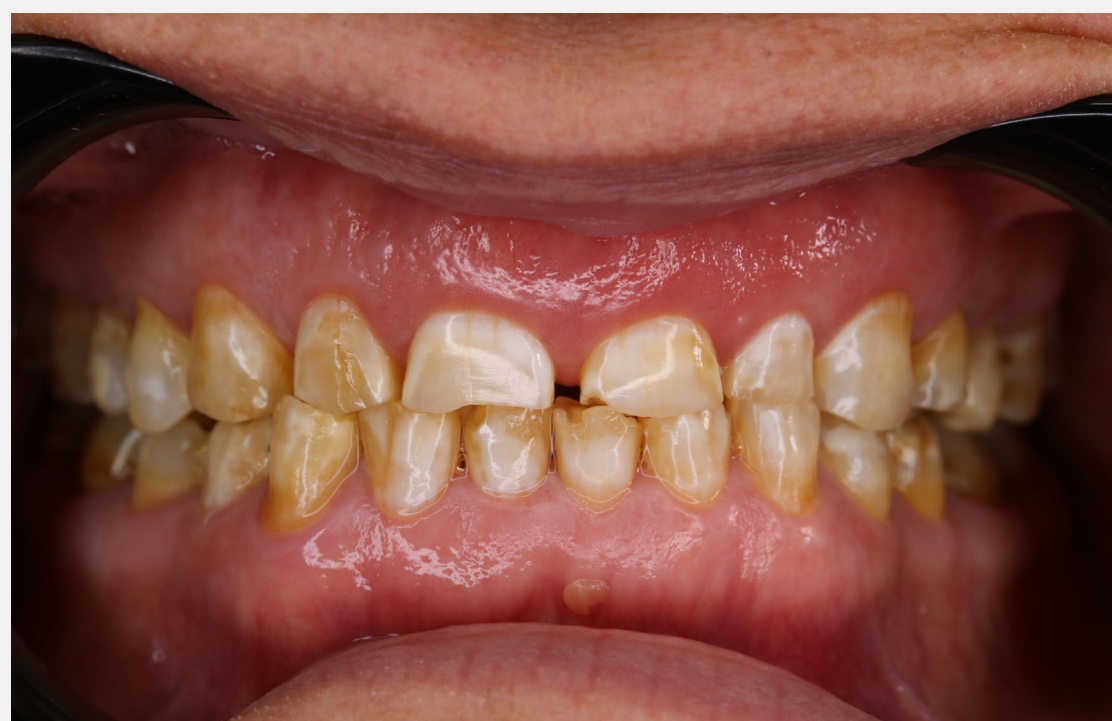

Ten VITA Suprinity PC single crowns – Quadrant rehabilitation in 2 sessions

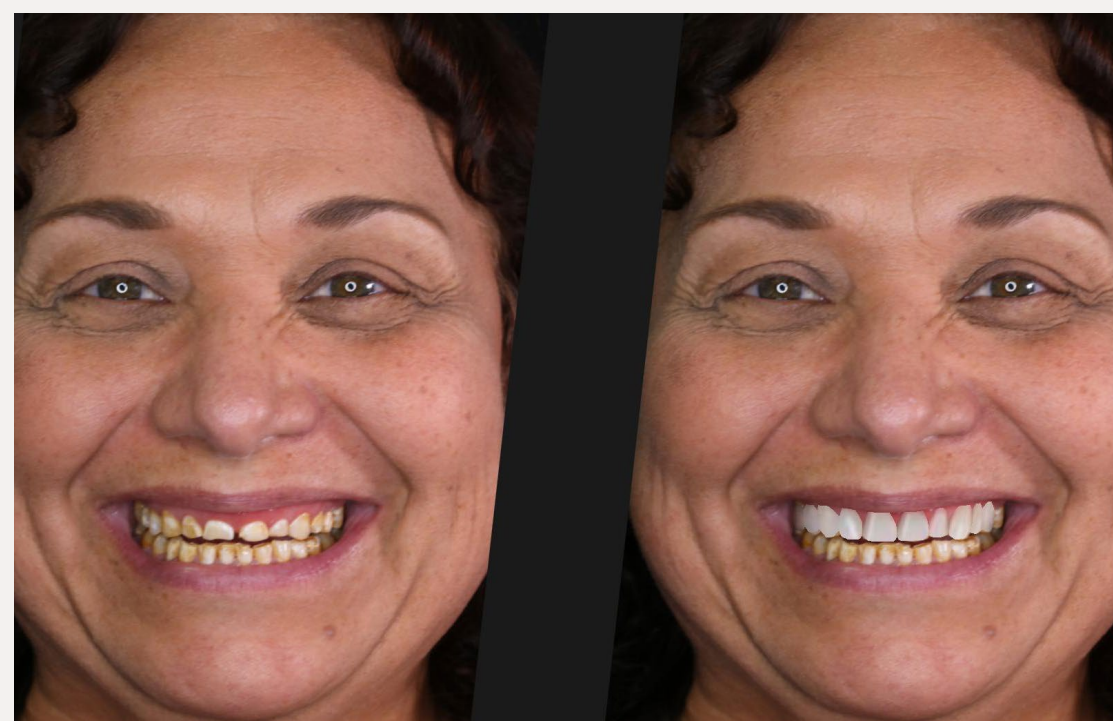

Dr. Daniel Vasquez
San Diego, USA

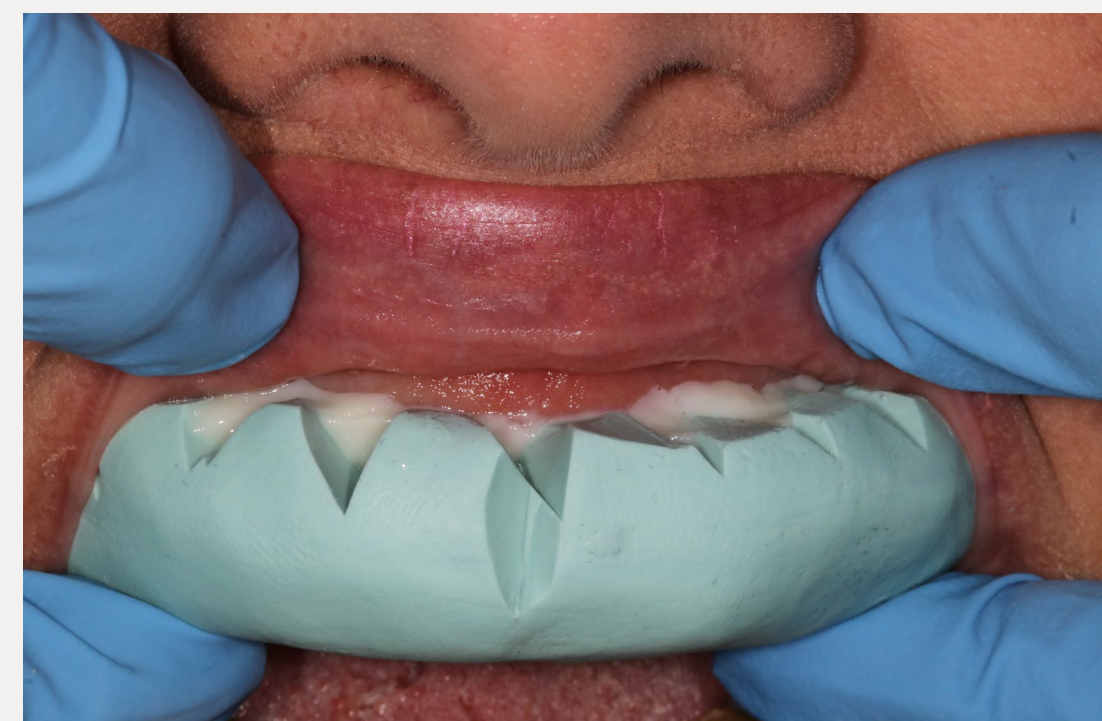Clinical Images



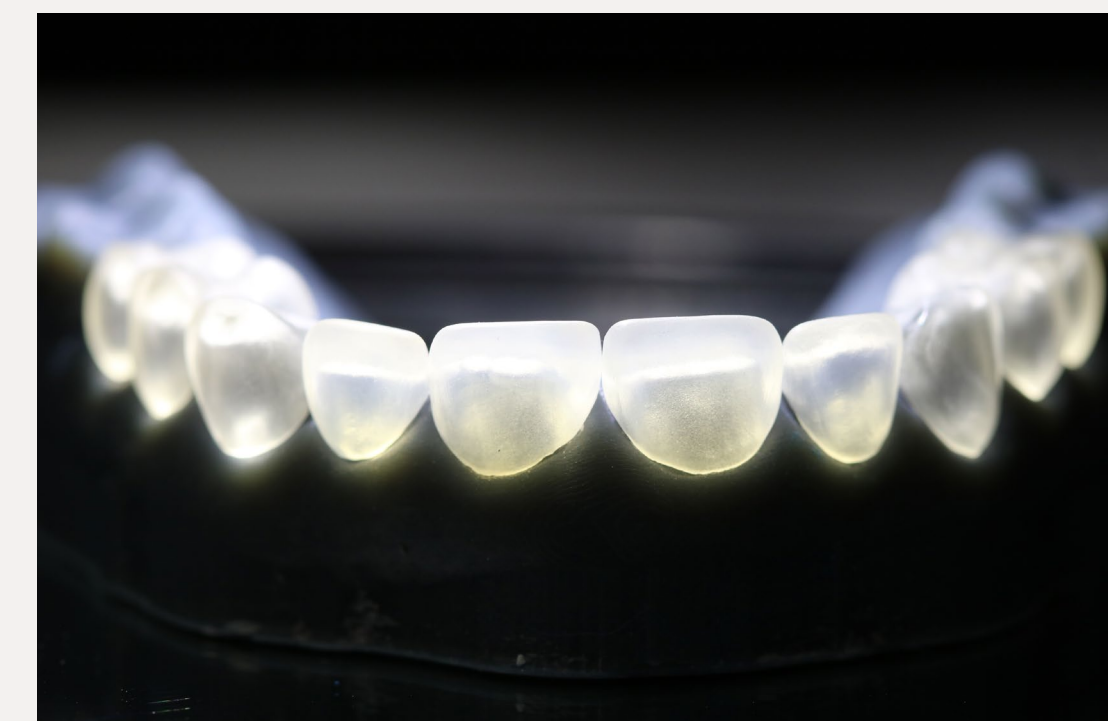Initial situation.



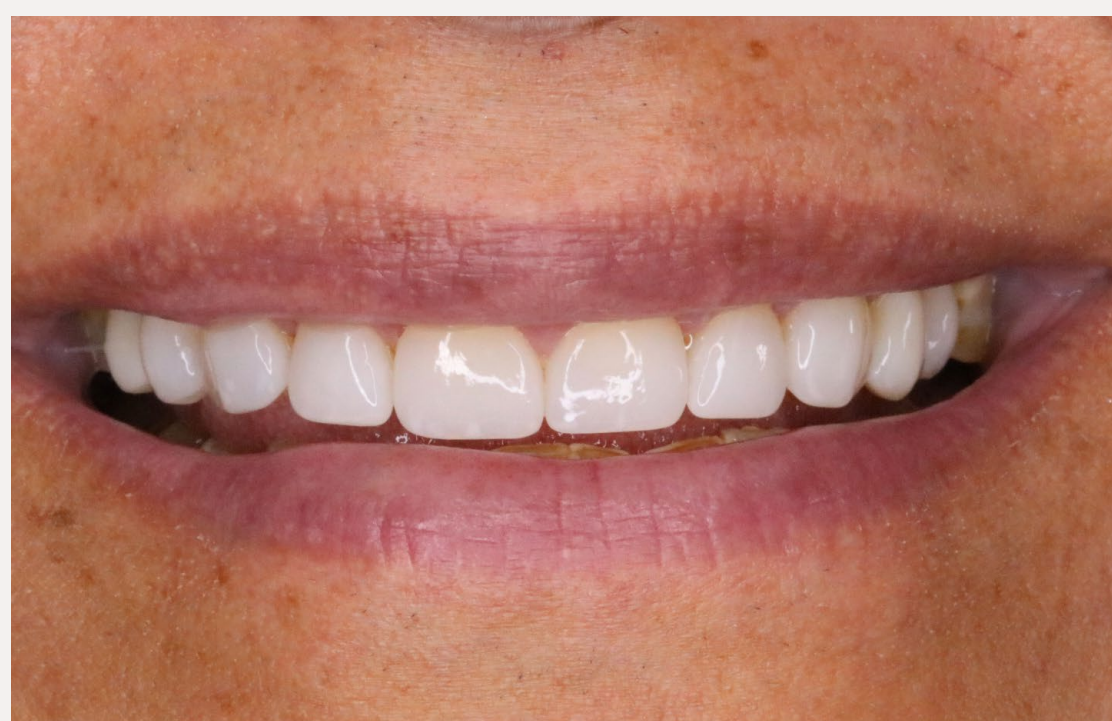Initial impressions: CEREC Primescan was used for the creation of 3D-printed models, the key for ideal mock-ups. CEREC Digital Study models and Bite registration (MIC or CR).



Emotional mock-up is transferred to patient's teeth; after patient approval, we were ready to start the proposed treatment.



Restorations are finished, polished and passively fitted in the printed model. Next step is crystallization of the zirconia-reinforced, high-strength glass-ceramic. All 10 restorations will be placed in the oven.



Final restoration.

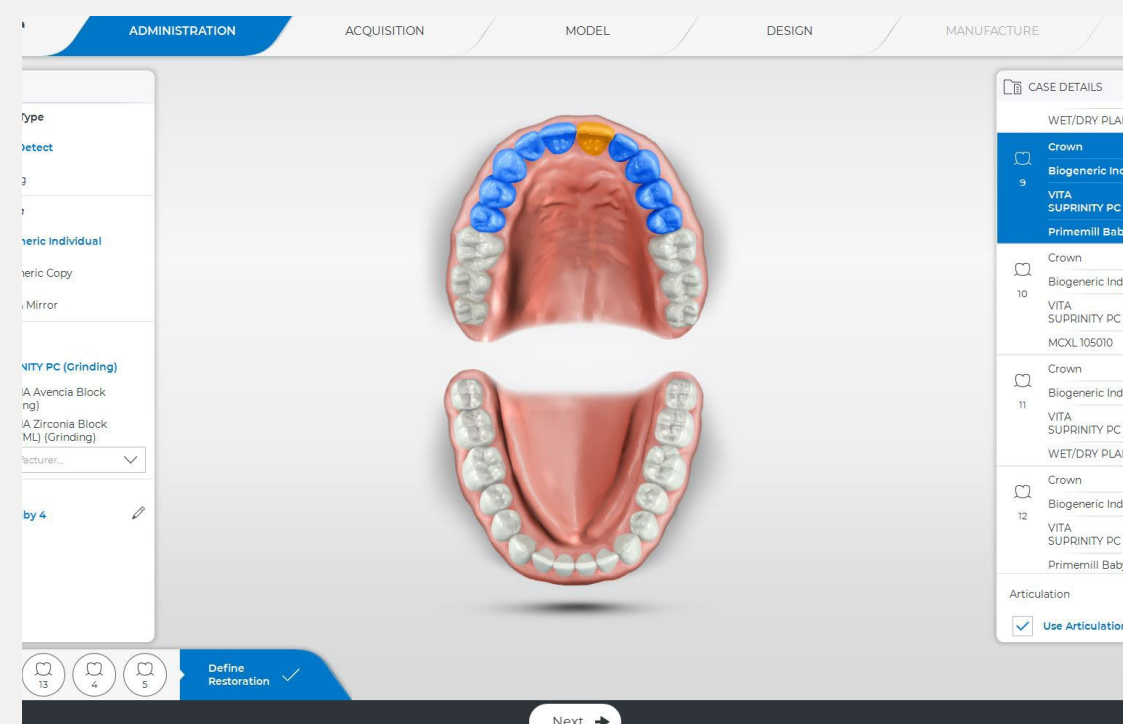


Ten VITA Suprinity PC single crowns – Quadrant rehabilitation in 2 sessions

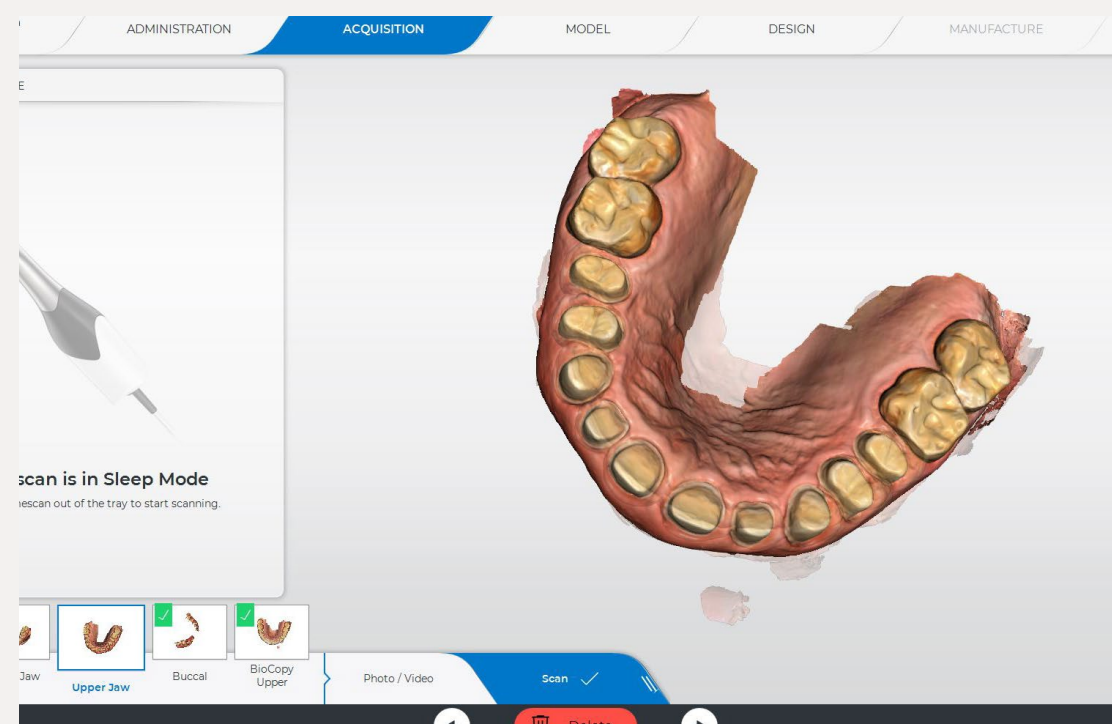


Dr. Daniel Vasquez
San Diego, USA

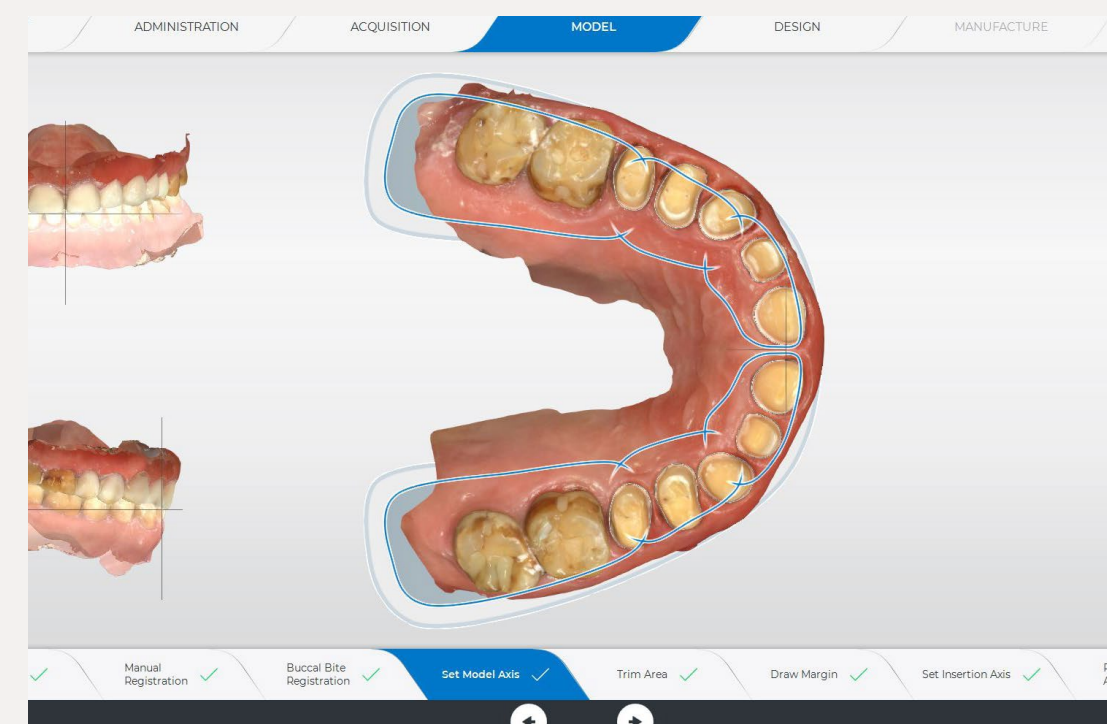
Workflow Images



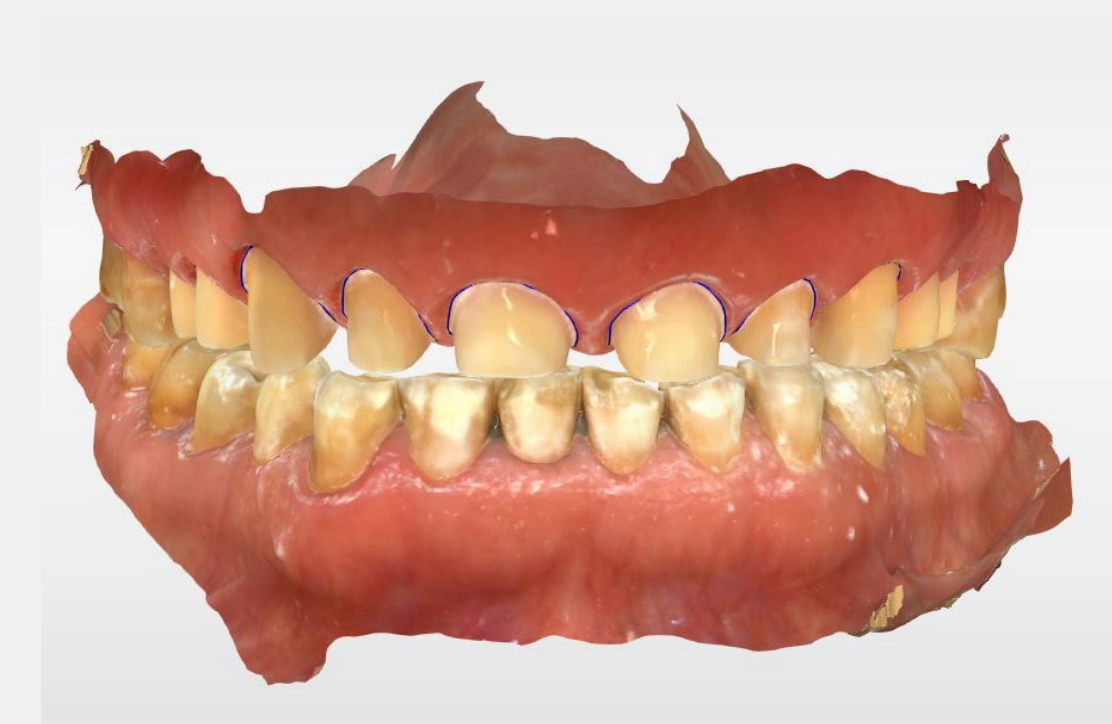Open CEREC Software and in the Administration phase we add restorations and the material to be used, which in this case was VITA Suprinity PC.



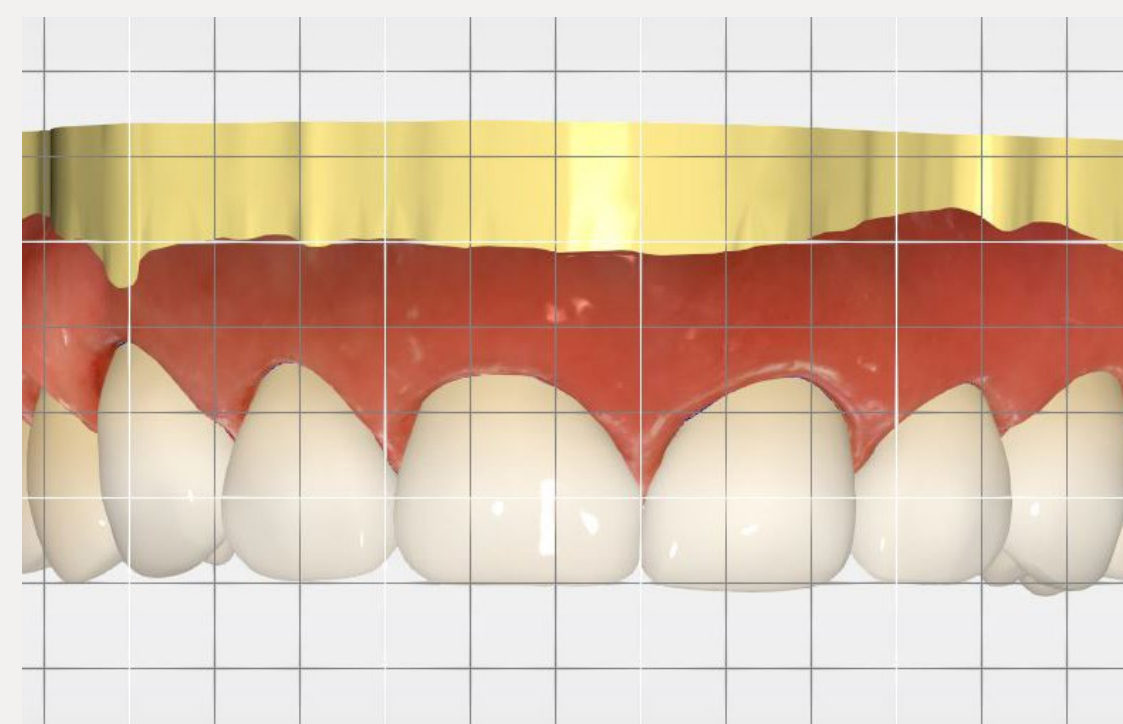
Full arch scan was taken of the preparations and from mock-up, adding a Biocopy folder.



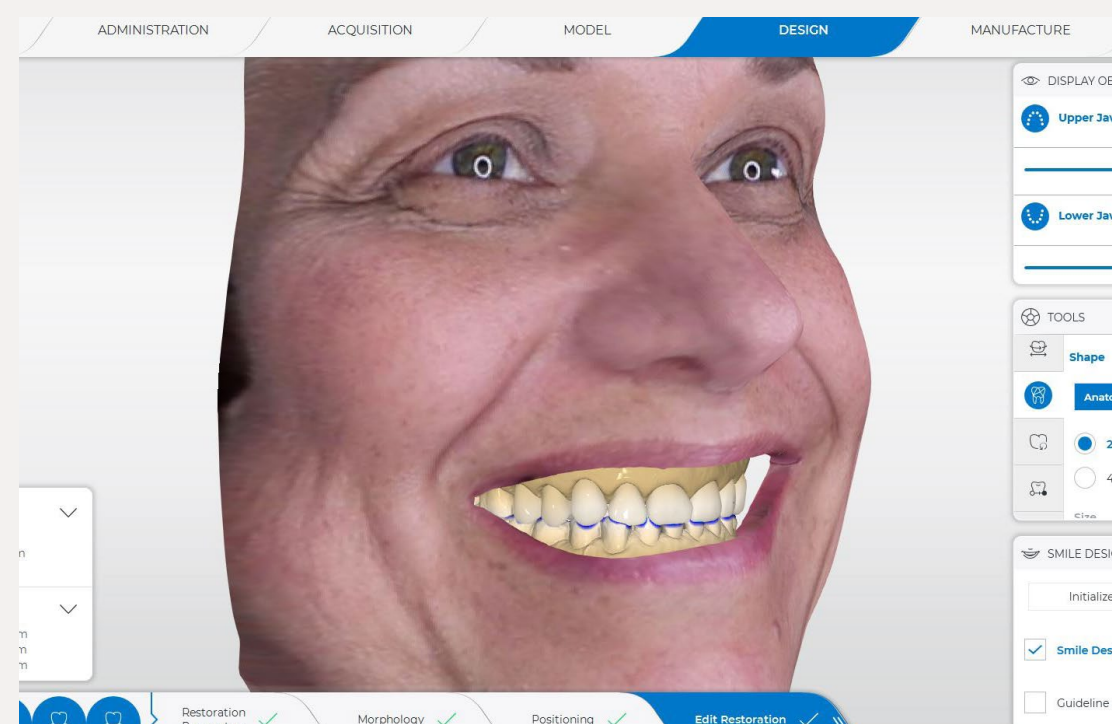
Setting the model axis and insertion axis are key for the best grinding of restorations in the manufacturing phase.



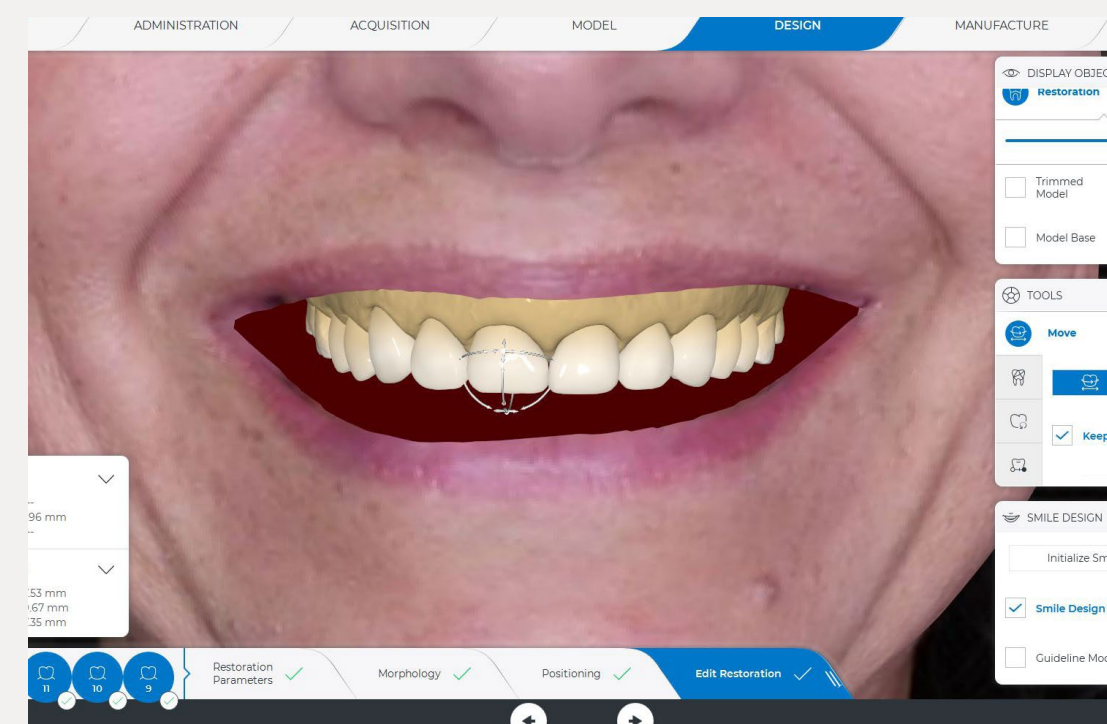
Upper and lower digital models articulated ready for the Design phase.



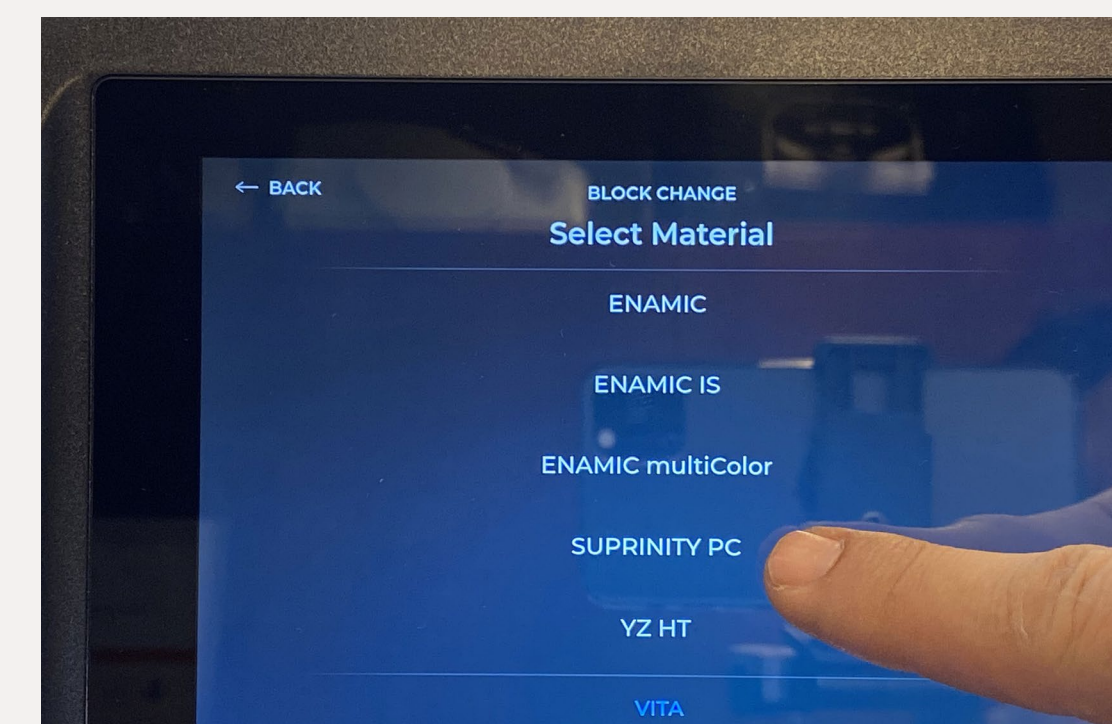
Restoration proposal, using grid to align teeth to length.



After the initial proposal, the CEREC Smile Design application was activated to finalize the design of the restoration using the patient's face and smile.



Design tools are used to perform minor touch-ups in the CEREC Smile Design application.



The new CEREC Primemill was used for the grinding of the restorations. Entering block information using the CEREC Primemill digital touchpad. Restoration with Vita Suprinity PC.



Astra Tech implant placement and an IPS e.max CAD single crown – Second upper premolar



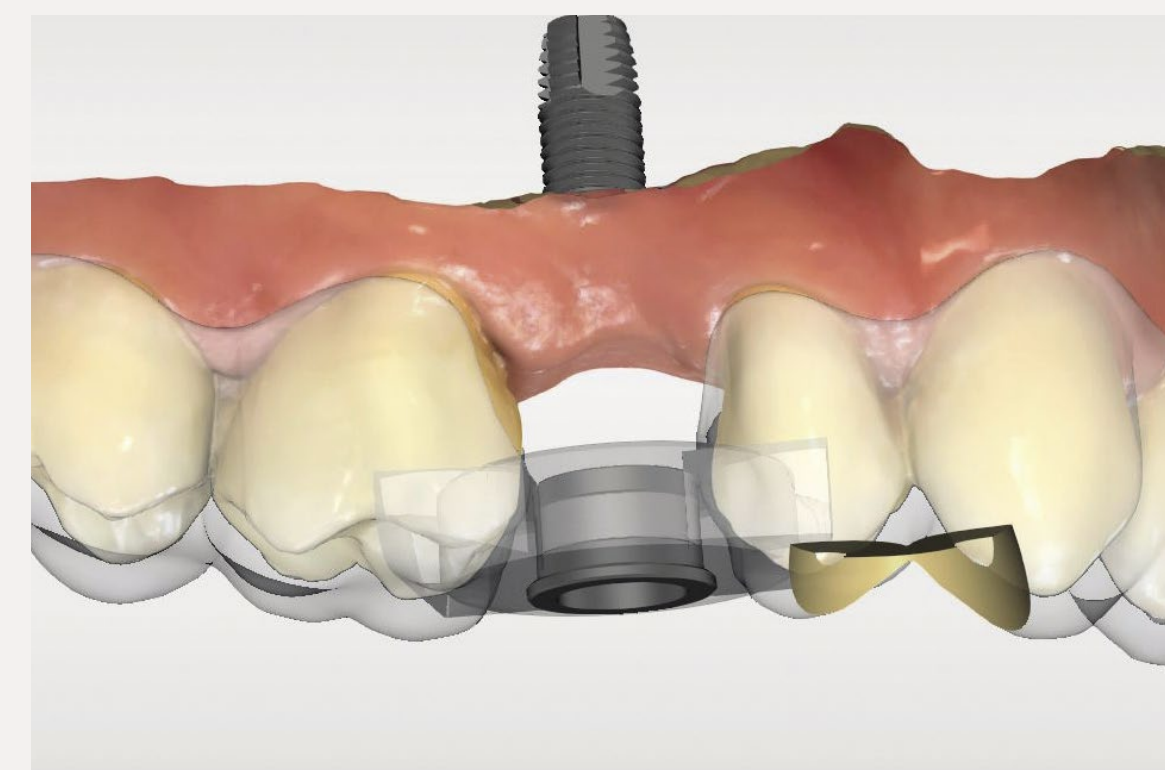
Dr. Andreas Bindl
Zurich, Switzerland

Case Description

A 36-year-old patient came to our practice four months after the extraction of tooth 15 due to a longitudinal fracture. He wanted to close the resulting tooth gap. The patient was healthy and with good oral hygiene. Treatment with an implant or a bridge was considered. The latter was rejected because the abutment teeth were only slightly filled and the substance removal for bridge preparation would have been too great. To check the bone quantity and quality, a three-dimensional radiograph with a volume of 5 cm x 5.5 cm (Orthophos SL) was taken. Based on the findings, because of the limited space and for the most accurate positioning of the implant, the decision was made in favor of a fully guided preparation of the implant site. This was to ensure the exact positioning of the implant and create the conditions for a highly esthetic restoration. After the first intraoral scan with CEREC Primescan, the model data were exported to the implant planning software SICAT Implant 2.0, where they were overlaid with the X-ray data. Implant and sleeve planning could now be completed for the fully guided preparation with the Astra Tech Implant System EV. Based on this, the CEREC Guide 3 surgical guide was designed in the CEREC Software. It was then milled in the CEREC Primemill from a CEREC Guide Bloc Medi. In the final step, the EV ND metal sleeve for the Astra Tech Implant System EV was bonded into the hole in the surgical guide. Both the preparation of the implant site and the insertion of the Astra Tech EV 8.0/4.2 mm implant were completely guided. Since only an 8 mm implant could be placed due to the reduced bone volume, a temporary prosthetic restoration was not used. Instead, a healing abutment was used for transgingival healing. After a healing period of two months, digital impressions were taken with ScanPost and Scanbody. These scans were then used to design a one-piece directly screw-retained implant crown in the CEREC Software, which was subsequently produced in CEREC Primemill (e.max CAD, Ivoclar Vivadent). For optimum esthetics, the crown was given a crystallization firing first, including color characterization. In addition, there were two more firings, with another color characterization and application of the glaze material. A total of two consultations were required for this restoration.

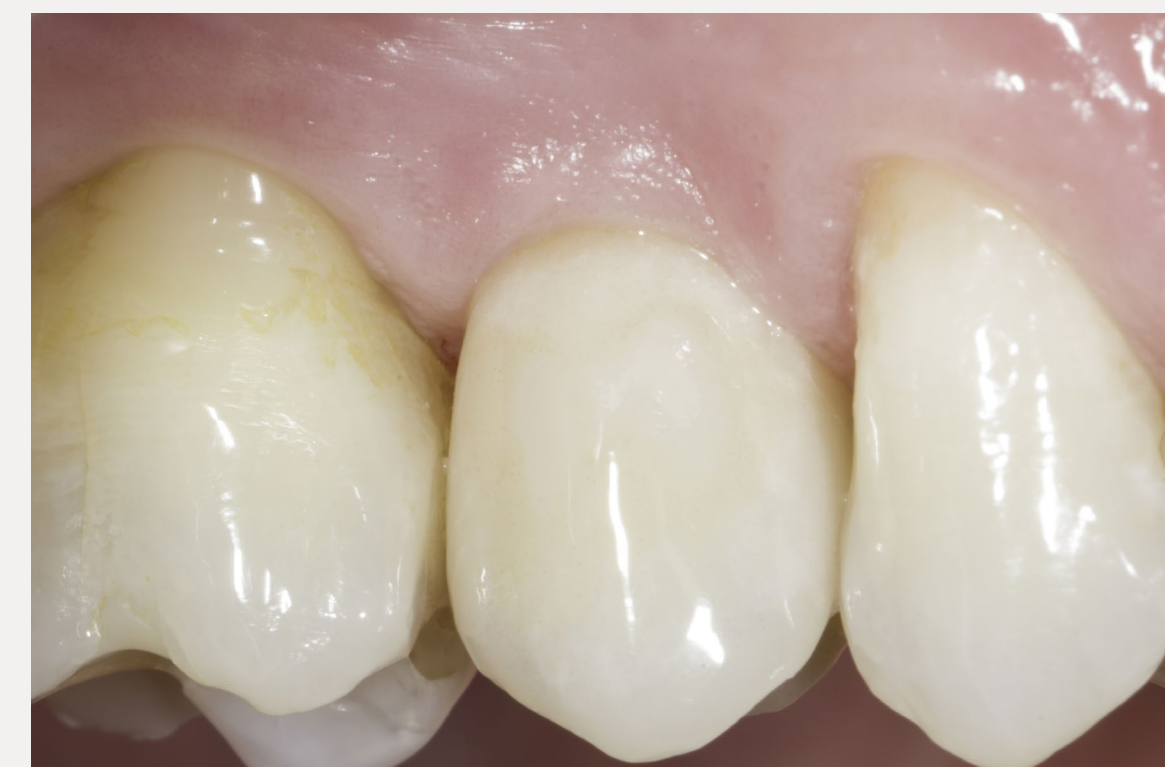Discussion

The implant and screw-retained crown made of a high-quality glass-ceramic material provided the patient with a highly esthetic and long-term stable restoration without the need to prepare healthy natural tooth enamel. The guided procedure with CEREC Guide 3 provided a high level of safety during preparation and insertion. After six months, the patient presented with healthy gingiva and bone conditions.



Before:

Tooth 15 was extracted four months before due to a longitudinal fracture. Patient wanted to close the resulting tooth gap.



After:

A crown made of a high-quality glass-ceramic material provided the patient with a highly esthetic and long-term stable restoration.



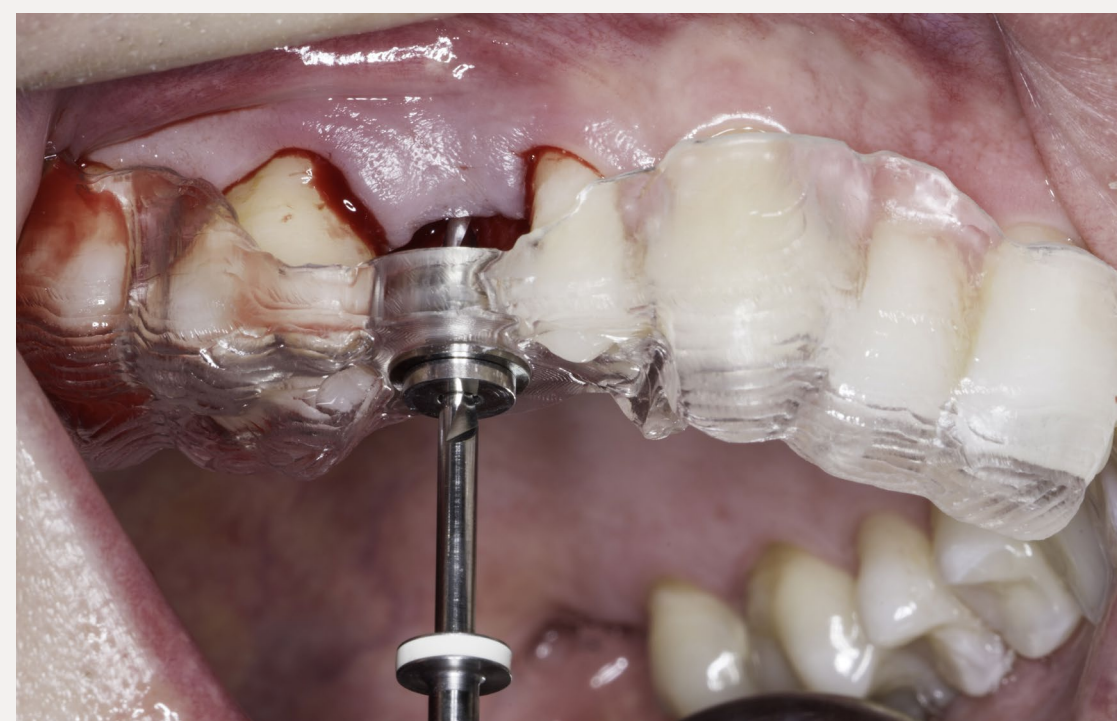

Astra Tech implant placement and an IPS e.max CAD single crown – Second upper premolar

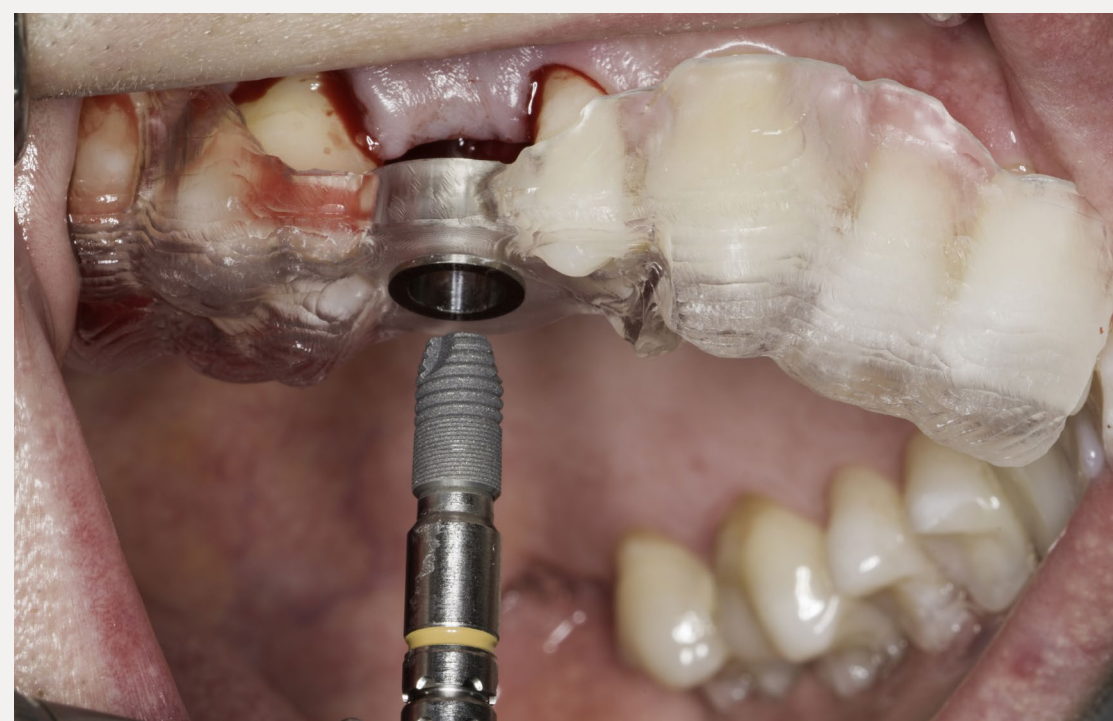

Dr. Andreas Bindl
Zurich, Switzerland

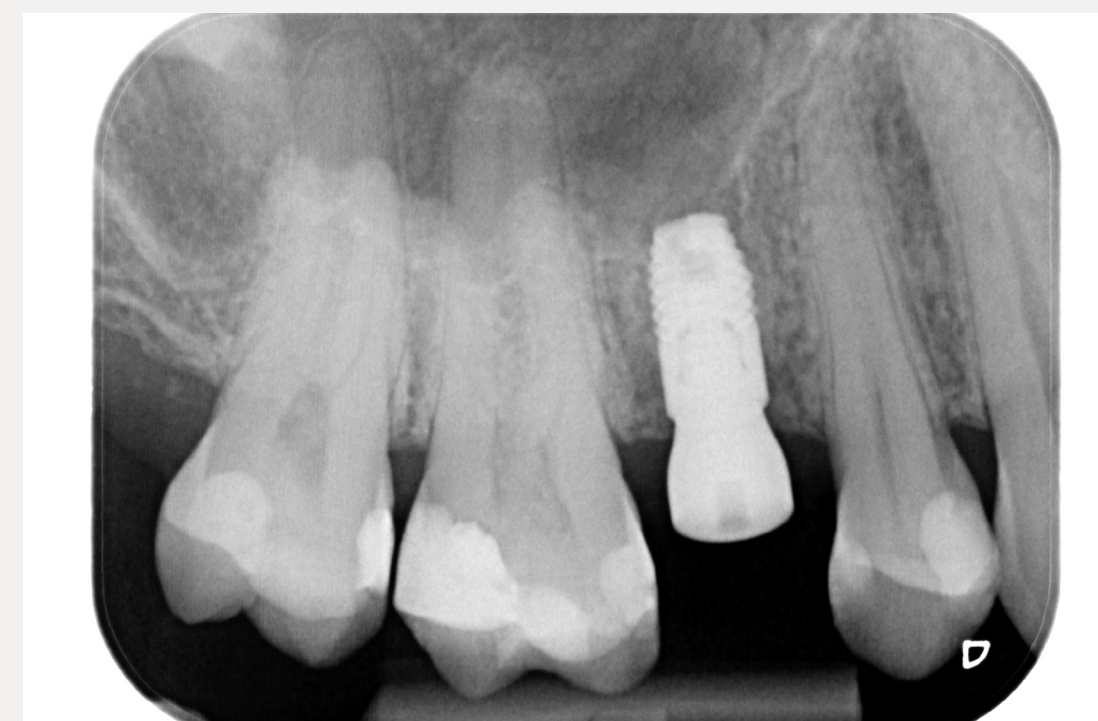Clinical Images



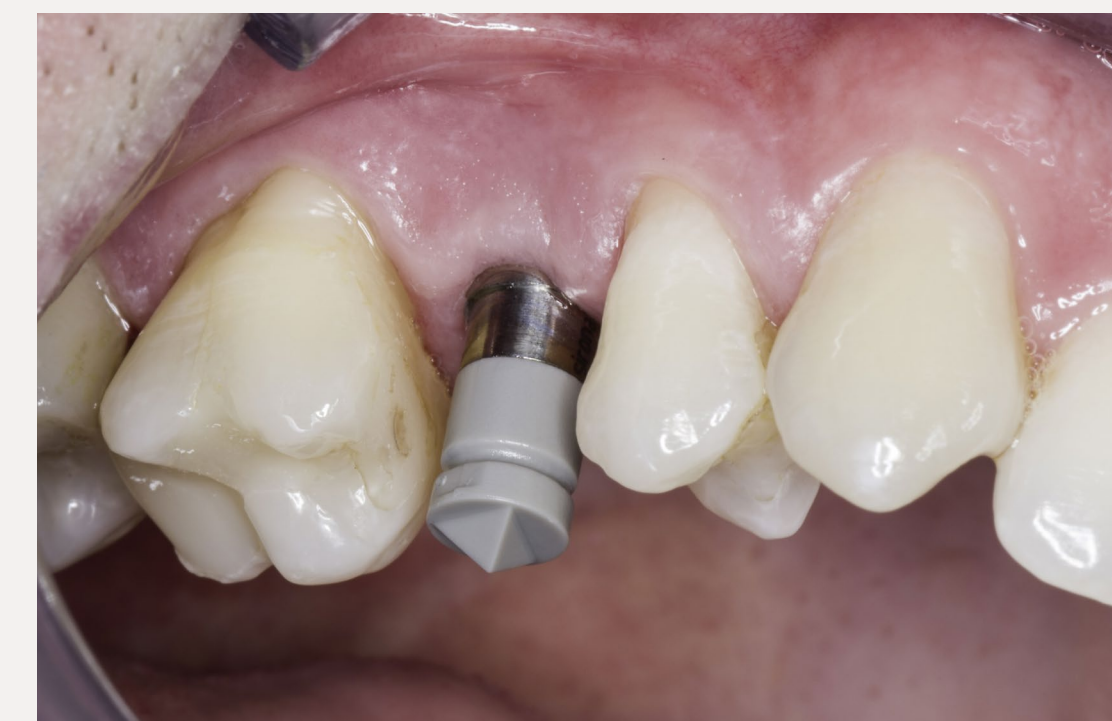Guided preparation with the Astra Tech Implant System EV.



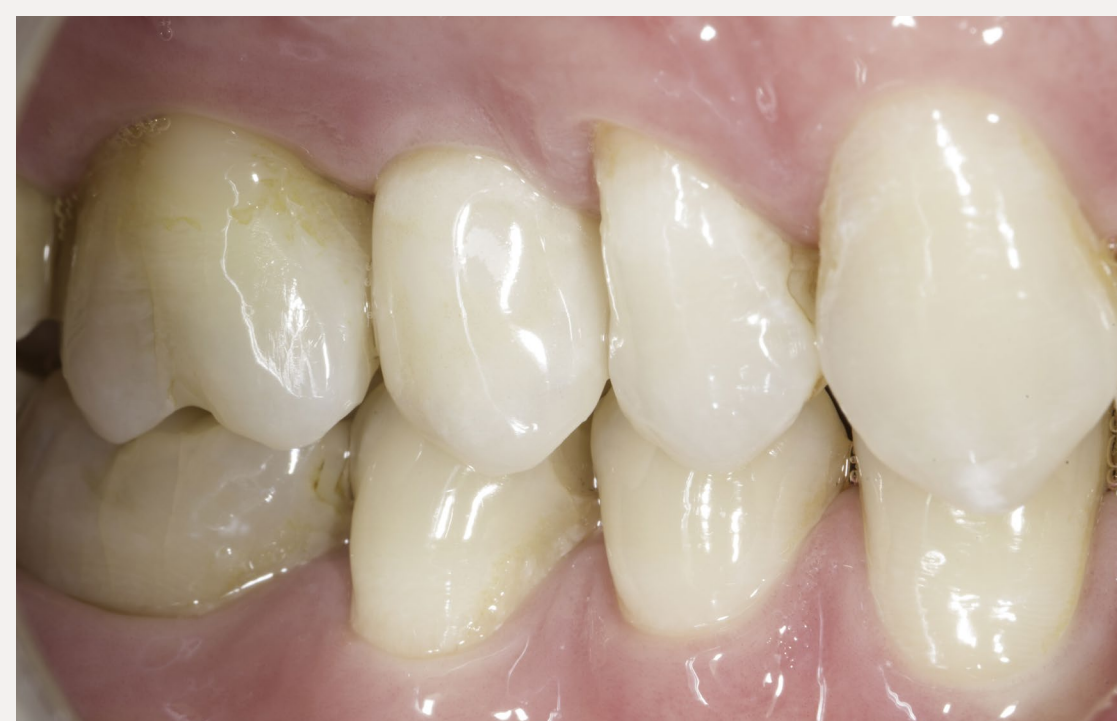Guided insertion of the implant with the Astra Tech EV surgery kit.



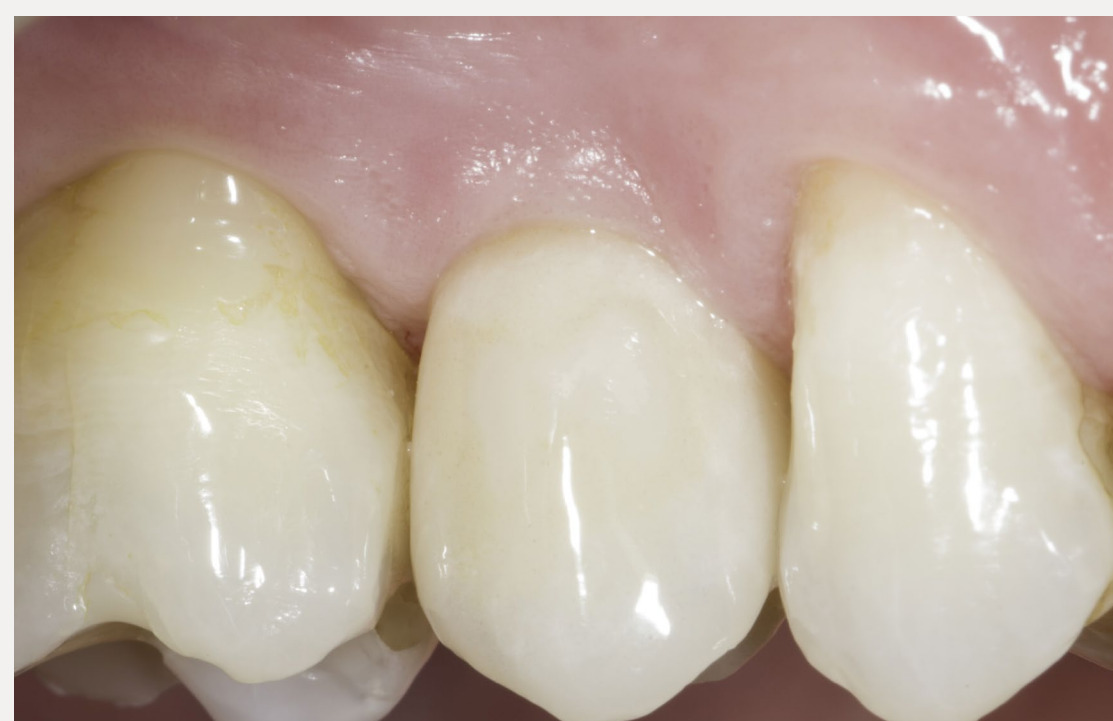X-ray image after placing the implant. Transgingival healing after mounting a healing abutment.



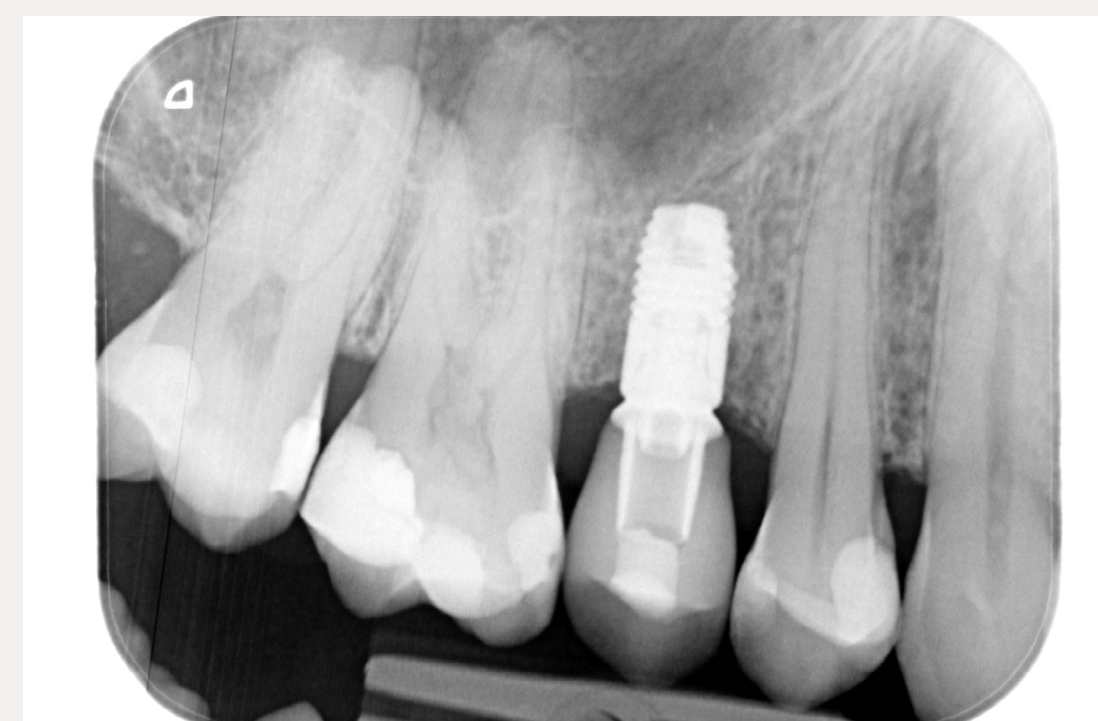After a healing period of 2 months, the ScanPost and Scanbody were mounted to record the position of the implant using the Primescan.



Directly screw-retained implant crown made of e.max CAD.



Healthy gingiva conditions around the crown after a lying period of 6 months.



Healthy bone conditions around the implant after a lying period of 6 months.

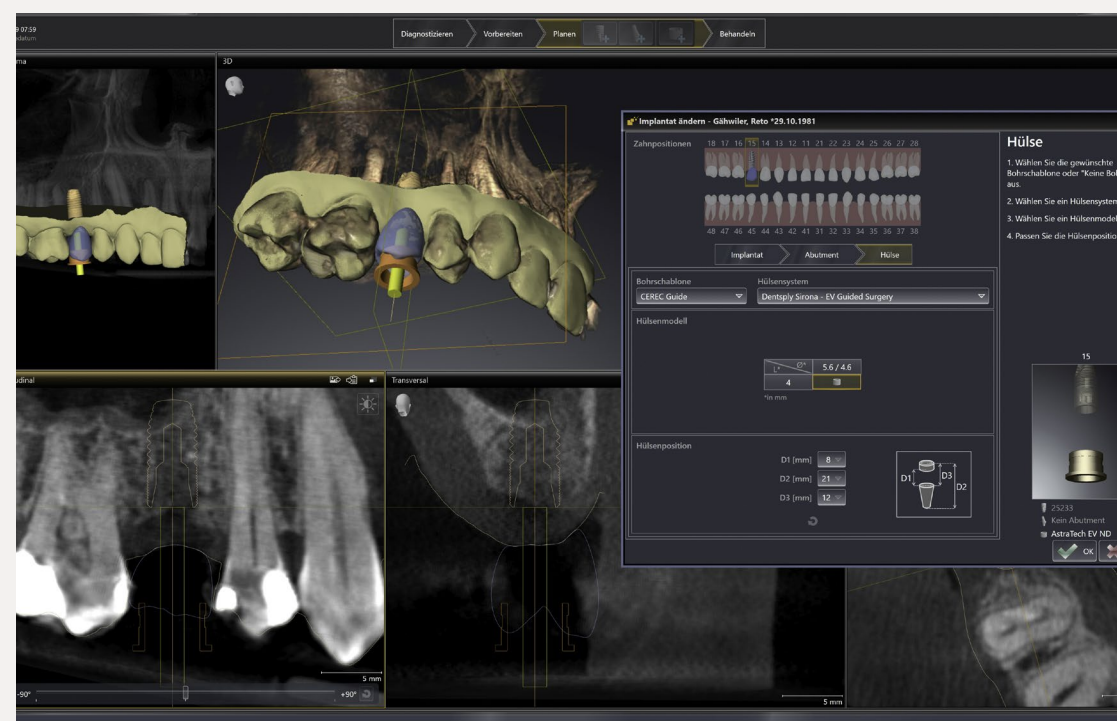


Astra Tech implant placement and an IPS e.max CAD single crown – Second upper premolar

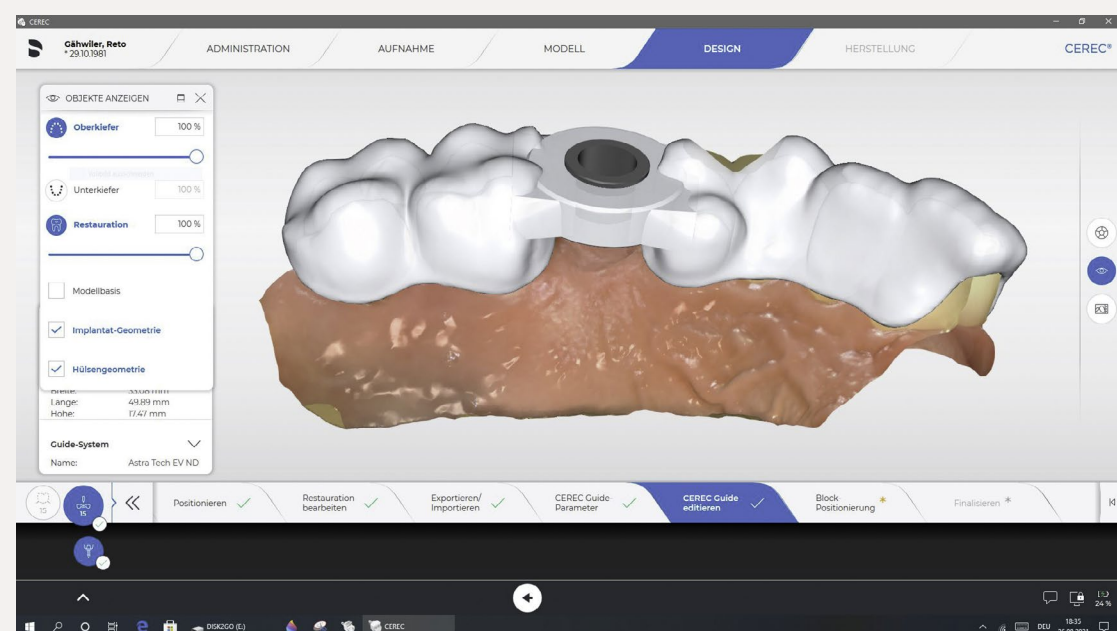


Dr. Andreas Bindl
Zurich, Switzerland

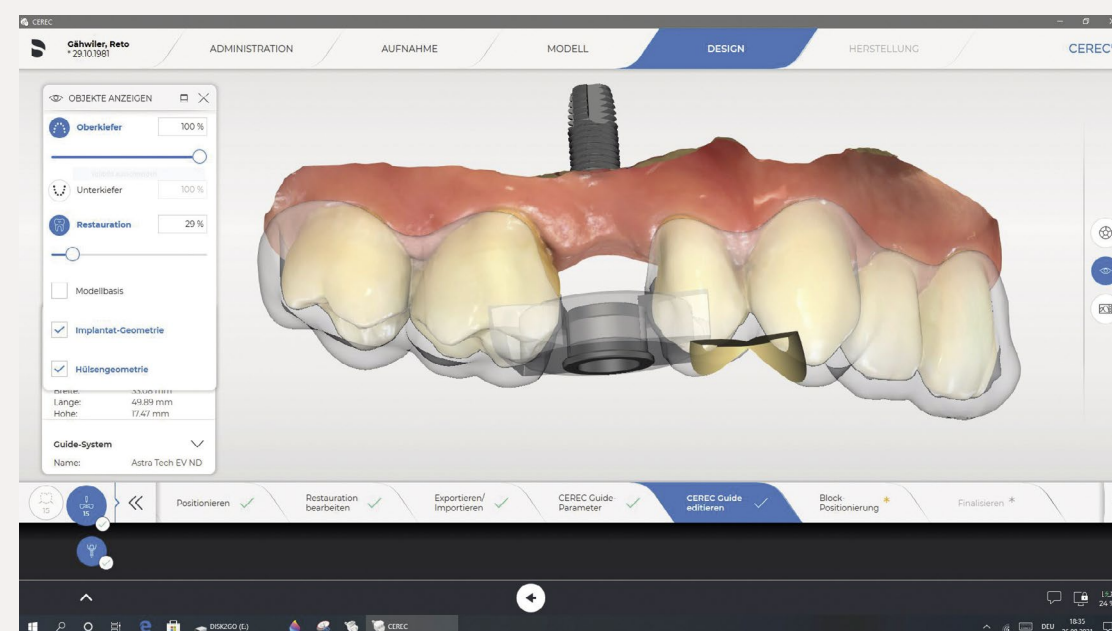Workflow Images



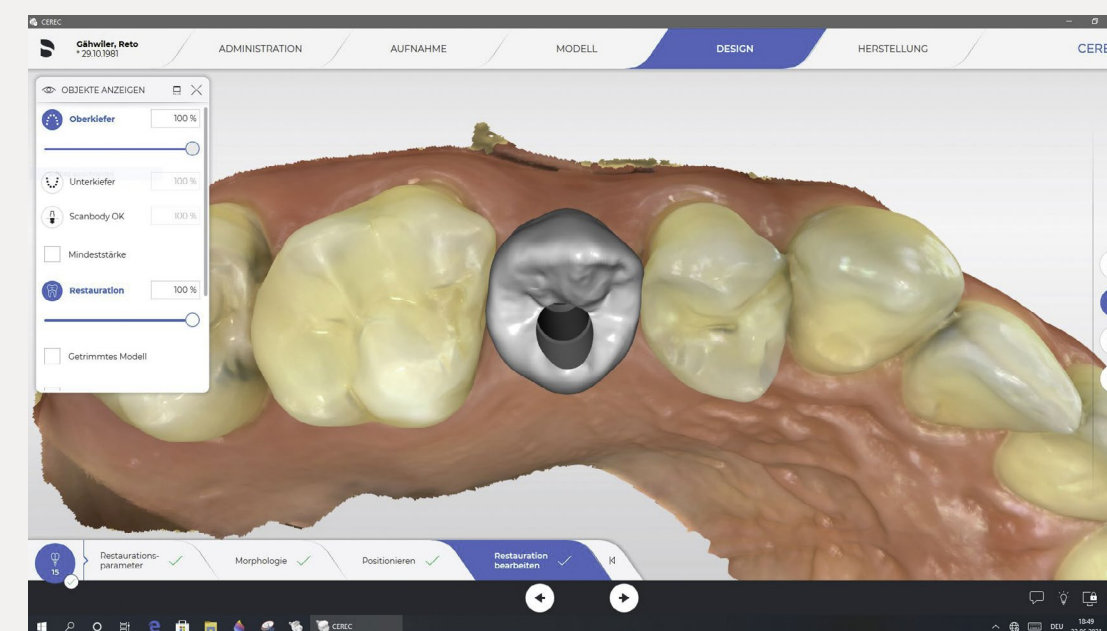
SICAT Implant 2.0: implant and sleeve planning for fully guided preparation with the Astra guided system.



After importing the implant and sleeve planning, the CEREC Guide 3 drill template is designed using CEREC Software.



Semi-transparent representation of the CEREC Guide 3 drill template. The metal sleeve is shown, which is glued into the perforation after milling the surgical template.



Design of a one-piece direct screw-retained implant crown with CEREC Software.



Ankylos implant placement and two Celtra Duo crowns – Upper lateral incisors in 180 minutes



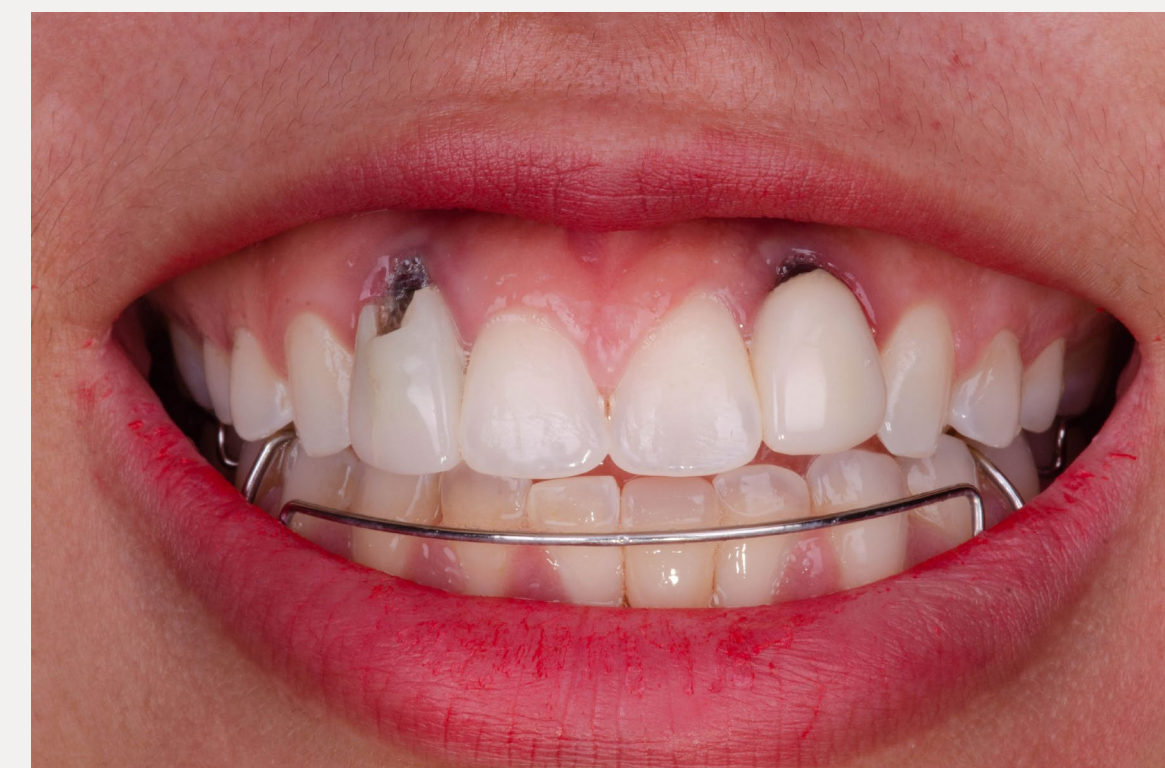Dr. Fernando Peixoto Soares
São Paulo, Brazil

Case Description

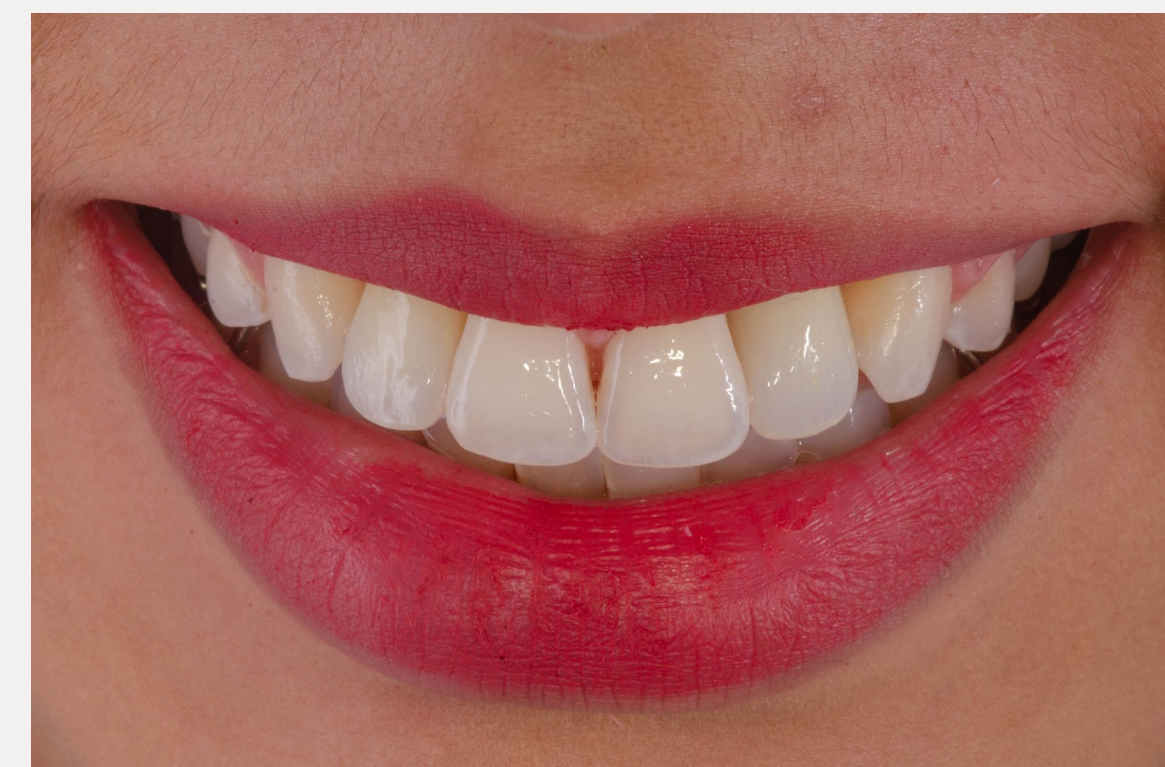A 22-year-old female patient came to my practice. Her medical history revealed that teeth 12 and 22 were missing due to dental agenesis and had been replaced by implants. This solution did not please the patient at all. She hid her smile and felt inhibited around company. She wanted to be able to laugh again with confidence. Restorations in the anterior region pose a particular challenge, especially from an esthetic point of view. In this case, the absence of teeth 12 and 22 and the bone loss caused by the first implants, which had not been optimally placed, also had to be taken into account. After their removal, augmentation with a bone graft and a collagen membrane (Bio-Oss, Bio Gide, Geistlich) was necessary. In a second surgical step six months later, two Ankylos implants (A9) were inserted and a soft tissue graft was placed. The patient then received chairside fabricated temporaries. After a further three months, I provided the patient with a final CEREC restoration. I took a digital impression with CEREC Primescan in conjunction with the TiBase Ankylos CEREC GH2, including ScanPost and Scanbody, and then designed two crowns in the CEREC Software, which fit excellently into the patient's dentition. Both crowns were then ground from a Celtra Duo HT block in shade A1 using CEREC Primemill. After staining and subsequent glazing in the CEREC SpeedFire, the restorations were cemented onto a custom zirconia abutment (inCoris Meso with TiBase), milled in the CEREC Primemill, and sintered in the CEREC SpeedFire. These steps were carried out in a single visit, which lasted a total of approximately 180 minutes.

Discussion

For an adequate result from a functional and esthetic point of view, the removal of both previous implants was unavoidable. The treatment options were an orthodontic gap closure, a restoration with bridges, or two single-tooth restorations with implants and chairside-fabricated crowns, the latter of which the patient preferred. In the end, she was able to receive two completely new restorations in only three visits and was very happy with her new smile.



Before:
Initial situation.



After:
Final smile.



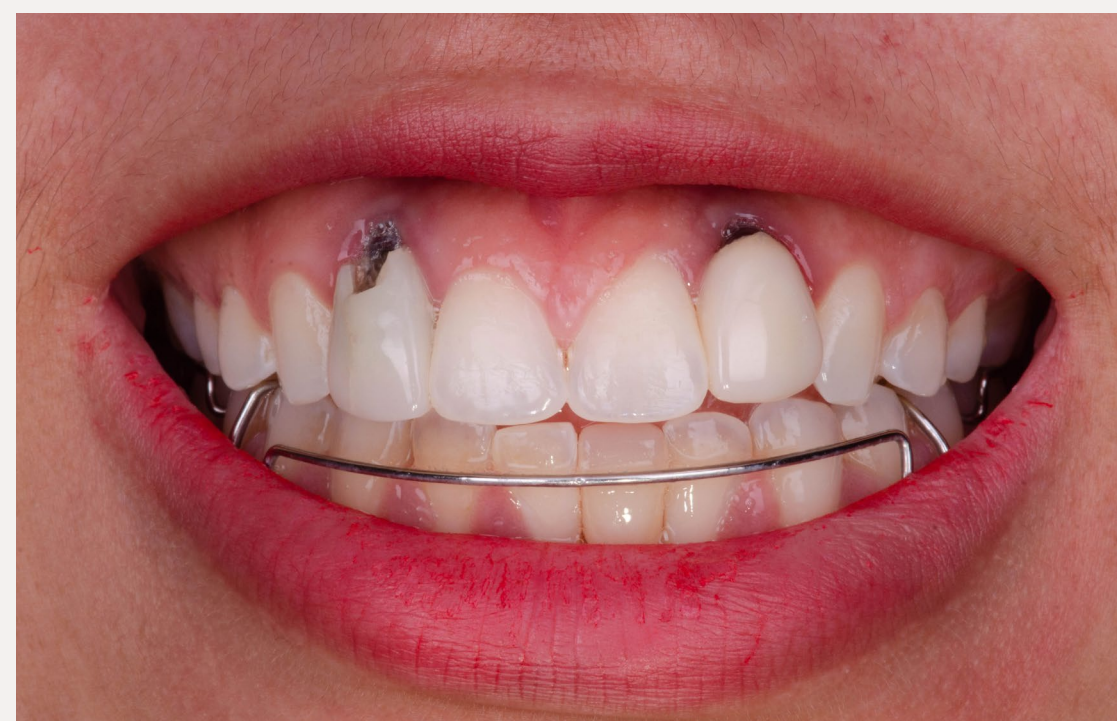

Ankylos implant placement and two Celtra Duo crowns – Upper lateral incisors in 180 minutes

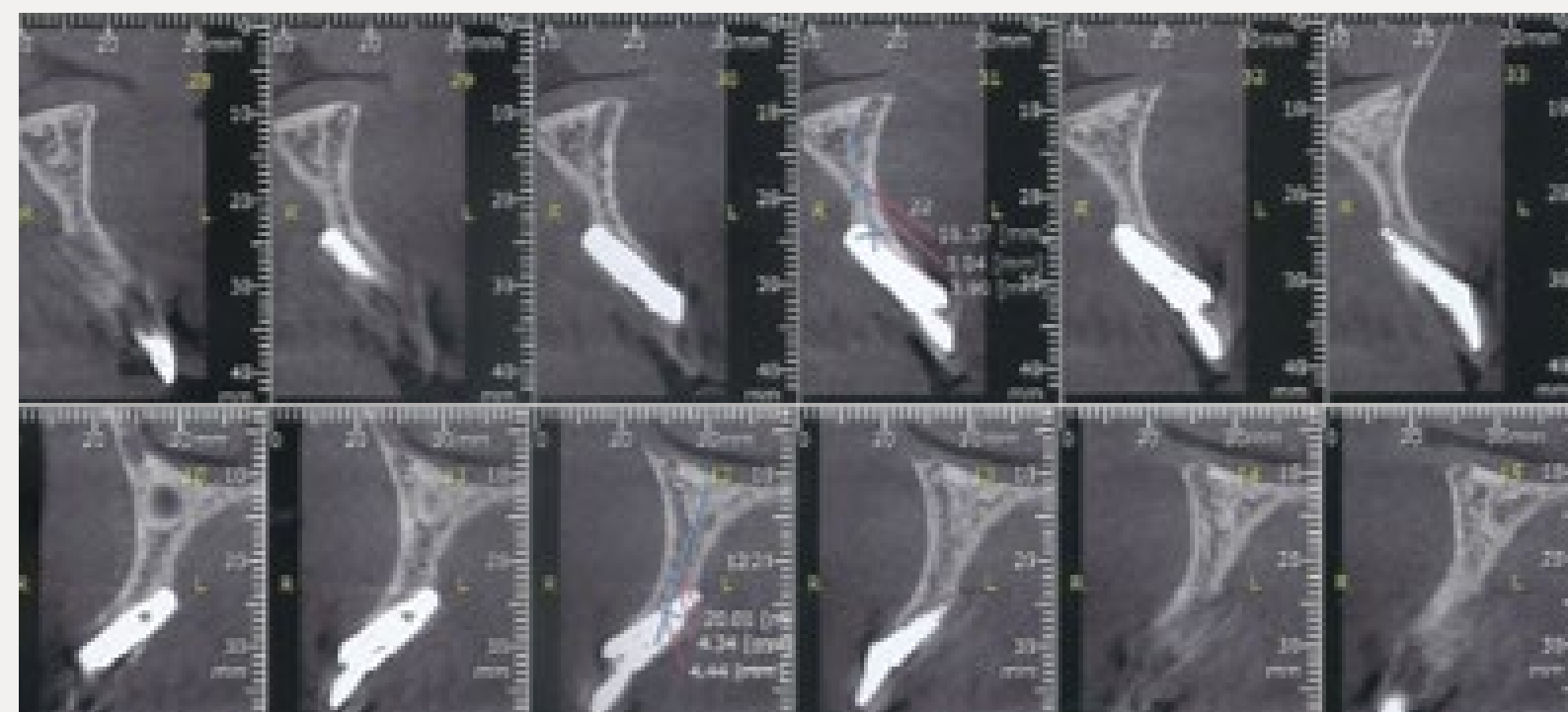


Dr. Fernando Peixoto Soares
São Paulo, Brazil

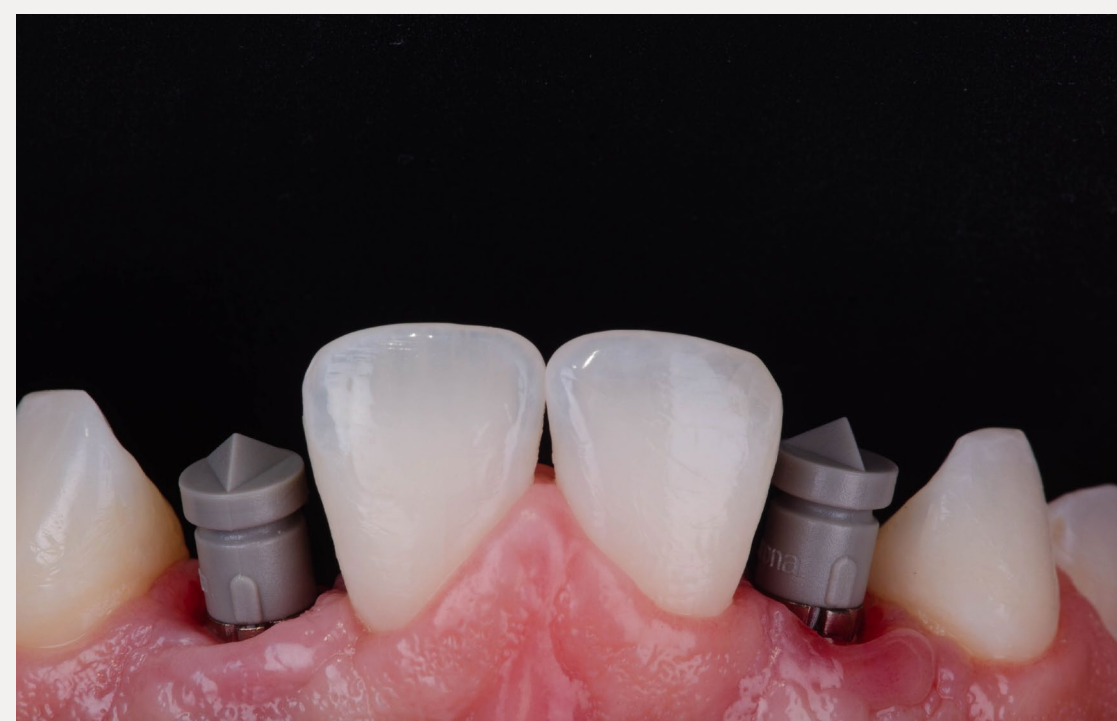Clinical Images



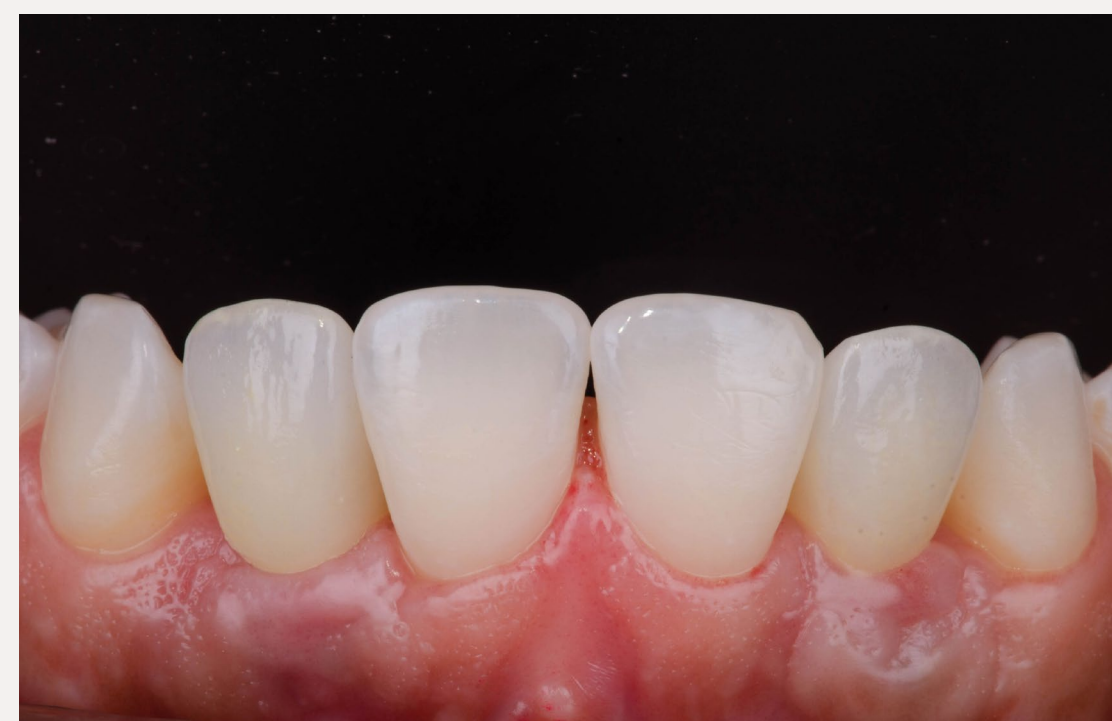Initial situation.



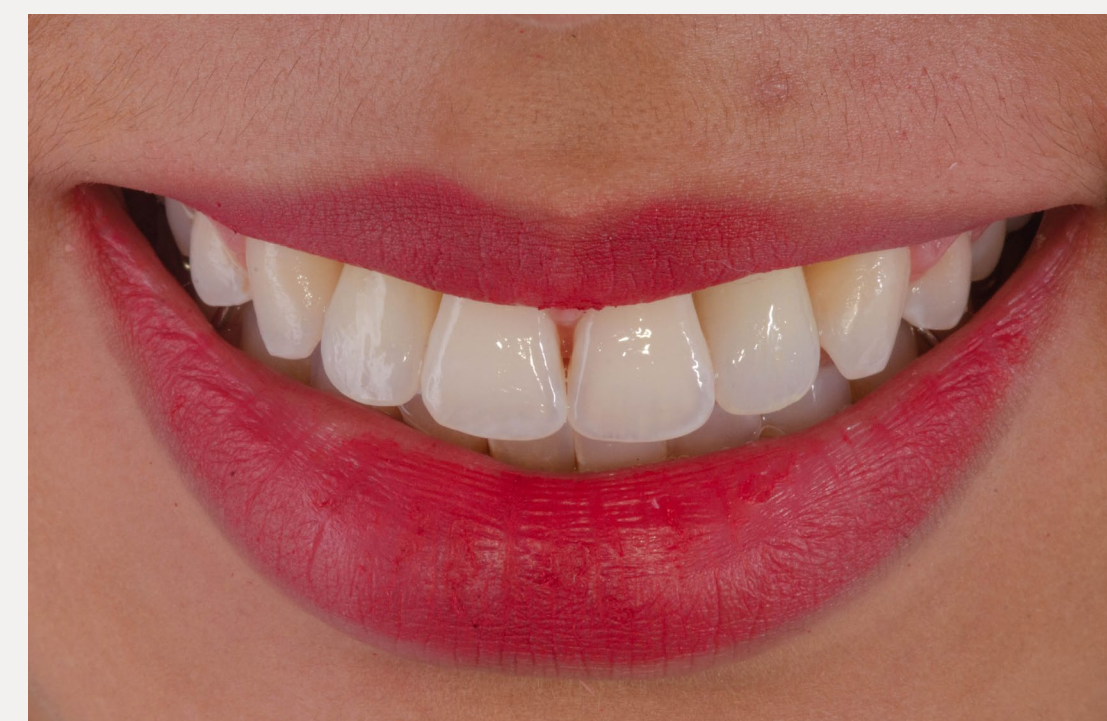The 3D X-ray demonstrates the suboptimally placed implants.



Nine months after removal of the old implants and three months after placement of the new implants. Scan of the new implant position with ScanPosts.



Final restoration of teeth 12 and 22.



Final situation.

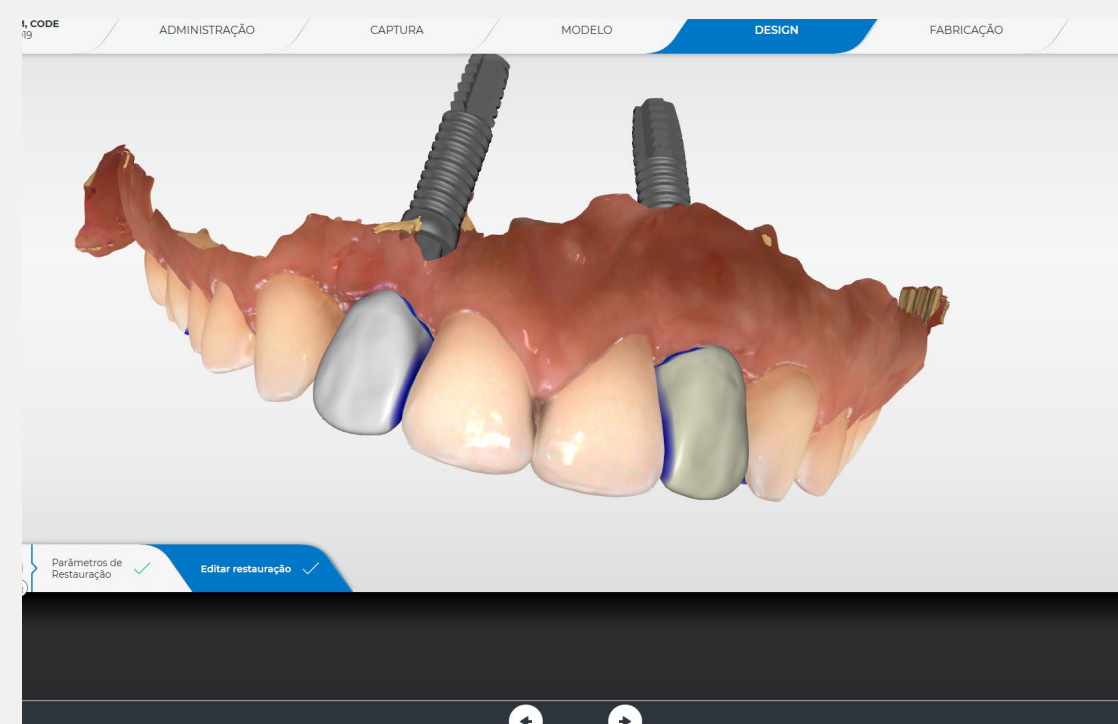


Ankylos implant placement and two Celtra Duo crowns – Upper lateral incisors in 180 minutes




Dr. Fernando Peixoto Soares
São Paulo, Brazil

Workflow Images



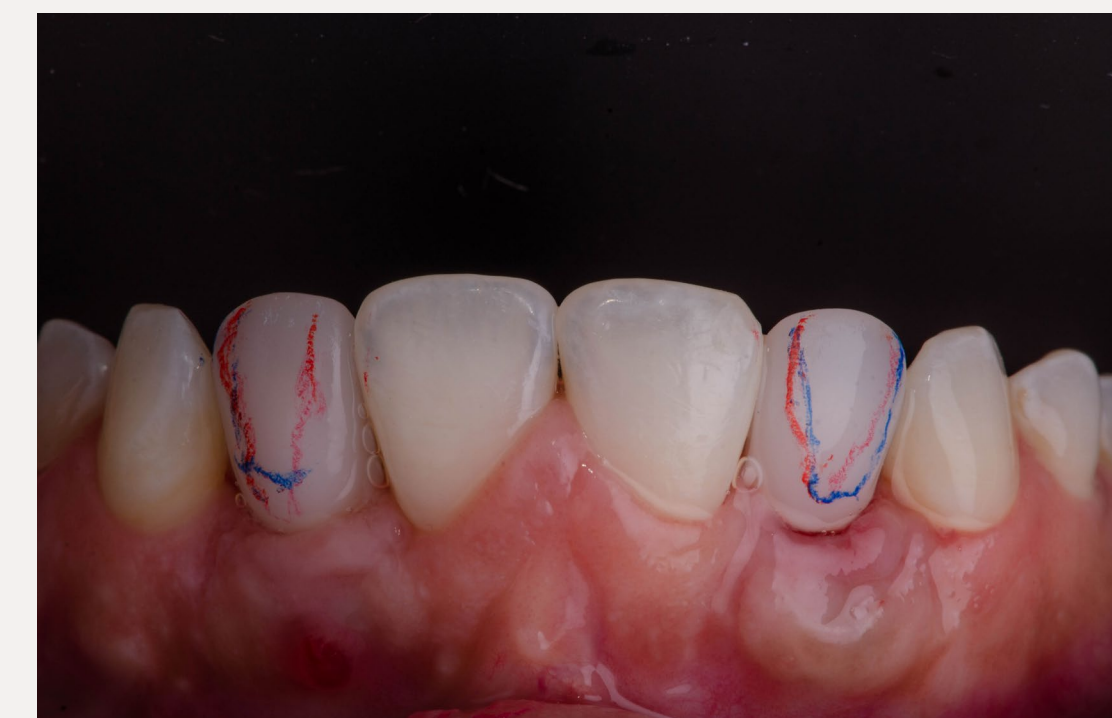Design of the crowns in the CEREC Software.



Milled zirconia abutment.



Adjustment of the Celtra Duo crown on the inCoris meso abutment.



Marking for the esthetic adjustment of the crowns.



Ankylos implant placement and IPS e.max CAD single crown – First upper premolar in 90 minutes



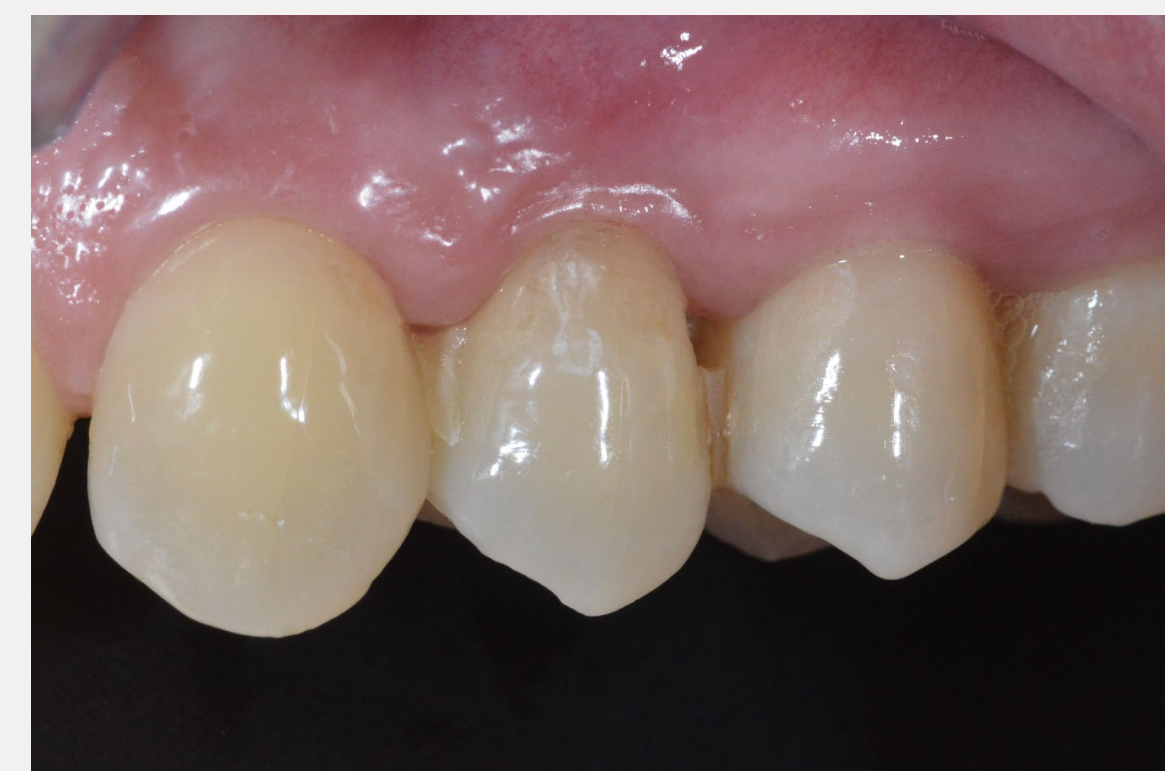Dr. Carlos Repullo
Sevilla, Spain

Case Description

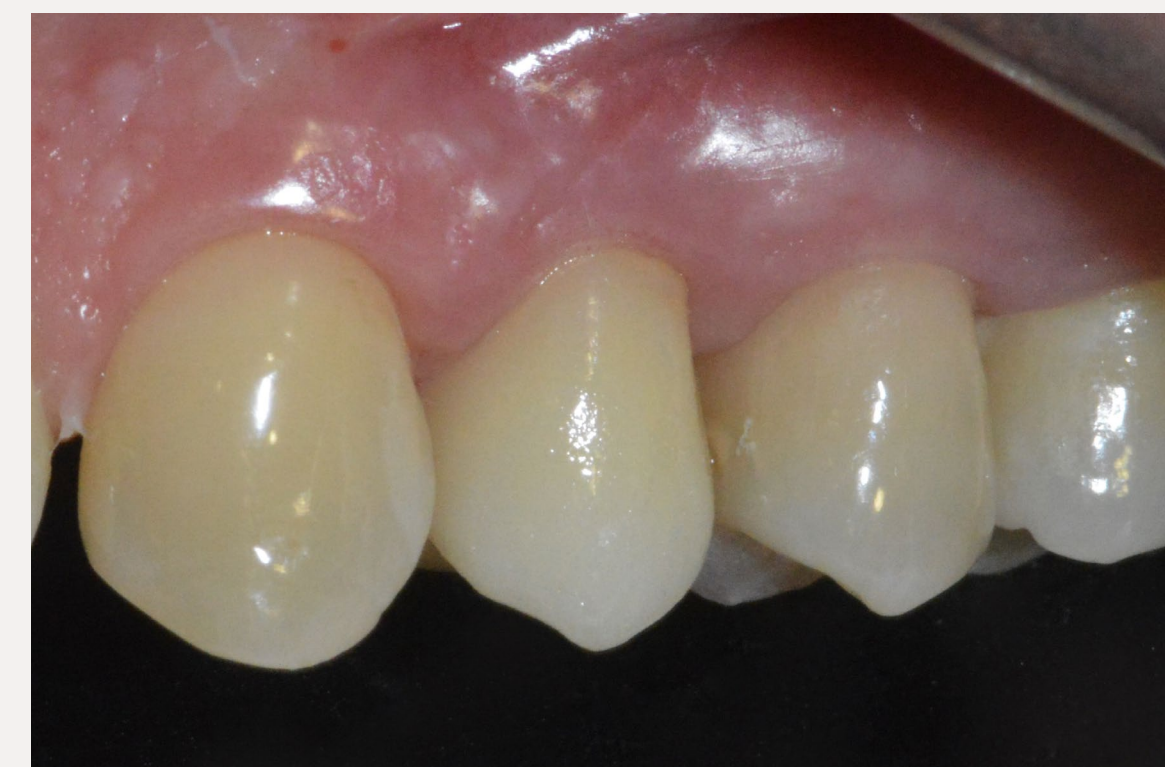A 56-year-old female patient came to my practice with pain and some loosening of tooth 24. After an initial examination, a CBCT scan was performed with Orthophos SL, which determined that a horizontal root fracture and a periapical infection were the cause of the problems. Together with the patient, it was decided to extract the fractured tooth and immediately restore the gap with an implant. At the next appointment, the tooth was gently removed. An implant (Ankylos A11) and a gingiva former were placed in the cleaned bony extraction socket and filled with particulated bone (Symbios Xenograft granules). The premolar crown was subsequently trimmed and reused as a temporary solution, while retaining the soft tissue contour. After a three-month healing period, the patient's final prosthetic restoration was started. Three scans of the maxilla were taken with CEREC Primescan: one scan of the temporary restoration (natural crown), which served as a reference for the permanent crown to be fabricated; another to record the soft tissue contour; and a third scan with the IO FLO-S scan body. In addition, a mandibular scan and a bite registration were carried out. CEREC Software was used for the design of the restoration in which the Biocopy setting was utilized. The gingival mask functioned as a reference for the emergence profile. The lithium disilicate crown (e.max CAD A14 block, Ivoclar Vivadent) was produced using CEREC Primemill. After crystallization (CEREC SpeedFire) and characterization, the restoration was cemented onto an Ankylos TitaniumBase. The crown itself was screwed to the implant and the screw channel filled with composite. This appointment took only a total of 90 minutes. At the follow-up visit five days later, the patient was very satisfied, saying, "It is as if nothing happened at all."

Discussion

A possible alternative would have been a conservative treatment approach with root canal treatment and stabilization of tooth fragments. However, the patient rejected this due to the relatively high risk of failure as well as a previous negative experience. Restoration with a bridge after extraction of the affected tooth was also ruled out. The advantage of the selected implant treatment, especially using the natural tooth crown as a temporary restoration, was the preservation of esthetics and the natural soft tissue contour.



Before:
Initial situation.



After:
Final result.



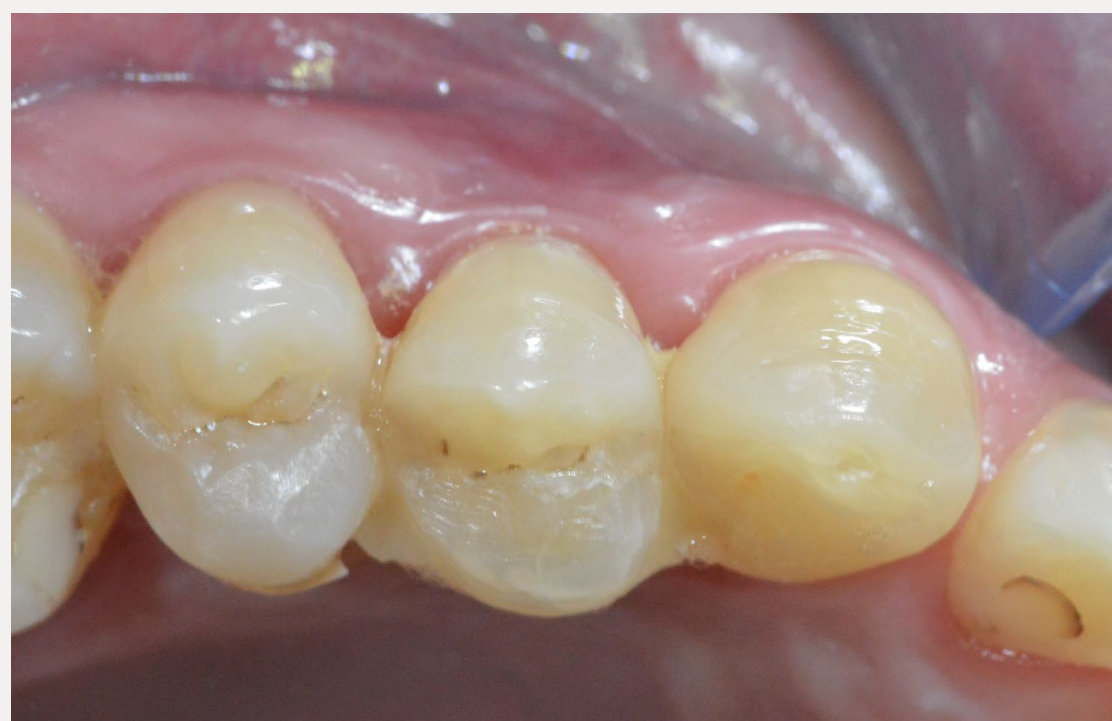

Ankylos implant placement and IPS e.max CAD single crown – First upper premolar in 90 minutes

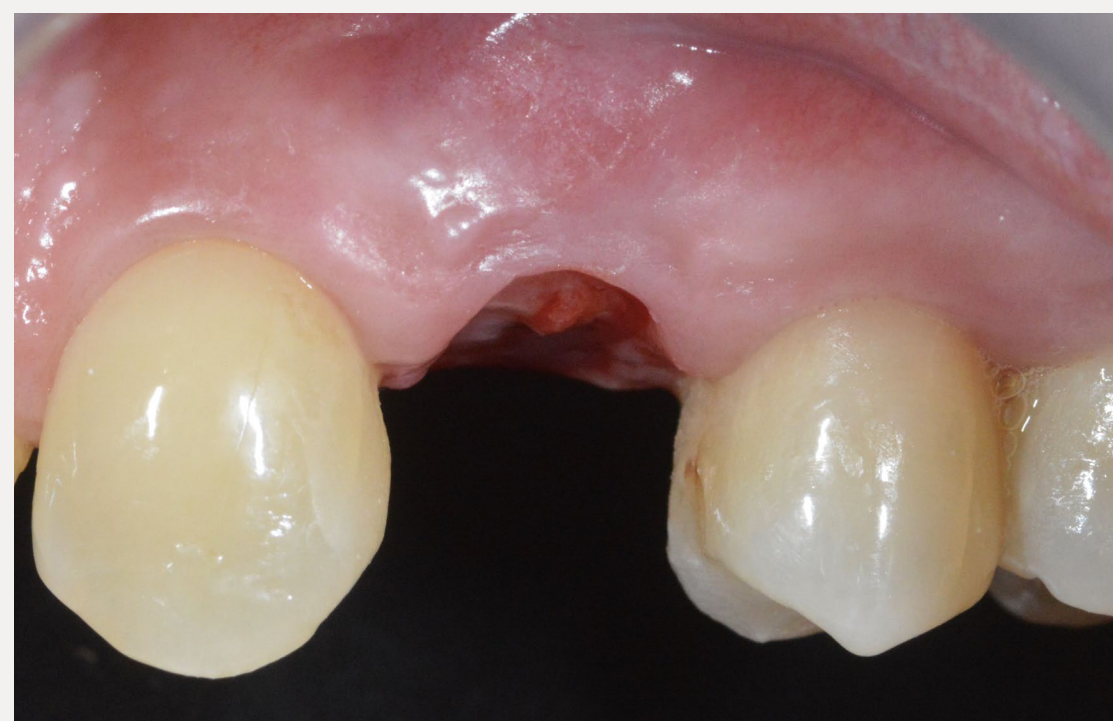

Dr. Carlos Repullo
Sevilla, Spain

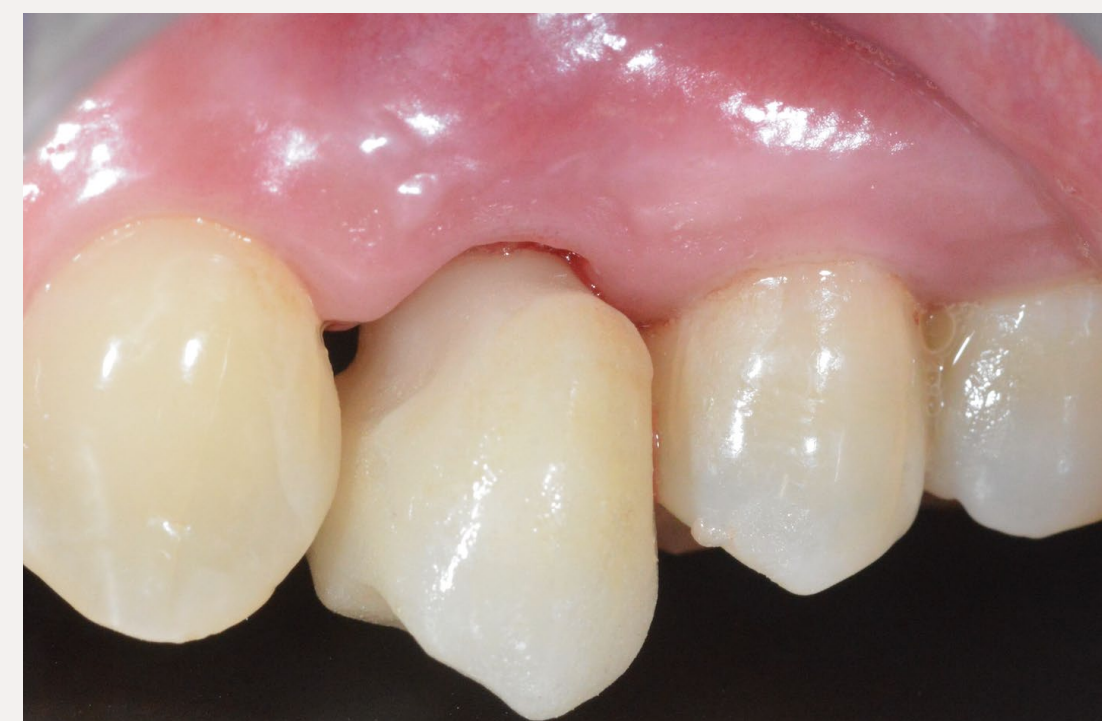Clinical Images



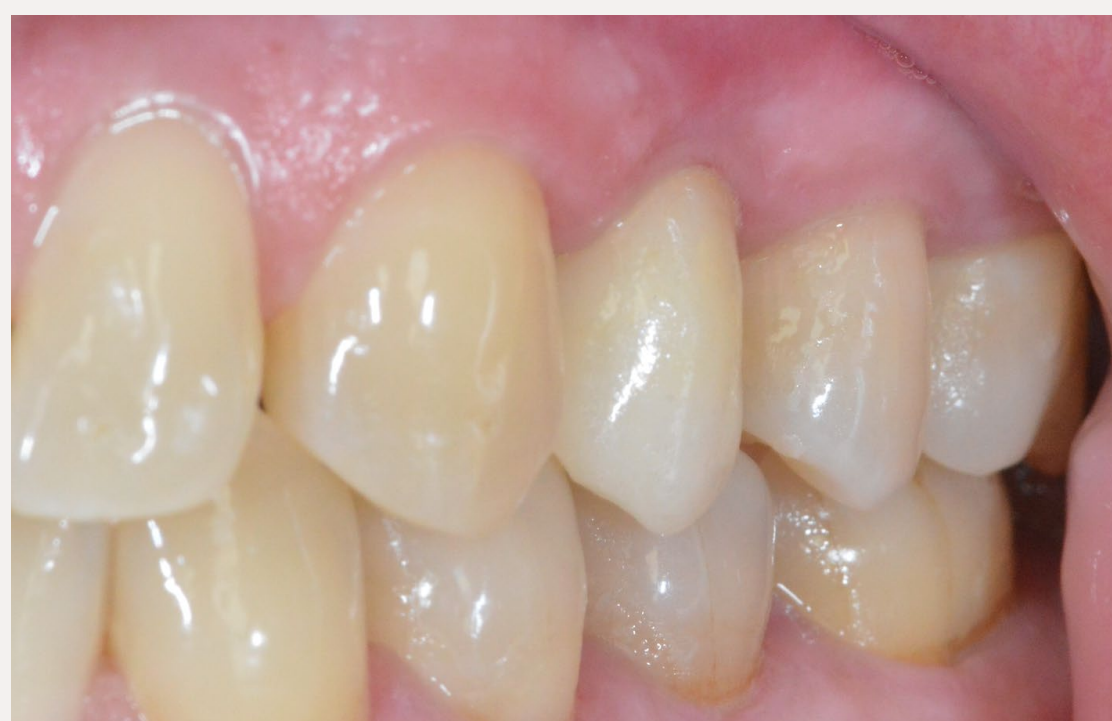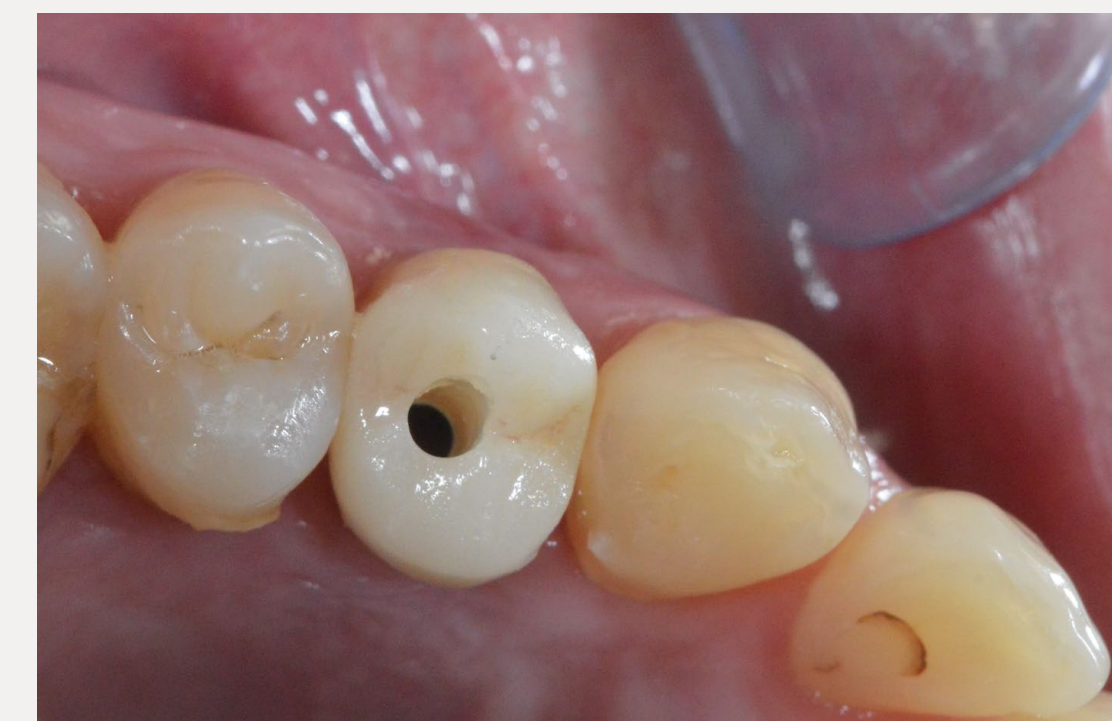
Horizontal root fracture and a periapical infection caused patient pain and some loosening of tooth 24.



Extraction of fractured tooth



Three months later: final prosthetic restoration



Result: preservation of esthetics and the natural soft tissue contour.

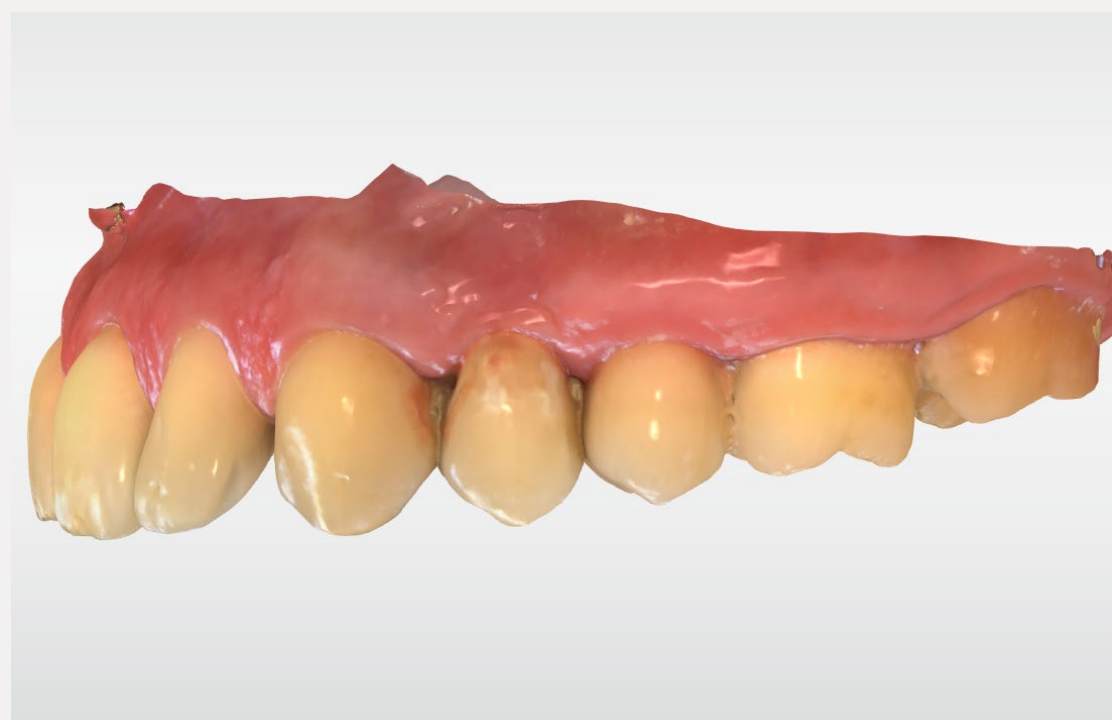

Ankylos implant placement and IPS e.max CAD single crown – First upper premolar in 90 minutes

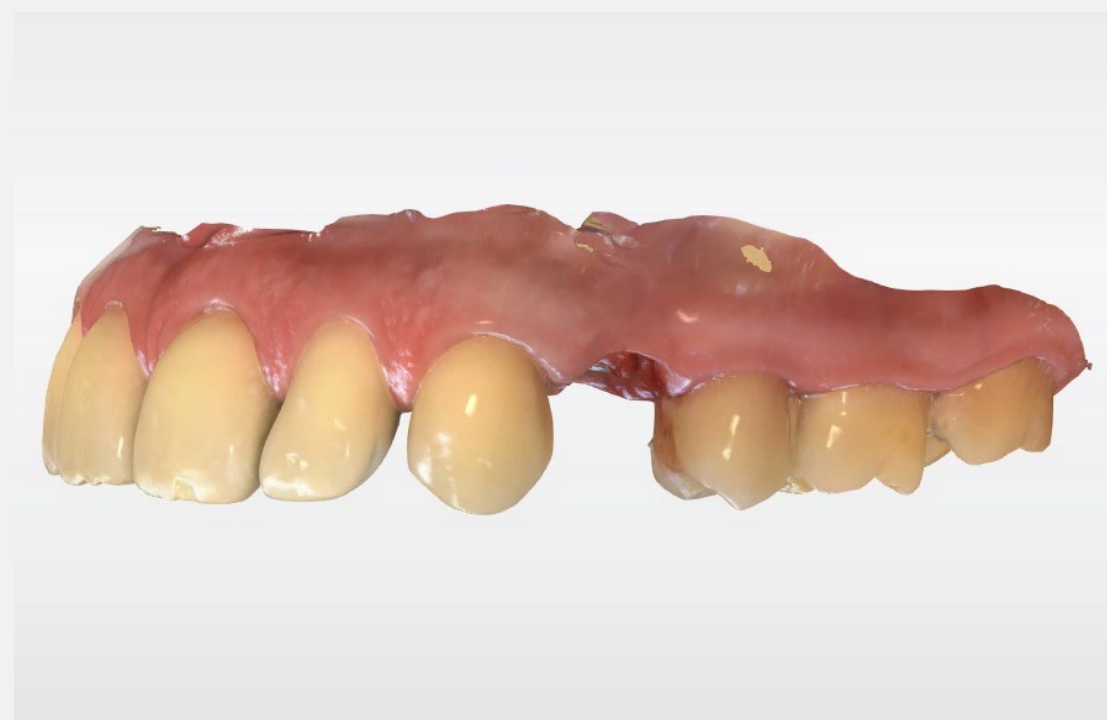

Dr. Carlos Repullo
Sevilla, Spain

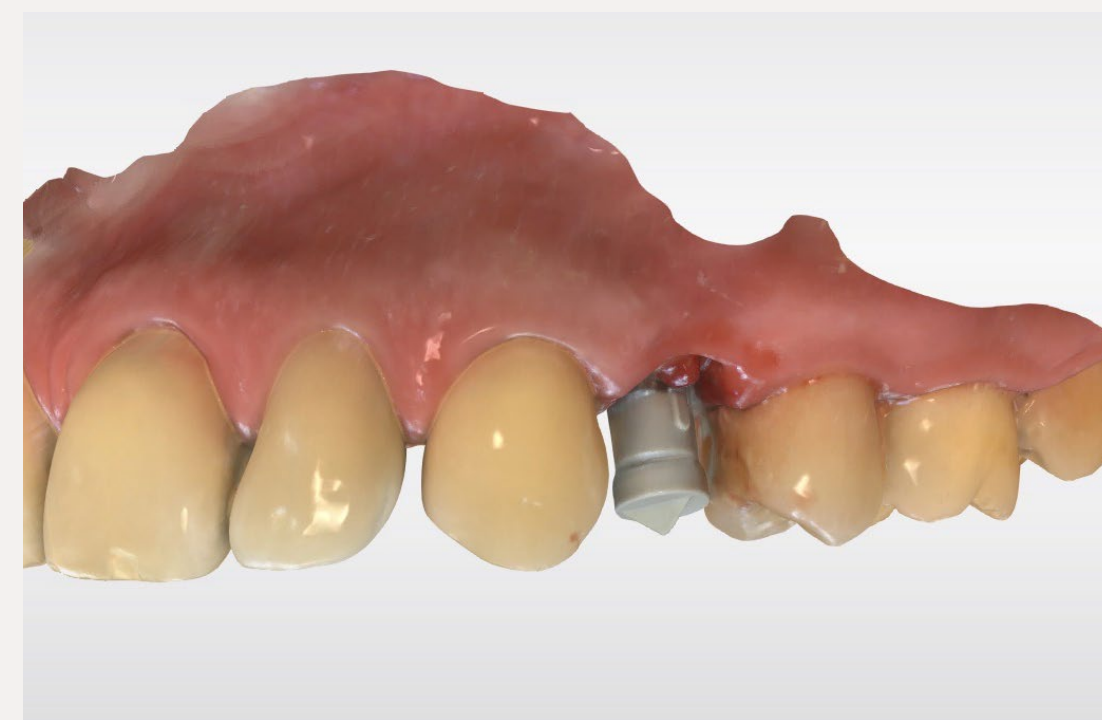Workflow Images



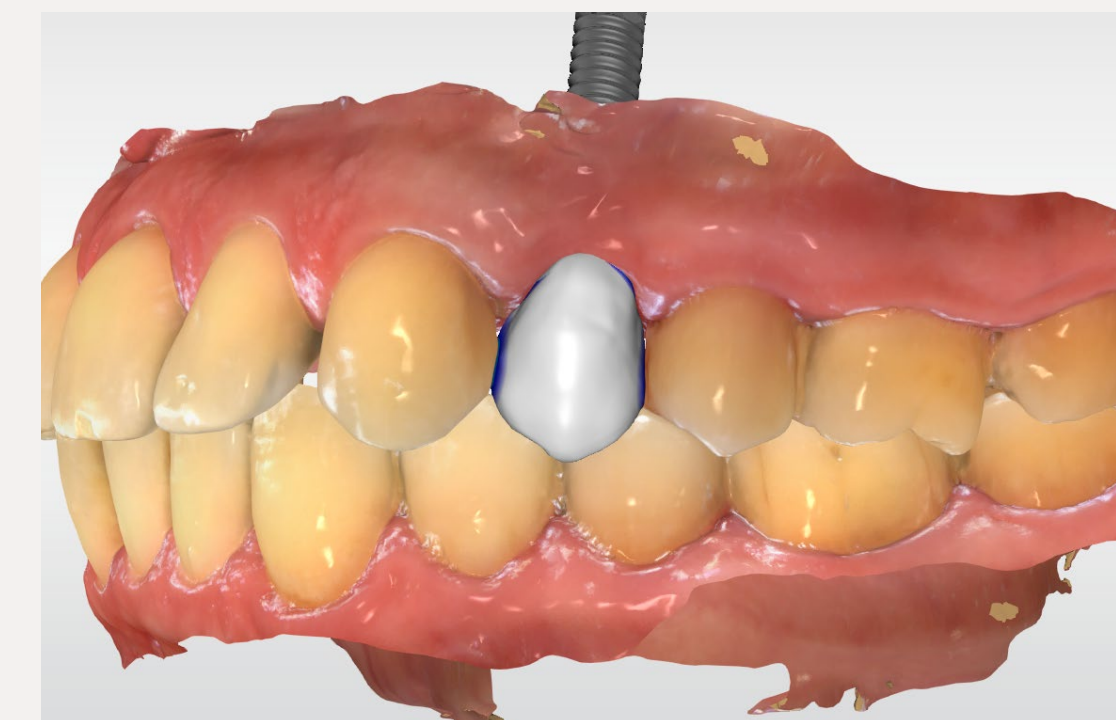
Scan of the temporary restoration (natural crown), which served as a reference for the permanent crown to be fabricated.




Scan after tooth was extracted to record the soft tissue contour.



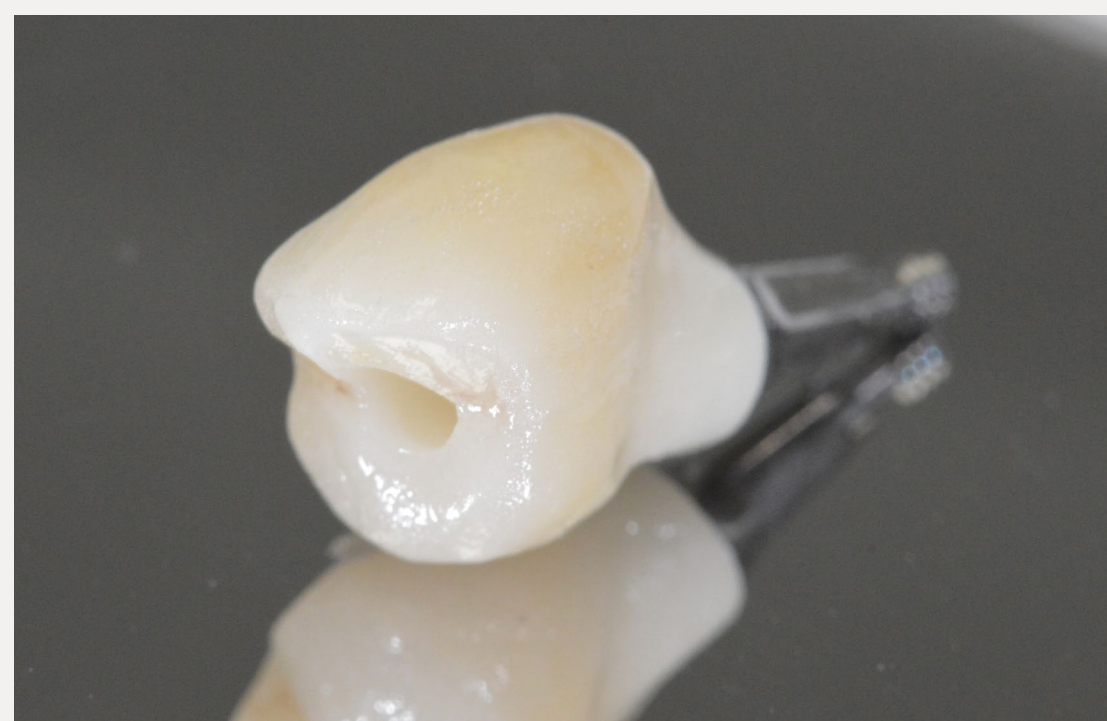Scan with ScanPost and Scanbody.



Restoration design.



CEREC Primemill fast grinding mode was selected.



After crystallization and characterization, the restoration was cemented onto an Ankylos TitaniumBase.