

Implant®

AstraTech
Implant System®

Atlantis®

CASE REPORT

Digital assisted precise
planning and manufacturing
of a fixed dental restoration

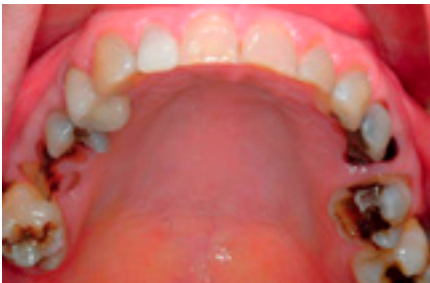
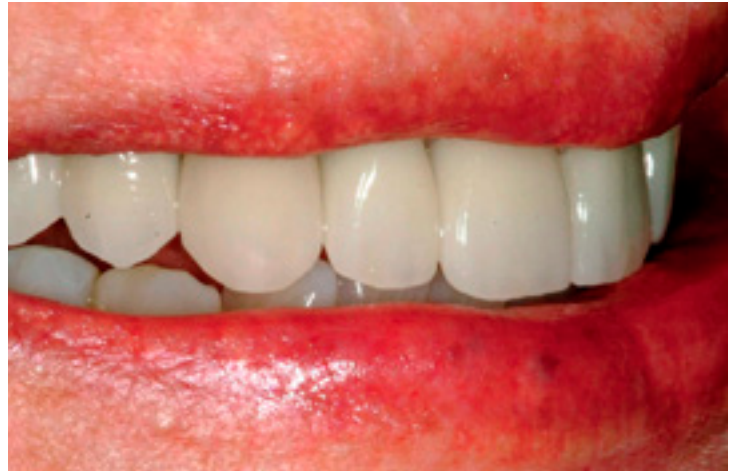
David Guichet, DDS,
Board Certified Prosthodontist
Prosthodontist, Private Practice,
Orange, CA, USA
drdavid@guichetdental.com
Thank you to Debra Wasky,
Dental Technician

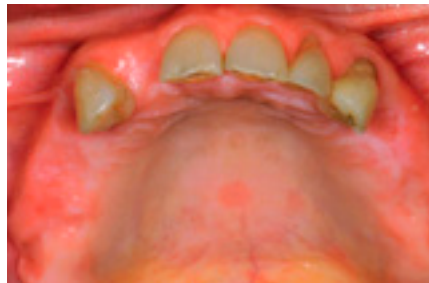A 66-year-old female patient presented with several decayed, fractured and supraerupted teeth in the upper jaw.

The patient required a fixed prosthetic restoration. This superstructure had to be fixed to implants as well as natural teeth and therefore was in need of a very stable and precisely fitting framework.

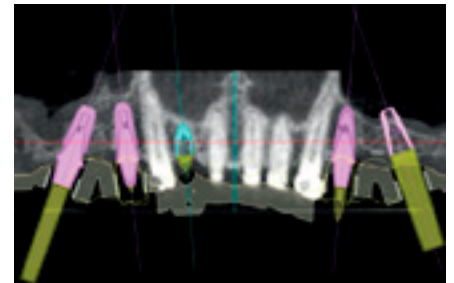
Extraction of the hopeless teeth and socket preservation grafting were performed. Five OsseoSpeed EV implants were placed; the two in the molar region were angled by 30 degrees. Afterwards a restoration with high-strength zirconia framework and a precise cutback for the veneering porcelain was digitally designed and fabricated. The patient was very satisfied with the fit and esthetic outcome of the bridge.



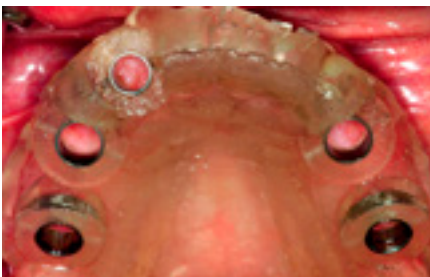1. Pre-treatment clinical situation.



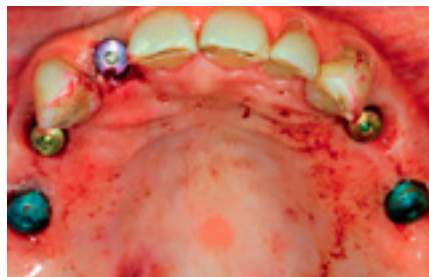2. Intraoral condition three months after extraction and grafting.



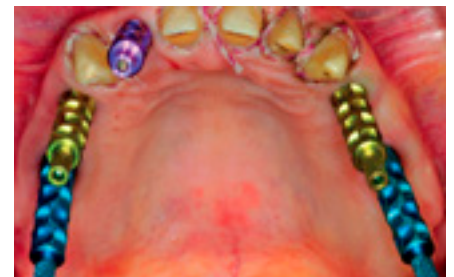3. Simplant software for planning the implant positions.



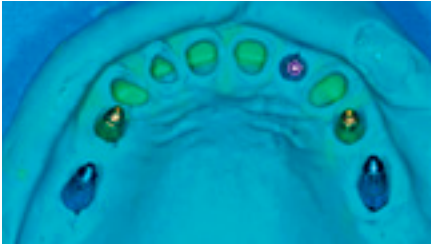
4. Simplant Guide for the first drilling steps.



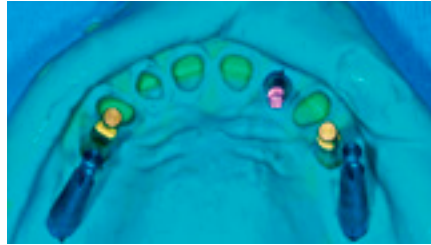
5. Color-coded HealDesign EV in place.



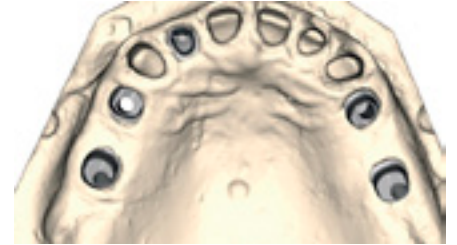
6. Implant Pick-Ups EV in position.



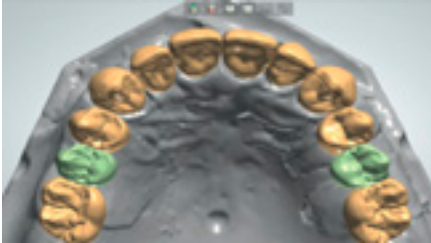
7. After impression taking, the interfaces of the impression posts were revealed in the impression.



8. Color-coded Implant Replicas EV are assembled to the Implant Pick-Ups EV in the impression.



9. Online Atlantis WebOrder showing the Atlantis patient-specific abutments with a digital wax-up transparent overlay.



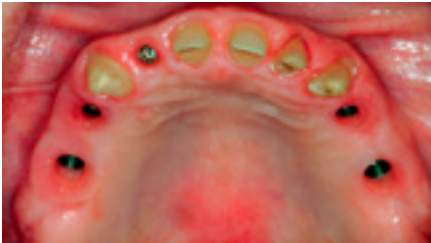10. Occlusal view of the fullcontour digital wax-up prior to digital cutback.



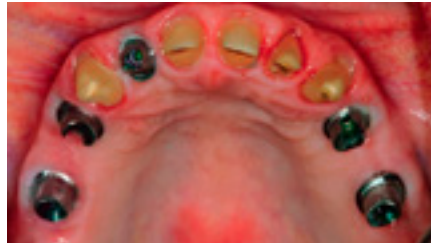11. Atlantis patient-specific abutments with corresponding screws.



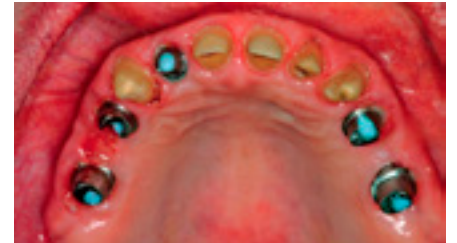12. Full-contour CAD/CAM PMMA provisional restorations.



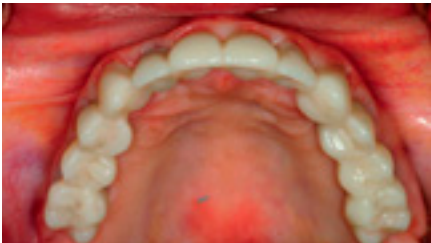13. Healthy and clean implant sulcus evident at all of the sites to be restored.



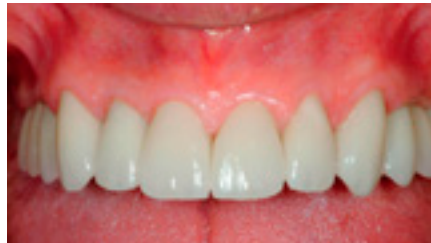14. Atlantis patient-specific abutments installed.



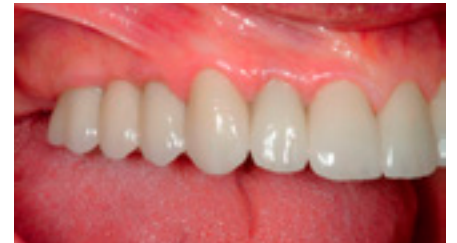15. Clinical situation on the day of final restoration.



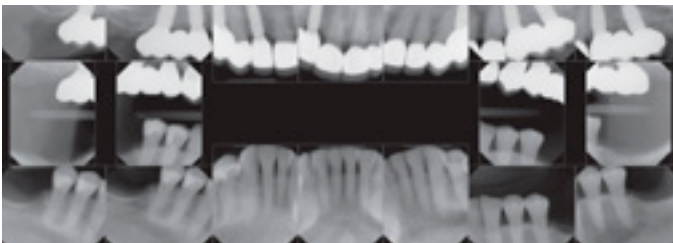
16. The maxillary arch restoration with occlusal and interproximal zirconia.



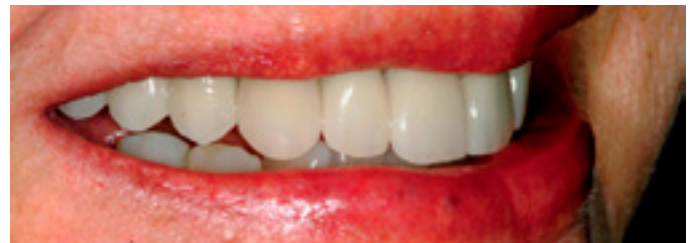17. Facial view revealing natural looking restorations in place on both teeth and implants.



18. A lateral view displaying healthy peri-implant and gingival tissues.



19. Radiographs of implants in the molar, premolar and lateral positions, along with the remaining natural dentition.



20. The patient's smile following maxillary arch reconstruction of her remaining natural teeth and implants.

This case report is published as an inspiration for you as a clinician and not necessarily as a recommendation from Dentsply Sirona.