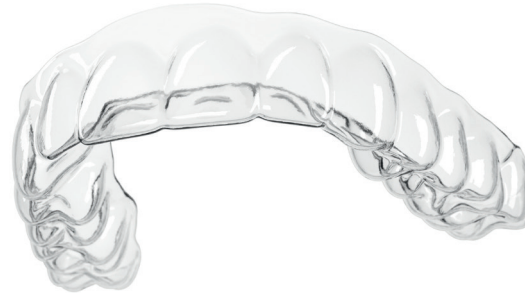


SureSmile® Aligners

Class I- Crowding, Shallow Over Bite

Case Study #06

Courtesy of Dr. Antonino Secchi



Age: 27 years old **Gender:** Female

Patient Primary Concern

I don't like the alignment of my front teeth

Diagnosis

- Moderate crowding lower incisors
- Shallow overbite

Treatment Duration: 5 Months **U:** 17 **L:** 17

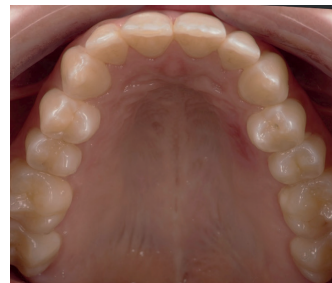Treatment Plan

- The challenge in this case is to be able to level and align the lower arch improving the over bite
- IPR in the lower arch from 3 to 3 in order to align incisors and keep them from proclining
- Improve alignment of upper and lower incisors improving the shallow overbite

Results

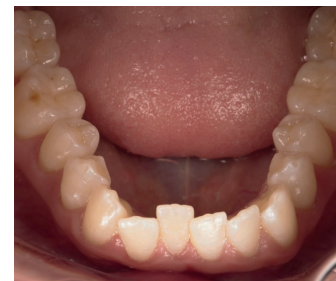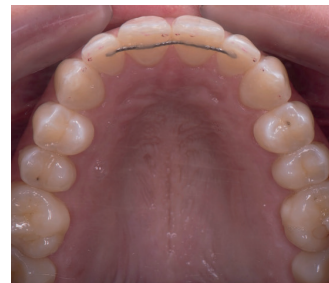- Good alignment of upper and lower teeth was achieved
- Shallow overbite was improved

Before

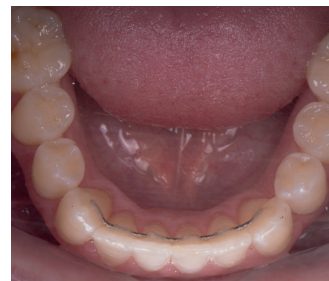

Upper Occlusal

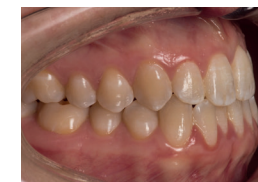After



Lower Occlusal

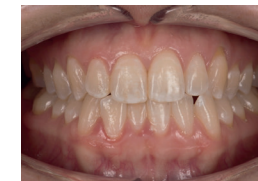
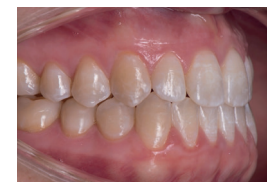
Before

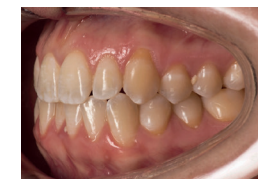
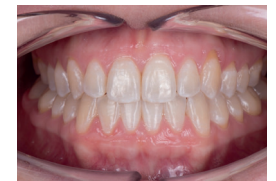
Right Buccal

After



Frontal



Left Buccal

